

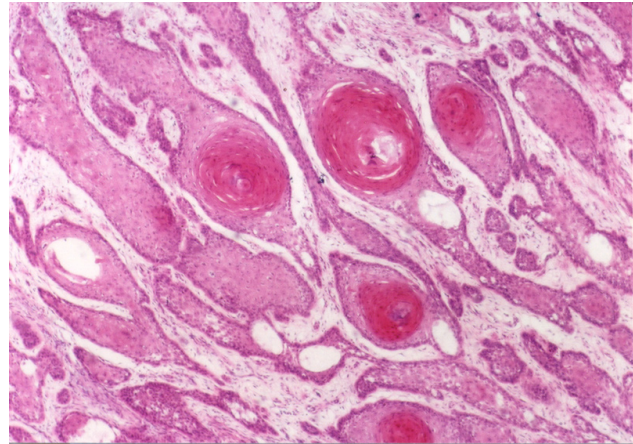
## Keratoacanthoma associated with lichen planus

Sedat Akdeniz, MD, Mehmet Harman, MD,  
Hüseyin Büyükbayram, MD.

Keratoacanthomas (KA) are benign tumors, which have many of the histological features of a well-differentiated squamous cell carcinoma (SCC) with the ability to spontaneously regress.<sup>1</sup> In one series, approximately 10% of lesions developed in areas of injury or previous skin disease.<sup>2</sup> To our knowledge, 2 cases of KA have previously been reported within hypertrophic lichen planus (LP).<sup>3</sup> In this report, we describe a patient who has KA with LP.

A 48-year-old woman presented with a 2-month history of a nodular growth on the back of her left hand. The lesion grew rapidly in the first few weeks and then has remained static in size. She had multiple pruritic papules on the flexor surfaces of the upper limbs, backs of the hands, trunk, and on the lower extremities for more than 8 months duration. She also gave a history of the same pruritic papular lesion on the back of her left hand at the site of nodular lesion. On physical examination, multiple papules on the flexor surfaces of the upper limbs, backs of the hands, trunk, and lower legs were noticed. A round one cm diameter nodule with central keratin plug was situated on the dorsum of the left hand. She also gave a history of the papular lesion, same as the others, at the site of the nodule. Additionally, erosive lesions and discrete white reticulate marks on the lower lip and buccal mucosa at the level of the posterior molars were noted. The full blood count, erythrocyte sedimentation rate, liver function tests, triglycerides and blood sugar were within normal limits. Hepatitis serology tests to viruses B, C, and D were all negative. Microscopically, excision of the nodule disclosed a central keratin-filled crater with surrounding irregular proliferation of pale eosinophilic keratinizing cells with a mild mononuclear infiltrate at the base, consistent with the diagnosis of KA (Figure 1). A biopsy specimen from the papular lesion on the flexor surface of the left upper limb disclosed epidermal hyperplasia with orthokeratosis and hypergranulosis, vacuolar alteration at the basal layer, and dense infiltration composed of lymphocytes in the superficial dermis, diagnostic for LP.

Although the origin of the KA is uncertain, it is possible that there is an interaction between genetic



**Figure 1** - Keratoacanthomas shows tumor island with glassy appearance invading the dermis. Keratinocytes arranged in concentric layers with increasing keratinization centrally (Hematoxylin and eosin stain, x80).

predisposition and other cofactors such as ultraviolet light, chemical agents, inflammatory diseases, and viral infections as well as trauma in the pathogenesis of KA.<sup>1</sup> Koebner's isomorphic phenomenon occurs by physical trauma, such as scratching, and this was positive in our patient. We think that LP together with scratching due to pruritus in LP may have been responsible in the development of KA. Keratoacanthomas have been reported to develop following inflammatory diseases such as psoriasis, discoid lupus erythematosus,<sup>4</sup> and at sites of trauma such as thermal burns, vaccination, and recently healing herpes zoster sites.<sup>5</sup> As we performed in our patient, solitary KAs should usually receive complete conservative excision, which also provides an optimal biopsy specimen and in most patients a greater likelihood of a favorable cosmetic outcome than would be anticipated with spontaneous resolution. The KAs may develop in certain benign conditions,<sup>1</sup> such as stasis dermatitis, vaccination site, lichen planus, psoriasis, venipuncture site, nevus sebaceous, epidermolysis bullosa dystrophica, atopic dermatitis, acne conglobata, discoid lupus erythematosus, radiation dermatitis, folliculitis, lichen simplex chronicus, thermal burns, nitrogen mustard patch testing site, linear epidermal nevus, pemphigus foliaceus, and lepromatous leprosy.

In conclusion, we present a case of KA with LP. This case may be a chance association of KA with LP. As no active LP is documented in the lesional site of KA, it is difficult to accept any causality with LP, however, the patient gave a history of the same pruritic papular lesion

## Clinical Notes

at the site of the nodular lesion. Trauma, such as itching may be the cause of KA in this case, as the patient is right hand dominant and had positive Koebner phenomenon on her left forearm.

Received 30th April 2006. Accepted 31st December 2006.

From the Department of Dermatology (Harman, Akdeniz), and from the Department of Pathology (Buyukbayram), Faculty of Medicine, University of Dicle, Diyarbakir, Turkey. Address correspondence and reprint requests to: Associate Professor Sedat Akdeniz, Department of Dermatology, Faculty of Medicine, University of Dicle, 21280 Diyarbakir, Turkey. Tel. +90 (412) 248850. Fax. +90 (412) 2488440. E-mail: sakdeniz@dicle.edu.tr

## References

1. Kalomenidis I, Light RW. Pathogenesis of the eosinophilic pleural effusions. *Curr Opin Pulm Med* 2004; 10: 289-293.
2. Rubins JB, Rubins HB. Etiology and prognostic significance of eosinophilic pleural effusions. A prospective study. *Chest* 1996; 110: 1271-1274.
3. Emad A. Exudative eosinophilic pleural effusion due to *Strongyloides stercoralis* in a diabetic man. *South Med J* 1999; 92: 58-60.
4. de Silva NR, Brooker S, Hotez PJ, Montresor A, Engels D, Savioli L, et al. Soil-transmitted helminth infections: updating the global picture. *Trends Parasitol* 2003; 19: 547-551.
5. Hotez PJ, Brooker S, Bethony JM, Bottazzi ME, Loukas A, Xiao S, et al. Hookworm infection. *N Engl J Med* 2004; 351: 799-807.

## Authorship Entitlement

Excerpts from the Uniform Requirements for Manuscripts Submitted to Biomedical Journals updated November 2003.  
Available from [www.icmje.org](http://www.icmje.org)

The international Committee of Medical Journal Editors has recommended the following criteria for authorship; these criteria are still appropriate for those journals that distinguish authors from other contributors.

Authorship credit should be based on 1) substantial contributions to conception and design, or acquisition of data, or analysis and interpretation of data; 2) intellectual content; and 3) final approval of the version to be published. Authors should meet conditions 1, 2, and 3.

Acquisition of funding, collection of data, or general supervision of the research group, alone, does not justify authorship.

Author should be prepared to explain the order in which authors are listed.