

The effects of N-acetylcysteine and vitamin C on liver and pulmonary tissue damage in rats following bile duct ligation

Hayrettin Ozturk, MD, Elcin H. Terzi, MD, Hulya Ozturk, MD, Aysel Kukner, MD.

ABSTRACT

الأهداف: تقييم آثار عقار إن-أسيتيلسيستين (NAC) وفيتامين (C) على التغيرات النسيجية الرئوية في الجرذان التي أجريت لها عملية ربط القناة الصفراوية (BDL).

الطريقة: أجريت هذه الدراسة بقسم جراحة الأطفال - المدرسة الطبية لجامعة أباتنت عزت بياسل - بولو - تركيا، خلال الفترة ما بين مايو 2007م وحتى يوليو 2007م. تم استعمال عدد 35 ذكر من جرذان سبارجيو داولي، تراوح الوزن 210-240grams. المجموعة الأولى (عدد=7) جرذان خضعت فقط لعملية فتح البطن. المجموعة الثانية (عدد=7) جرذان أجريت لها عملية ربط القناة الصفراوية (BDL). المجموعة الثالثة (عدد=7) جرذان أجريت لها عملية ربط القناة الصفراوية (BDL) وتلقت فيتامين (C). المجموعة الرابعة (عدد=7) جرذان أجريت لها عملية ربط القناة الصفراوية (BDL) وأعطيت عقار (NAC). المجموعة الخامسة (عدد=7) جرذان أجريت لها عملية ربط القناة الصفراوية (BDL) وأعطيت عقار (NAC) وفيتامين (C). تم إجراء التقييم الكيميائي الحيوي والنسيجي في نهاية فترة الثلاثة أسابيع.

النتائج: انخفضت قيم البيليروبين الكلي في المجموعة الخامسة مقارنة بالمجموعة الثانية والثالثة والرابعة. أظهرت المجموعة الثانية وجود ترشيع سدوي كبير مع خلايا ملتهبة ووذمة سدوية وتبدل نردي للخلايا الخطية الدرديرية، ولوحظ وجود تلف شديد للبنية الرئوية. أظهرت معالجة الجرذان بعقار (NAC) وفيتامين (C) تقلص ملحوظ في النقاط المرضية النسيجية مقارنة مع المجموعة الثانية والثالثة والرابعة.

خاتمة: اتحاد تركيب عقار (NAC) وفيتامين (C) يخفف من التغيير النسيجي للرئة في الجرذان التي أجريت لها عملية ربط للقناة الصفراوية (BDL) مع تحمل كل عقار بشكل فرادي.

Objective: To evaluate the effects of N-acetylcysteine (NAC) and vitamin C on pulmonary histological alterations in bile duct-ligated (BDL) rats.

Methods: The current study was conducted in the Department of Pediatric Surgery, Medical School of Abant Izzet Baysal University, Bolu, Turkey between May 2007 and July 2007. Thirty-five males Sprague-Dawley rats, weighing 210-240 grams, were used. Group 1 rats (n=7) underwent only laparotomy. Group 2 rats (n=7) were subjected to BDL. Group 3 rats (n=7) were subjected to BDL and given vitamin C. Group 4 rats (n=7) were subjected to BDL and given NAC. Group 5 rats (n=7) were subjected to BDL and received NAC plus vitamin C. At the end of the 3 week period, biochemical and histological evaluations were processed.

Results: Total bilirubin values were decreased in group 5 compared to group 2, 3, and 4. Group 2 showed massive interstitial infiltration with inflammatory cells. Interstitial edema, focal cuboidal metaplasias of alveolar lining cells, and severely damaged pulmonary architecture were noted. Treatment of rats with NAC and vitamin C produced a significant reduction in the histopathological score compared to groups 2, 3, and 4.

Conclusions: The combination of NAC and vitamin C reduced lung histological alterations in BDL rats with afforded by each drug individually.

Saudi Med J 2008; Vol. 29 (11): 1580-1584

From the Departments of Pediatric Surgery (Ozturk), Histology and Embryology (Terzi, Kukner), Medical School, Abant Izzet Baysal University, Bolu, and Department of Pediatric Surgery (Ozturk), Medical School, Duzce University, Duzce, Turkey.

Received 8th April 2008. Accepted 24th September 2008.

Address correspondence and reprint request to: Associate Professor Hayrettin Ozturk, Department of Pediatric Surgery, Medical School, Abant Izzet Baysal University, Bolu 14280, Turkey. Tel. +90 (374) 2534656 Ext. 3220. Fax. +90 (374) 2534615. E-mail: ozturkhayrettin@hotmail.com

Cholestatic liver disease is associated with high perioperative morbidity such as sepsis, bleeding, wound problems, renal and liver malfunction and pulmonary inflammation.^{1,2} Research has demonstrated that common bile duct obstruction in humans and animals is associated with disruption of intestinal integrity,^{1,2} and systemic endotoxemia leading to multiple organ dysfunction.³⁻⁵ Thus, endotoxemia activates immunocompetent cells, such as monocytes, macrophages, and endothelial cells that contribute to an uncontrollable inflammatory cascade.^{6,7} Pulmonary failure is a frequent occurrence in patients with cholestatic liver disease.⁸ One of the major histopathologic characteristics of this pulmonary damage is the infiltration of large numbers of potentially injurious leukocytes into the pulmonary tissue.⁹ Additionally, lipid peroxidation is associated with the pathogenesis of tissue damage in animals with obstructive jaundice. Reactive oxygen species (ROS) seem to play a role in the pathogenesis of tissue injury secondary to obstructive jaundice.¹⁰ Reactive oxygen species scavengers decrease in bile duct-ligated rats, thence increasing the predisposition of the liver to injury by ROS.¹¹ Morise et al⁹ suggested that ROS produced in response to bile duct ligation may up-regulate vascular cell adhesion molecule-1 expression in the lung and play an important role in the pathophysiology of this pulmonary injury. N-acetylcysteine (NAC) is a membrane-permeable precursor of glutathione (GSH) that protects cells against oxidative damage.¹²⁻¹⁴ In addition, it has been shown that NAC has an anti-inflammatory action and reduces the ability of neutrophils and monocytes to generate and release ROS, such as nuclear factor- κ B, tumor necrosis factors- α and cell adhesion molecules.¹⁵⁻¹⁷ Ascorbic acid (vitamin C) is a protective factor in inflammation because of its antioxidant properties. Vitamin C is known to scavenge aqueous ROS by rapid electron transfer and hence, inhibits lipid peroxidation.¹⁸⁻²⁰ Based on prevention of inflammation by NAC and vitamin C and their antioxidant properties, we investigated the effects of NAC and vitamin C on lung histological alterations in bile duct-ligated rats in the present experimental study.

Methods. The current study was conducted in the Department of Pediatric Surgery, Medical School of Abant Izzet Baysal University, Bolu, Turkey between May 2007 and July 2007. Thirty-five males Sprague-Dawley rats weighing 210-240 grams were used in the study. The protocol was approved by the ethics committee for animal experiments of the Medical Faculty of the University of Bolu Abant Izzet Baysal, Bolu, Turkey. The animals were divided into 5 groups. Each rat was anesthetized with ketamine (50 mg/kg) and xylazine (4 mg/kg). The rats were subjected to

either bile duct ligation (BDL) or sham operation using aseptic techniques. Group 1 (sham-control, n=7) rats underwent laparotomy, the bile duct was dissected from the surrounding tissue and rats received intraperitoneally (IP) one ml of saline. Group 2 rats (BDL/untreated, n=7) were subjected to BDL and received IP one ml of saline. Group 3 rats (BDL/vitamin C, n=7) were subjected to BDL and given IP vitamin C (Ascorbic acid, Redoxon®, Roche, Istanbul, Turkey) at a daily dose of 100 mg/kg for 21 days after BDL. Group 4 rats (BDL/NAC, n=7) were subjected to bile duct ligation and given IP NAC (Assist ampule 100 mg/mL, Husnu Arsan Ilaclari A.S. Turkey) at a daily dose of 200 mg/kg for 21 days after BDL. Group 5 rats (BDL/NAC plus vitamin C, n=7) were subjected to BDL and received a daily dose of vitamin C (100 mg/day⁻¹×kg⁻¹) and NAC (200 mg/day⁻¹×kg⁻¹) ip for 21 days after BDL. At the end of the 21 days, the rats were housed in standard cages in a room controlled for daylight (12 hours), temperature (20°C) and humidity (60%), and maintained on a standard rat pellet diet. After opening the abdomen by a midline incision, the aorta was punctured and 5 ml of blood was taken into heparinized tubes. Plasma was separated by centrifugation for biochemical studies, and the concentrations of total bilirubin (TB) (mg/dl) in plasma were determined by standard auto-analyser methods on an Abbot Aeroset, USA. Just after the rats were sacrificed, the liver and lung were extracted for histopathological evaluation. The extracted tissues were immediately placed into 10% formaldehyde solution overnight, embedded in paraffin, and cut into 5-mm thick sections; stained with hematoxylin-eosin for light microscopic analysis. Light microscopic analysis of the liver and lungs was performed by blinded observation. The liver histopathological scoring of groups, for degree of fibrosis (ductular proliferation, focal ductular cholestasis, portal tract expansion, mixed inflammation, necrosis, and fibrosis) was scored as: 0-absent, 1-slight, 2-moderate, and 3-severe. Pulmonary architecture, tissue edema formation, and infiltration of the inflammatory cells were scored between grades 1 and 4. According to this scoring system: 1) normal lung histology; 2) few neutrophil leukocyte infiltration; 3) moderate neutrophil leukocyte infiltration, perivascular edema formation, and partial destruction of pulmonary architecture; and 4) dens neutrophil leukocyte infiltration and complete destruction of pulmonary architecture.²¹

Differences in biochemical and histological data were analyzed by Mann-Whitney U test. Changes in time were analyzed by one-way analysis of variance. Differences at the indicated time points were assessed by Bonferroni test for multiple comparisons when applicable. data were entered on an IBM-compatible personal computer using SPSS version 10.0 (SPSS Inc.,

Chicago, Illinois, USA. A *p*-value of less than 0.05 were considered significant.

Results. The values of bilirubin were measurement for the different groups (Table 1). Total bilirubin levels were increased significantly in group 2 ($p<0.0001$), 3 ($p<0.0002$), 4 ($p<0.0002$), and 5 ($p<0.0002$) compared with the group 1 ($p<0.05$ in all cases). However, TB values were decreased in group 5 compared to group 2 ($p<0.001$), 3 ($p<0.001$), and 4 ($p<0.002$). No morphological damage was observed in group 1. In group 2, 3, and 4, severe damage such as dilated central veins, proliferation of portal

Table 1 - Comparative biochemical and histopathologic measurements 3 weeks after the start of the study (N=7).

Groups	TB (mg/dl)	Histopathological scores
Group 1 (Sham-control)	0.3±0.1	0.1±0.3
Group 2 (BDL/untreated)	11±1.3*	3.2±0.5*
Group 3 (BDL/vitamin C)	10±1.0*	2.3±0.5*†
Group 4 (BDL/NAC)	9±1.5*	2.2±0.5*†
Group 5 (BDL/NAC + vitamin C)	8±0.9*†	1.6±0.9*†

BDL - bile duct ligation, TB - total bilirubin,
NAC - N-acetylcysteine, * $p<0.05$ compared with Sham-control,
† $p<0.05$ compared with group 2

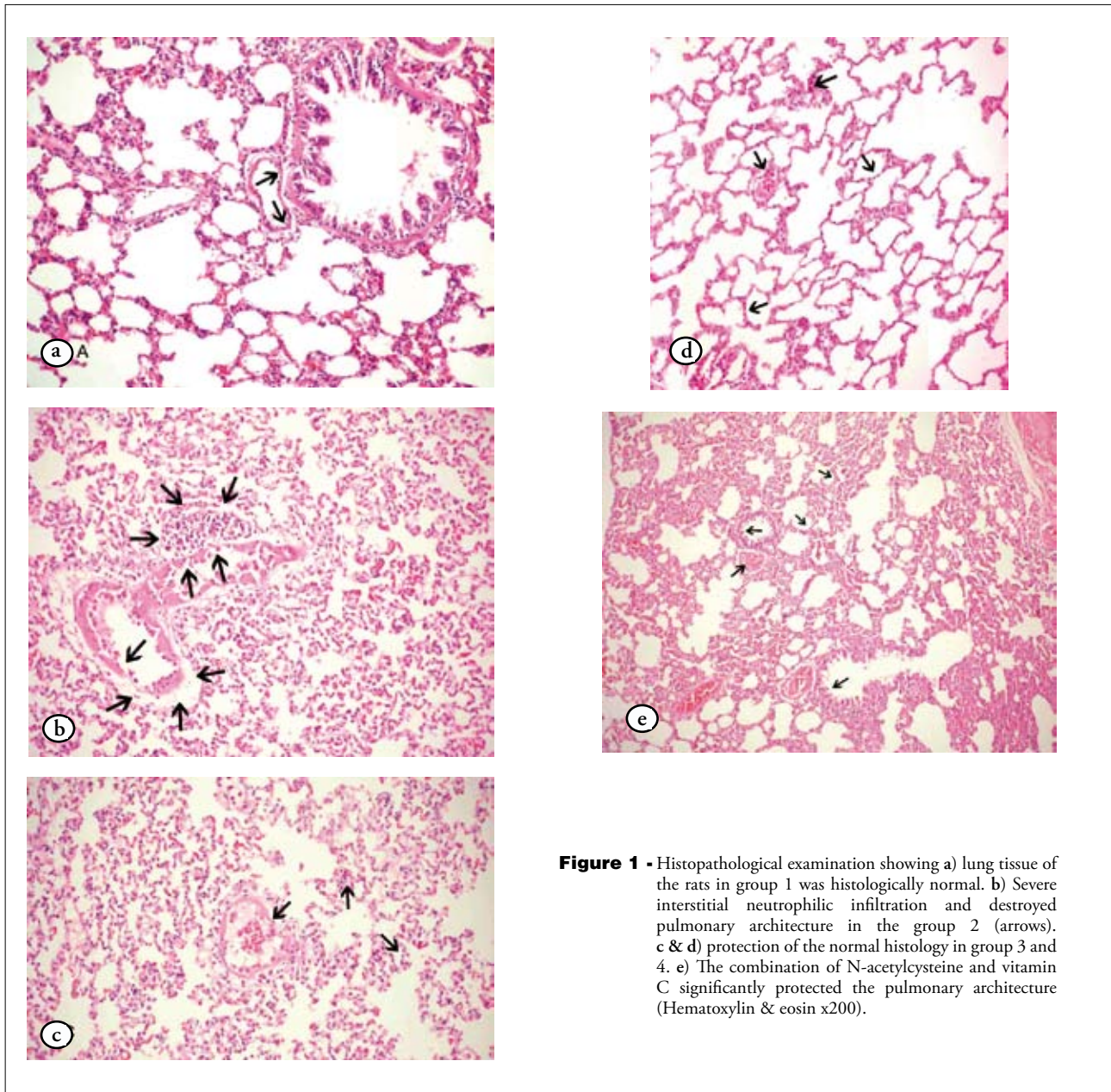


Figure 1 - Histopathological examination showing a) lung tissue of the rats in group 1 was histologically normal. b) Severe interstitial neutrophilic infiltration and destroyed pulmonary architecture in the group 2 (arrows). c & d) protection of the normal histology in group 3 and 4. e) The combination of N-acetylcysteine and vitamin C significantly protected the pulmonary architecture (Hematoxylin & eosin x200).

and periportal biliary ductules, dilated portal spaces and areas of polymorphonuclear leukocyte infiltrate and hepatocytes necrosis was observed. In group 5, moderate damage was seen. The histopathological scores for the different groups were shown in Table 1. In group 1, the histopathological examination of the lung tissue of the rats was found to be normal (Figure 1a). Group 2 showed massive interstitial infiltration with inflammatory cells, including lymphocytes with fewer numbers of neutrophils and eosinophils. Interstitial edema, focal cuboidal metaplasias of alveolar lining cells, and severely damaged pulmonary architecture also were noted (Figure 1b). The median score of group 2 was significantly higher than sham ($p < 0.0001$). N-acetylcysteine and vitamin C administration to the jaundiced rats resulted in a decrease in median histopathological score when compared with group 2 ($p < 0.001$) (Figures 1c & 1d). N-acetylcysteine plus vitamin C administration protected the pulmonary architecture, and the median histopathologic score decreased significantly when compared with median score of groups 2, 3, and 4 ($p < 0.001$, $p < 0.002$, $p < 0.002$ in all cases) (Figure 1e).

Discussion. Obstructive jaundice is linked to a higher incidence of renal and intestinal dysfunction, multiple organ failure, impaired immune function, impaired wound healing, and cardiovascular abnormalities such as reduced peripheral vascular resistance, increased basal cardiac output, and impaired cardiac contractile.²²⁻²⁶ However, it is pulmonary inflammation that is the most significant complication that is associated with morbidity and mortality.^{27,28} Therefore, this study was mainly focused to investigate the effect of NAC and vitamin C on lung histopathologic alterations in experimental obstructive jaundice. Additionally, the present study shows that treatment with NAC in combination with vitamin C was effective to reduce the lung damage produced by BDL in rats.

N-acetylcysteine is a well-known precursor of GSH that helps to scavenge the ROS generated in the extracellular medium and was found to increase GSH levels in bronchoalveolar fluid.²⁹ Ozdulger et al²¹ demonstrated that NAC reduced the number of apoptotic cells in the lung and alleviated lung injury in a cecal ligation and puncture induced sepsis model. They found that the chronic use of NAC inhibited myeloperoxidase activity and lipid peroxidation, which resulted in reduction of apoptosis in the lung.²¹ In another experimental study, Borjesson et al³⁰ suggested that treatment with NAC prevented against intestinal ischemia reperfusion induced over activation of pulmonary macrophages and a decrease in pulmonary blood content.

Vitamin C works as a cofactor in the enzymatic biosynthesis of collagen, carnitine, and catecholamine, and peptide neurohormones.³¹ Vitamin C also prevents injurious effects of oxidants because it diminishes ROS to stable molecules.³² Kearns et al³³ suggested that vitamin C therapy protects against ischemia reperfusion induced acute lung injury, possibly by attenuating neutrophil respiratory burst activity. Furthermore, Vanisree et al³⁴ reported that NAC along with vitamin C could enhance the antioxidant state of the lung. Vitamin C could help to continue the diminished pools of GSH and gets converted to dehydro ascorbate in the process of generating GSH from its oxidized form (oxidized glutathione).^{34,35} In the present study, in individual evaluation, NAC and vitamin C administration to the jaundiced rats resulted in a decrease in median histopathological score when compared with group 2. Combination of NAC and vitamin C also produced a synergistic effect in protection of lung tissue against the deleterious effects of BDL. Scott et al³⁶ suggested that tobacco-induced vascular activation in smokers is unaffected by vitamin C supplementation.

In conclusion, the combination of NAC and vitamin C augments the amount of lung protection afforded by each drug individually, and increased their antioxidant potentials. We believe that further experimental and clinical studies are needed to elucidate the efficacy of combined NAC plus vitamin C on lung protection.

References

1. Chang SW, Ohara N. Pulmonary circulatory dysfunction in rats with biliary cirrhosis. An animal model of the hepatopulmonary syndrome. *Am Rev Respir Dis* 1992; 145: 798-805.
2. Kimmings AN, van Deventer SJ, Obertop H, Rauws EA, Gouma DJ. Inflammatory and immunologic effects of obstructive jaundice: pathogenesis and treatment. *J Am Coll Surg* 1995; 181: 567-581.
3. Parks RW, Stuart Cameron CH, Gannon CD, Pope C, Diamond T, Rowlands BJ. Changes in gastrointestinal morphology associated with obstructive jaundice. *J Pathol* 2000; 192: 526-532.
4. Sileri P, Morini S, Sica GS, Schena S, Rastellini C, Gaspari AL, et al. Bacterial translocation and intestinal morphological findings in jaundiced rats. *Dig Dis Sci* 2002; 47: 929-934.
5. Clements WD, Erwin P, McCaigue MD, Halliday I, Barclay GR, Rowlands BJ. Conclusive evidence of endotoxaemia in biliary obstruction. *Gut* 1998; 42: 293-299.
6. Sakrak O, Akpınar M, Bedirli A, Akyurek N, Aritas Y. Short and long-term effects of bacterial translocation due to obstructive jaundice on liver damage. *Hepatogastroenterology* 2003; 50: 1542-1546.
7. Padillo FJ, Muntane J, Montero JL, Briceno J, Mino G, Solorzano G, et al. Effect of internal biliary drainage on plasma levels of endotoxin, cytokines, and C-reactive protein in patients with obstructive jaundice. *World J Surg* 2002; 26: 1328-1332.
8. Thompson JE Jr, Tompkins RK, Longmire WP Jr. Factors in management of acute cholangitis. *Ann Surg* 1982; 195: 137-145.

9. Morise Z, Ueda M, Kitajima M, Epstein CJ, Granger DN, Grisham MB. Reactive oxygen species and vascular cell adhesion molecule-1 in distant organ failure following bile duct obstruction in mice. *Dig Dis Sci* 2002; 47: 607-613.
10. Kucuk C, Ok E, Yilmaz Z, Sozuer E, Muhtaroglu S, Arar M. The effects of dimethylsulfoxide in experimental obstructive jaundice. *Acta Chir Belg* 2003; 103: 392-395.
11. Tsai LY, Lee KT, Lu FJ. Biochemical events associated with ligation of the common bile duct in Wistar rats. *J Formos Med Assoc* 1997; 96: 17-22.
12. Blesa S, Cortijo J, Mata M, Serrano A, Closa D, Santangelo F, et al. Oral N-acetylcysteine attenuates the rat pulmonary inflammatory response to antigen. *Eur Respir J* 2003; 21: 394-400.
13. Vivot C, Stump DD, Schwartz ME, Theise ND, Miller CM. N-acetylcysteine attenuates cold ischemia/reperfusion injury in the isolated perfused rat liver. *Transplant Proc* 1993; 25: 1983-1984.
14. Aruoma OI, Halliwell B, Hoey BM, Butler J. The antioxidant action of N-acetylcysteine: its reaction with hydrogen peroxide, hydroxyl radical, superoxide, and hypochlorous acid. *Free Radic Biol Med* 1989; 6: 593-597.
15. Blacwell TS, Blacwell TR, Holden EP, Christman BW, Christman JW. In vivo antioxidant treatment suppresses nuclear factor- κ B activation and neutrophilic lung inflammation. *J Immunol* 1996; 157: 1630-1637.
16. Kharazmi A, Nielsen H, Schiotz PO. N-acetylcysteine inhibits human neutrophil and monocyte chemotaxis and oxidative metabolism. *Int J Immunopharmacol* 1988; 10: 39-46.
17. Hoffer E, Avidor I, Benjaminov O, Shenker L, Tabak A, Tamir A, et al. N-acetylcysteine delays the infiltration of inflammatory cells into the lungs of paraquat-intoxicated rats. *Toxicol Appl Pharmacol* 1993; 120: 8-12.
18. Daga MK, Chhabra R, Sharma B, Mishra TK. Effects of exogenous vitamin E supplementation on the levels of oxidants and antioxidants in chronic obstructive pulmonary disease. *J Biosci* 2003; 28: 7-11.
19. Tug T, Karatas F, Terzi SM. Antioxidant vitamins (A, C and E) and malondialdehyde levels in acute exacerbation and stable periods of patients with chronic obstructive pulmonary disease. *Clin Invest Med* 2004; 27: 123-128.
20. Gogou E, Hatzoglou C, Chamos V, Zarogiannis S, Gourgoulis KI, Molyvdas PA. The contribution of ascorbic acid and dehydroascorbic acid to the protective role of pleura during inflammatory reactions. *Med Hypotheses* 2007; 68: 860-863.
21. Ozdulger A, Cinel I, Koksel O, Cinel L, Avlan D, Unlu A, et al. The protective effect of N-acetylcysteine on apoptotic lung injury in cecal ligation and puncture-induced sepsis model. *Shock* 2003; 19: 366-372.
22. Grey JD, Krukowski ZH, Matheson NA. Surgical mortality and morbidity in one hundred and twenty patients with obstructive jaundice. *Br J Surg* 1998; 75: 216.
23. Caglikulekci M, Besirov E, Ozkan H, Gundogdu H, Bakanay SM. The effect of granulocyte colony stimulating factor on the immune parameters in experimental obstructive jaundice. *Hepatogastroenterology* 2001; 48: 220-223.
24. Ma Z, Lee SS. Cirrhotic cardiomyopathy: getting to the heart of the matter. *Hepatology* 1996; 24: 451-459.
25. Assimakopoulos SF, Thomopoulos KC, Patsoukis N, Georgiou CD, Scopa CD, Nikolopoulou VN, et al. Evidence for intestinal oxidative stress in patients with obstructive jaundice. *Eur J Clin Invest* 2006; 36: 181-187.
26. Nakatani Y, Fukui H, Kitano H, Nagamoto I, Tsujimoto T, Kuriyama S, et al. Endotoxin clearance and its relation to hepatic and renal disturbances in rats with liver cirrhosis. *Liver* 2001; 21: 64-70.
27. Fallon MB, Abrams GA, McGrath JW, Hou Z, Luo B. Common bile duct ligation in the rat: a model of intrapulmonary vasodilatation and hepatopulmonary syndrome. *Am J Physiol* 1997; 272: G779-G784.
28. Sztymf B, Libert JM, Mougeot C, Lebec D, Mazmanian M, Humbert M, et al. Cirrhotic rats with bacterial translocation have higher incidence and severity of hepatopulmonary syndrome. *J Gastroenterol Hepatol* 2005; 20: 1538-1544.
29. Bernard GR. N-acetylcysteine in experimental and clinical lung injury. *Am J Med* 1991; 91: 54S-59S.
30. Borjesson A, Wang X, Sun Z, Wallen R, Deng X, Johansson E, et al. Effects of N-acetylcysteine on pulmonary macrophage activity after intestinal ischemia and reperfusion in rats / with invited commentaries. *Dig Surg* 2000; 17: 379-387.
31. Gogou E, Hatzoglou C, Chamos V, Zarogiannis S, Gourgoulis KI, Molyvdas PA. The contribution of ascorbic acid and dehydroascorbic acid to the protective role of pleura during inflammatory reactions. *Med Hypotheses* 2007; 68: 860-863.
32. Wilson JX. The physiological role of dehydroascorbic acid. *FEBS Lett* 2002; 527: 5-9.
33. Kearns SR, Kelly CJ, Barry M, Abdih H, Condron C, Leahy A, et al. Vitamin C reduces ischaemia-reperfusion-induced acute lung injury. *Eur J Vasc Endovasc Surg* 1999; 17: 533-536.
34. Vanisree AJ, Shyamaladevi CS. Effect of therapeutic strategy established by N-acetylcysteine and Vitamin C on the activities of tumour marker enzymes invitro. *Indian J Pharmacol* 1999; 31: 275-278.
35. Johnston CS, Meyer CG, Srilakshmi JC. Vitamin C elevates red blood cell glutathione in healthy adults. *Am J Clin Nutr* 1993; 58: 103-105.
36. Scott DA, Poston RN, Wilson RF, Coward PY, Palmer RM. The influence of Vitamin C on systemic markers of endothelial and inflammatory cell activation in smokers and non-smokers. *Inflamm Res* 2005; 54: 138-144.