

Noninsulinoma pancreatogenous hypoglycemia syndrome in a Saudi male

A diagnostic and management dilemma

Abdullah M. Karawagh, MD, FRCPC, Layla S. Abdullah, MD, FRCPC, Abdelhamid M. Gasim, MD, MRCP, Muntasir M. Abdelaziz, FRCP (Glasg), PhD.

ABSTRACT

النسلة عبارة عن فرط التنسج البؤري أو المنتشر لخلايا البنكرياس، والتي تؤدي إلى زيادة في إفراز هرمون الأنسولين، وينتج عنها هبوط السكر في الدم في عدم وجود ورم في البنكرياس. يظهر هذا المرض عادة عند الأطفال وحديثي الولادة. نستعرض الحالة الأولى للنسلة التي تم تشخيصها على مستوى المملكة العربية السعودية والخليج العربي في شخص بالغ. وعلى الرغم من استجابة المريض للعلاج الجراحي إلا أن أعراض هبوط السكر تعاوده بعض الأحيان مما استدعى إلى استخدام دواء يمنع هبوط السكر. الانطباع السائد أن النسلة تصيب حديثي الولادة والأطفال، إلا أن هناك حالات تصيب كبار السن والبالغين، والتي تشكل صعوبة وتحدي للأطباء في التشخيص والعلاج.

Nesidioblastosis is focal or diffuse islet hyperplasia leading to hyperinsulinism with subsequent hypoglycemia in the absence of insulinoma, usually described in neonates and infancy. We described the first adult case of nesidioblastosis in Saudi Arabia and the Gulf region. The diagnosis and treatment of the condition can be very difficult and challenging. Despite the fact that our patient responded initially to surgical treatment, his hypoglycemic symptoms occasionally recurred and needed adjunctive medical treatment. Although initially thought to affect only infants and children, cases of nesidioblastosis can affect adults and pose a diagnostic and therapeutic challenge to the clinicians.

Saudi Med J 2008; Vol. 29 (11): 1654-1657

From the Departments of Medicine (Karawagh, Gasim, Abdelaziz), King Khalid National Guard Hospital, and Pathology (Abdullah), King Abdulaziz University Hospital, Jeddah, Kingdom of Saudi Arabia.

Received 13th July 2008. Accepted 21st October 2008.

Address correspondence and reprint request to: Dr. Abdullah M. Karawagh, Department of Medicine, King Khalid National Guard Hospital, PO Box 9515, Jeddah, Kingdom of Saudi Arabia. Tel. +966 (2) 6240000 Ext. 21298. Fax. +966 (2) 6240000 Ext. 22765. E-mail: a_karawagh@yahoo.com

Nesidioblastosis is a term used to describe islet hyperplasia, which can be focal or diffuse.^{1,2} It is characterized by hypoglycemia, hyperinsulinism in the absence of insulinoma. Nesidioblastosis is often poorly responsive or unresponsive to medical management, necessitating pancreatectomy. It represents the most common cause of hyperinsulinism in neonates.¹ Although initially thought to affect only infants and children, numerous cases have been reported in adults of all ages.^{2,3} We report here an adult case of persistent hypoglycemia secondary to nesidioblastosis in Saudi Arabia and the Gulf region. We would like to highlight its importance as a cause of hypoglycemia in adults. The literature has been reviewed and addressed in relation to the case. We highlighted the importance of this condition as a cause of hypoglycemia in adults, and its diagnostic and therapeutic dilemma.

Case Report. A 75-year-old Saudi male, previously healthy, presented in September 2001 with episodes of dizziness, sweating, headache, palpitation, and feeling hungry for 4 months. All these symptoms were relieved after meals. He admitted that he gained 5 kilograms over the last month. The symptoms have gradually progressed over time in frequency and severity to the extent that it started to happen daily, and he required 2 admissions to the hospital because of decreased level of consciousness over one month. In October 2001, he presented at the emergency room with loss of consciousness and blood glucose of 1.5 mmol/l. He completely regained his consciousness without any neurological deficit after been given IV 50% dextrose. He was referred to our institution for further evaluation of hypoglycemia. The patient was admitted to the hospital and initial blood work for blood glucose, complete blood count, urea, creatinine, and liver function test was normal. The chest x-ray and electrocardiogram were normal. His thyroid function, morning cortisol, and parathyroid hormone were all normal. The patient was subjected to fasting

hypoglycemic test for 48-hours. His frequent blood glucose monitoring ranged between 4-6 mmol/l. While in hospital he had blood sample for serum insulin-like growth factor-1 (IGF-1), and this came to be normal. Computed tomography (CT) scan of the abdomen was unremarkable. Subsequently magnetic resonance imaging (MRI) of the pancreas and octreotide scan were performed and showed no abnormality. Endoscopic ultrasound was normal. He was scheduled to have pancreatic angiography with selective arterial calcium stimulation and hepatic venous sampling for blood glucose and C-peptide, and put on diazoxide, while waiting for the procedure. During hospitalization, he did not go into hypoglycemia. He was discharged home and given an appointment for readmission to have the planned investigation. One week after discharge he presented to the emergency room with dizziness, and his blood glucose was 2.0 mmol/l. The serum sample was sent for insulin and C-peptide and result came back later to be high at a level of 170Uu/ml for insulin (normal value up to 30Uu/ml) and 19.7ug/ml for C-peptide (normal value between 0.8-4.0). Repeat serum cortisol during this admission was normal. The blood glucose responded to 25% dextrose and his symptoms improved. One week later he underwent pancreatic angiography with selective arterial calcium stimulation and hepatic venous sampling for blood glucose and insulin C-peptide. The angiography was normal, and the result of the stimulation test failed to localize the presence of occult insulinoma (Table 1). The patient was referred to surgery where he had partial pancreatectomy. Gross examination of the pancreatic tissue was grossly unremarkable and serial sectioning failed to detect any tumor. Microscopic examination of the pancreatic tissue showed hyperplasia of islets with an increased number of randomly scattered islets both in pancreatic parenchyma as well as in the peripancreatic fat (Figures 1a & 1b). The hyperplastic islets were variable in size and shape and very close or immediately budding from the pancreatic ducts (ductuloinsular complexes) (Figure 2). The pathological picture was consistent with the diagnosis of nesidioblastosis. Following surgery he was free from hypoglycemia for 3 months, before he started again having symptoms of hypoglycemia and low blood glucose in the range of 2.5-3.0 mmol/l with high insulin level and C-peptide. A repeat MRI of the pancreas failed to show a tumor. He was treated with Diazoxide 25mg bid day. Since then he has not had symptoms of hypoglycemia and no drop in the blood glucose.

Discussion. We describe here a 75-year-old Saudi male of noninsulinoma hyper-insulinemic hypoglycemia. This novel syndrome of non-insulinoma pancreatogenous hypoglycemia is characterized histologically by nesidioblastosis (islet hyperplasia) in

Table 1 - Pancreatic angiography with selective arterial calcium stimulation and hepatic venous sampling for blood glucose and insulin C-peptide.

Time	Glucose (4.1-9.0 mmol/L)	Insulin C-peptide (298-1324 pmol/L)
15:04	5.8	797
15:05	5.6	895
15:06	5.8	974
15:07	5.9	530
15:08	5.5	

the absence of insulinoma.^{1,2,4} It is reported initially in infancy and associated with mutation of the β -cell sulfonylurea receptor gene or potassium channel (Kir 6.2) gene.^{5,6} It accounts for 0.5-5% of the cases of organic hyper-insulinemia and is characterized by spontaneous or post-prandial hypoglycemia with a high level of insulin secondary to diffuse non-neoplastic β -cell hyper-function and hyperplasia. The diagnosis is usually based on histological findings of diffuse nesidioblastosis in the absence of gross or microscopic tumor in the right clinical setting.² Although it is usually described in children, nesidioblastosis recently has been reported among the adult population, and may create a diagnostic and management dilemma for clinicians.²⁻⁴

Nesidioblastosis is characterized by the presence islet cell enlargement, β -cell budding off ductular epithelium and islets in apposition to ducts,^{2,4} both features were observed in our patient. These findings were not pathognomic of the syndrome of noninsulinoma hyper-insulinemic hypoglycemia, as autopsy changes of similar features were observed in 36% of normal individuals without hypoglycemia. Furthermore, changes consistent with nesidioblastosis were reported in association other conditions such as insulinoma, in those treated previously with insulin, or sulfonylureas, Werner Morrison, Zollinger-Ellison syndrome, and multiple endocrine neoplasia type I. However, in our case there was no-concomitant insulinoma detected on ultrasound, CT scan or histologically, the patient gave no history of insulin or hypoglycemic agent administration, octreotide scan was negative, and both thyroid and parathyroid hormones were normal. The presence of diffuse islet cell hyperplasia in the presence of high insulin level and absence of any alternative explanation of hypoglycemia is consistent with the noninsulinoma hyper-insulinemic hypoglycemic syndrome (nesidioblastosis).

The diagnosis of this unique syndrome is very difficult and should be considered when there is unexplained

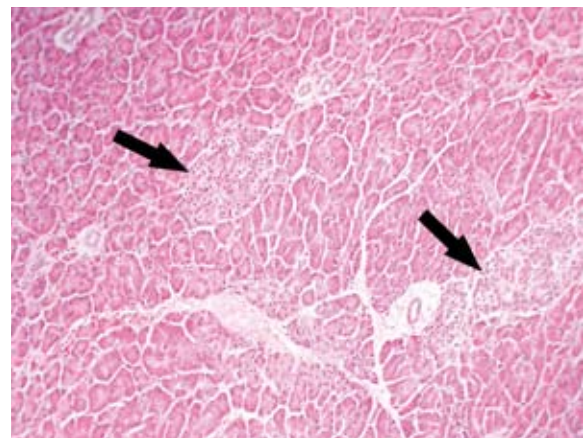
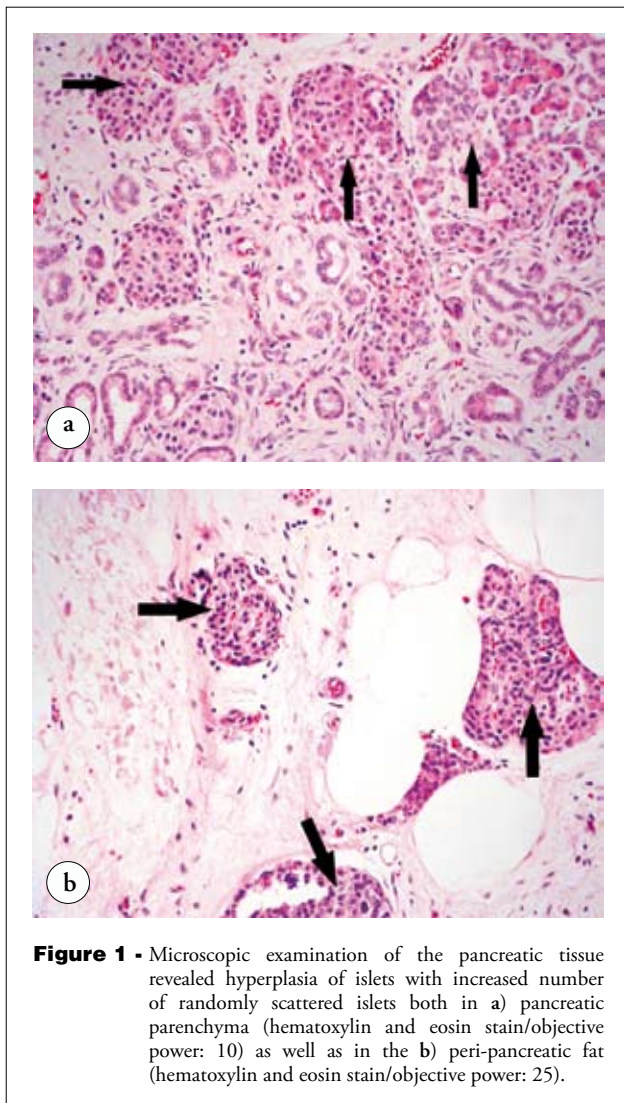


Figure 2 - Microscopic examination of the pancreatic tissue (hematoxylin and eosin stain/objective power: 25) showing hyperplastic islets variable in size and shape and very close or immediately budding from the pancreatic ducts (ductuloinsular complexes).

hypoglycemia despite extensive investigations. It is usually considered when preoperative imaging modalities fail to localize a lesion in patients with hyperinsulinism. Our patient presented with symptomatic hypoglycemia with normal liver, renal and thyroid function tests. Although 48-hour fasting failed to demonstrate significant hypoglycemia, the patient was subsequently admitted with documented hypoglycemia, during which both his insulin and C-peptide were abnormally high. We used 48 hours rather than 72 hours fast as this is kinder to the patient, and a study by Hirshberg et al,⁷ and Quinkler et al⁸ demonstrated that the necessary information could be obtained in the first 48 hours most of the time. A negative fasting test is an unlikely occurrence in patients with insulinoma. However, a negative fasting test seems to be a characteristic of non-focal noninsulinoma hyperinsulinemic hypoglycemia,^{2,5} which was the case in our

patient. As CT abdomen, endoscopic ultrasound, and octreotide scan all failed to demonstrate insulinoma, the patient was subjected to pancreatic angiography with selective calcium stimulation and hepatic venous sampling. Non-invasive imaging techniques, such as CT and MRI often fail to localize insulinoma smaller than 2cm in diameter. Boukhman et al⁹ examined the different investigation modalities used in localizing insulinoma and found that the sensitivities of CT scan to be 24% and MRI to be 30%. In contrast, selective calcium stimulation, and hepatic venous sampling demonstrated a high sensitivity approaching 100% in localizing insulin-secreting tumors.¹⁰ A negative test in our patient with negative radiological localizing studies reinforces the diagnosis of non-insulinoma islet cell hyperplasia. Subsequently the diagnosis was confirmed histologically after surgery. Despite the presence of many diagnostic modalities, the diagnosis of this condition remains a challenge and is usually confirmed after surgery. Service et al⁵ reported 5 cases of noninsulinoma hyper-insulinemic hypoglycemia, all of them confirmed histologically after pancreatectomy. Similarly, Writteles et al¹¹ studied 32 patients that underwent surgical exploration for hyperinsulinemic hypoglycemia and found 27 (84%) to have insulinomas, and 5 were diagnosed as nesidioblastosis postoperatively.

Noninsulinoma hyperinsulinemic hypoglycemia continues to be a treatment dilemma. Surgery remains the treatment of choice and distal pancreatectomy was found to be effective in controlling hypoglycemia in 60% (3/5) of the patients in one series. Similarly Service et al⁵ reported complete resolution of the symptoms following surgical resection in 4 out of 5 patients. Although our patient did respond initially to surgical treatment, and his hypoglycemic symptoms

recurred 3 months later. Our patient's hypoglycemic symptoms were subsequently controlled with Diazoxide. Therapeutic agents used in controlling hypoglycemia in this condition include glucagons, Diazoxide, calcium antagonist, and octreotide.

References

1. Al-Rabeeh A, al-Ashwal A, al-Herbish A. persistent hyperinsulinemic hypoglycemia of infancy: experience with 28 cases. *J Pediatr Surg* 1995; 30: 1119-1121.
2. Won JG, Tseng HS, Yang AH, Tang KT, Jap TS, Lee CH, et al. Clinical features and morphological characterization of 10 patients with noninsulinoma pancreatogenous hypoglycaemia syndrome (NIPHS). *Clin Endocrinol (Oxf)* 2006; 65: 566-578.
3. Soleiman A, Schindl M, Passler C, Scheuba C, Prager G, Kaserer K, et al. Nesidioblastosis in adults: a challenging cause of organic hyperinsulinism. *Eur J Clin Invest* 2003; 33: 488-492.
4. Sahloul R, Yaqub N, Driscoll HK, Leidy JW Jr, Parkash J, Matthews KA, et al. Noninsulinoma pancreatogenous hypoglycemia syndrome: quantitative and immunohistochemical analyses of islet cells for insulin, glucagon, somatostatin, and pancreatic and duodenal homeobox protein. *Endocr Pract* 2007; 13: 187-193.
5. Service FJ, Natt N, Thompson GB, Grant CS, van Heerden JA, Andrews JC, et al. Non-insulinoma pancreatogenous hypoglycemia: a novel syndrome of hyperinsulinemic hypoglycemia in adults independent of mutations in Kir 6.2 and Sur1 genes. *J Clin Endocrinol Metab* 1999; 84: 1582-1589.
6. Darendeliler F, Fournet JC, Bas F, Junien C, Gross MS, Bundak R, et al. ABCC8 (SUR1) and KCNJ11 (KIR6.2) mutations in persistent hyperinsulinemic hypoglycemia of infancy and evaluation of different therapeutic measures. *J Pediatr Endocrinol Metab* 2002; 15: 993-1000.
7. Hirshberg B, Livi A, Bartlett DL, Liputti SK, Alexander HR, Doppman JL, et al. Forty-eight hour fast: The diagnostic test for insulinoma. *J Clin Endocrinol Metab* 2001; 86: 2328-2329.
8. Quinkler M, Strelow F, Pirlich M, Rohde W, Biering H, Lochs H, et al. Assessment of suspected insulinoma by 48-hour fasting test: a retrospective monocentric study of 23 cases. *Horm Metab Res* 2007; 39: 507-510.
9. Boukhman MP, Karam JM, Shaver J, Siperstein AE, Delorimier AA, Claark OH. Localization of insulinomas. *Arch Surg* 1999; 134: 818-822.
10. Brandle M, Pfammatter T, Spinass GA, Lehmann R, Schmid C. Assessment of selective arterial calcium stimulation and hepatic venous sampling to localize insulin secreting tumors. *Clin Endocrinol* 2001; 55: 357-362.
11. Wittteles RM, Straus II FH, Sugg SL, Koka MR, Costa EA, Kaplan EL. Adult-onset nesidioblastosis causing hypoglycemia: an important clinical entity and continuing treatment dilemma. *Arch Surg* 2001; 136: 656-663.

Related topics

Nikeghbalian S, Bananzadeh A, Yarmohammadi H. Hypoglycemia, the first presenting sign of hepatocellular carcinoma. *Saudi Med J* 2006; 27: 387-388.

Zayeri F, Kazemnejad A, Ganjali M, Babaei G, Khanafshar N, Nayeri F. Hypothermia in Iranian newborns. Incidence, risk factors and related complications. *Saudi Med J* 2005; 26: 1367-1371.

Badawoud MH. Development of fetal rat pancreatic islet A cells. A quantitative and immunocytochemical study. *Saudi Med J* 2006; 27: 1311-1314.