

Unusual outcome of Ludwig's angina

Kamal-Eldin A. Abou-Elhamd, MSc, MD, Maaidah A. Al-Rasheed, MBBS, MD, Ahmed Jawad, MBBS, MD.

ABSTRACT

ذبحة لودويق الرقبية، هي عبارة عن التهاب بكتيري حاد يصيب طبقة ما تحت جلد الفك السفلى وأرضية الفم مما يسبب تورم قد يصل إلى منطقة الحنجرة فيسبب ضيق في مجرى التنفس مما يؤدي إلى الاختناق فالموت إذا لم يعالج بسرعة وبالطريقة الطبية السليمة. نستعرض في هذا التقرير حالتين غير مألوفتين في تطور إصابتهما. الأولى لفتاة اندونيسية، تطورت التهابات لديها إلى ما تحت الفك السفلى مما سبب لها اختناق بمجرد استخدام خافض اللسان للكشف على فمها، وتم تركيب أنبوبة شق قصبي وبمجرد إزالتها بعد تحسن الالتهابات أصيبت المريضة بصعوبة بالتنفس نتيجة لتجمع الهوائي تحت جلد الصدر والرقبة. والحالة الثانية لشاب هندي أصيب باختناق بعد خلع احد أضراسه، وتم أيضا تركيب أنبوبة شق قصبي ولكن المريض أصيب بنزيف متكرر وحاد من جميع الأنسجة نتيجة تخثر في الدم مما أدى إلى وفاته.

This is a report of 2 cases of Ludwig's angina. An Indonesian young female patient developed severe stridor after oral examination. Then she underwent tracheostomy and developed post decannulation dyspnea due to huge surgical emphysema. The second case regards an Indian young male who developed disseminated intravascular coagulation and died from hemorrhage. The objectives of our cases presentation are to avoid mouth examination of Ludwig's angina if we are not ready for performing tracheotomy and to be aware of the possible development of disseminated intravascular coagulation and post decannulation emphysema.

Saudi Med J 2008; Vol. 29 (12): 1811-1814

From the Department of Surgery (Abou-Elhamd), Al-Ahsa College of Medicine, King Faisal University, and the Department of Ear, Nose and Throat (Al-Rasheed, Jawad), Al-Jabr Eye and Ear, Nose and Throat Hospital, Al-Ahsa, Kingdom of Saudi Arabia.

Received 26th August 2008. Accepted 3rd November 2008.

Address correspondence and reprint request to: Dr. Kamal-Eldin A. Abou-Elhamd, Department of Surgery, Al-Ahsa College of Medicine, King Faisal University, PO Box 400, Al-Ahsa 31982, Kingdom of Saudi Arabia. Tel. +966 508580065. Fax. +966 (3) 5801243. E-mail: Kamal375@yahoo.com

The German physician Karl Wilhelm Frederick von Ludwig was the first to describe Ludwig's angina in 1836 as a potentially fatal, rapidly spreading infection of the neck and floor of the mouth.¹ Although Ludwig's angina is rare, it is very clinically important as it might lead to death due to airway obstruction. Dental problems are the cause in approximately 85% of cases of Ludwig's angina especially the lower second and third molar teeth. Other causes include peritonsillar abscess, parapharyngeal abscess, submandibular sialadenitis and penetrating injuries to the floor of the mouth.² Diabetes mellitus, anemia, malnourishment, intravenous drug use and alcoholism are systemic predisposing factors.³ *Alpha hemolytic streptococci*, *staphylococci*, and *bacteroides* are the common involved organisms. The apices of the lower second and third molar teeth extend below the insertion of the mylohyoid muscle into the mandible. Any dental abscess may extend around the mylohyoid muscle reaching the sublingual space raising the tongue superior and posterior leading to airway compression. The patient usually presents with neck swelling, dysphagia, odynophagia, fever, malaise, and drooling. On examination, tender indurated brawny submandibular swelling and elevated tongue are the common clinical signs. Fever and tachycardia are associated signs. Carious molar tooth and trismus are sometimes found. Ultrasonography and CT are the best methods of investigation to demonstrate cellulitis stage or to confirm and localize the collection of pus.⁴ Treatment should be fast and the patient should be under close observation. Admission is mandatory and securing of the airway patency is the main goal of treatment. If there is any stridor or airway compromise, awake fiberoptic intubation or awake tracheotomy is the safest way to save the patient life as tongue elevation and laryngeal edema may obstruct the airway in a fast dramatic unexpected scenario. If the airway is patent, intravenous potent antibiotics against aerobic and anaerobic organisms, and steroid should be injected in maximum allowed doses. Penicillin G 2.4 gm daily in 4 divided doses combined with metronidazole 500 mg every 8 hours are the best antibiotics to start.⁵ If the patient is hypersensitive to penicillin, clindamycin

600mg every 8 hours is the best substitute.⁴ Intravenous dexamethasone 10 mg as an initial dose followed by 4 mg every 6 hours for 2 days resolves edema and cellulitis, provides chemical decompression, protects the airway and allows better antibiotic penetration.^{2,6} If there is no clinical improvement within 24 hours of medical treatment or there is abscess collection, surgical decompression should not be delayed. Although pus production is of low tendency in Ludwig's angina, surgical decompression by incision can relieve airway obstruction. Computerized tomography-guided percutaneous drainage is a safe, fast and highly effective low-cost alternative method for surgical drainage.⁷ Complicated Ludwig's angina may present with mediastinitis, empyema, subphrenic abscess or infection of the carotid sheath.⁸

Case Report. *Patient one.* A 22-year-old Indonesian female patient presented in July 2005 to the outpatient Ear, Nose and Throat clinic of Ghassan Najeeb Pharoan Hospital, Khamis Mushayt, Kingdom of Saudi Arabia with a history of dysphagia, odynophagia, fever, and right neck swelling. On examination, right tender submandibular brawny indurated swelling with elevation of the tongue and drooling due to associated trismus were revealed. Blood investigations showed: red blood cells $4.5 \times 10^9/\text{dL}$ (normal range: $3.8 \times 10^9/\text{dL}$), hemoglobin 11 gm/dL (normal range: 11.5-16.5 gm/dL), hematocrit 36% (normal range: 37-47%), mean corpuscular volume 78 fl (normal range: 80-97 fl), platelets $317 \times 10^9/\text{L}$ (normal range: $120-500 \times 10^9/\text{L}$), white blood cells $14 \times 10^9/\text{L}$ (normal range: $4-11 \times 10^9/\text{L}$), neutrophils $11.5 \times 10^9/\text{L}$ (normal range: $2-7.5 \times 10^9/\text{L}$), albumin 35 g/L (normal range: 35-50 g/L), random blood sugar 8 mmol/L (normal range: up to 10 mmol/L), sodium 140 mmol/L (normal range: 135-145 mmol/L), potassium 3.4 mmol/L (normal range: 3.5-5.2 mmol/L), creatinine 60 $\mu\text{mol}/\text{L}$ (normal range: 48-97 $\mu\text{mol}/\text{L}$), prothrombin time 14 seconds (normal range: 11-14 seconds), international normalized ratio 1.27 (normal range: 0.8-1.2), and human immunodeficiency virus (HIV) was negative. The CT neck was requested and showed localized inflammatory swelling on the right side of the mandible without abscess formation. The patient was admitted and medical treatment under close observation was started. Intravenous injection of Rocephin (ceftriaxone) 2 gm/24 hours, intravenous injection of Solu-Cortef (hydrocortisone) 250 mg/12 hours, intravenous infusion of 1 gm metronidazole/12 hours and suppositories of Tylenol (acetaminophen) 350 mg/8 hours were the starting medical treatment. The patient stopped oral feeding and supportive treatment in the form of parenteral saline 500cc/12 hours and 5% glucose 500cc/8 hours was also given.

The patient must sleep in semi-sitting position and the general practitioner on duty was instructed to observe her breathing and contact the author if any develop stridor while starting oxygenation. Five hours after admission, severe stridor developed after the general practitioner had examined the mouth cavity of the patient using tongue depressor. The patient was transmitted fastly to the intensive care unit for monitoring under pulse oximetry and for oxygenation. Awake tracheotomy was performed in the operation room under local anesthetic. The result of the examination of the dentist revealed periodical abscess related to the lower third molar tooth after performing panoramic x-ray of the mandible. The following day, drainage of the dental abscess with extraction of the lower third molar tooth under general anesthesia was performed. The induration of the submandibular region did not improve in spite of the drainage. Culture of the pus did not show organisms. We substituted Rocephin (the antibiotic) with Augmentin (amoxicillin plus clavulanic acid) 1.2 gm intravenous every 12 hours. A great improvement was noticed. Three days later, the neck was back to normal and tracheotomy was closed. Three hours after closure of the tracheotomy, the patient was in severe dyspnea and on examination there was a diffuse subcutaneous emphysema. Computerized tomography was performed (Figure 1). The patient underwent exploration of the site of closure of the tracheotomy, there was a leak of air between the tracheal opening and the subcutaneous tissue. Closure of the tracheal stoma with closure of the covering subcutaneous tissue and skin were performed under local anesthesia. After 3 days, the patient was in good healthy condition and she was discharged. On her follow up for 3 months, the patient did not show any clinical abnormality.

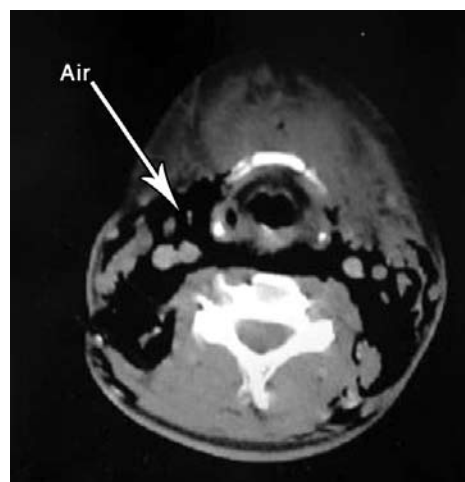


Figure 1 - Axial CT neck shows air between the neck spaces.

Patient 2. A 32-year-old diabetic Indian driver presented in December 2007 to the Ear, Nose and Throat Emergency room of Al-Jabr Eye and Ear, Nose and Throat Hospital in Al-Ahsa, Kingdom of Saudi Arabia with history of dysphagia, odynophagia, fever, and right neck swelling for the last 5 days after right lower second molar tooth extraction. On examination, right hot tender submandibular and submental brawny indurated swelling with elevation of the tongue and drooling due to associated trismus were revealed. Examination of the mouth revealed soft palate edema with deviation of the uvula to the left. The temperature was 39°C. A diagnosis of Ludwig's angina was made and the patient was admitted. Blood investigations showed: red blood cells $3.9 \times 10^9/\text{dL}$ (normal range: $4.5\text{-}6.5 \times 10^9/\text{dL}$), hemoglobin 16.2 gm/dL (normal range: 13-18 gm/dL), hematocrit 36% (normal range: 40-54%), mean corpuscular volume 78 fl (normal range: 80-97 fl), platelets $277 \times 10^9/\text{L}$ (normal range: $120\text{-}500 \times 10^9/\text{L}$), white blood cells $22.3 \times 10^9/\text{L}$ (normal range: $4\text{-}11 \times 10^9/\text{L}$), differential count was 65% polymorphs, 28% lymphocytes, 9% monocytes, and 3% eosinophils, blood urea nitrogen 8.4 mmol/L [normal range: 1.7-8.3 mmol/L (7-21mg/dL)], albumin 35 g/l (normal range: 35-50 g/L), random blood sugar 8.3 mmol/L (normal range: up to 10 mmol/L), sodium 137 mmol/L (normal range: 135-145 mmol/L), potassium 4 mmol/L (normal range: 3.5-5.2 mmol/L), creatinine 79 $\mu\text{mol}/\text{L}$ (normal range: 48-97 $\mu\text{mol}/\text{L}$), prothrombin time 13.8 seconds (normal range: 11-14 seconds), partial thromboplastin time 33.9 seconds (normal range: 25-43 seconds), international normalized ratio 1.2 (normal range: 0.8-1.2), and HIV test was negative. Computerized tomography of the neck was requested. Axial pre- and post- intravenous contrast CT showed right submental heterogeneous soft tissue swelling with air and fluid collection at its center (abscess) extending laterally beside the right mandibular ramus (submandibularly) (Figures 2-4). The lesion was associated with marked soft tissue edema extending to the epiglottic area, glottic area, and the retro-sternal space.

Medical treatment under close observation was started. Intravenous injection of cefotaxime 1 gm/12 hours, intravenous infusion of 500 mg metronidazole/8 hours, intravenous injection of gentamycin 80 mg/8 hours and intramuscular injection of voltaren 75 mg/ 12 hours were the starting medical treatment with insulin controlling his diabetes. The patient was instructed to stop the oral feeding and supportive treatment in the form of parenteral saline 500cc /12 hours and 5% glucose 500 cc/8 hours was also given. The following day, the patient was taken to the theatre and incision and drainage of serosanguous fluid at the right submandibular area under general anesthesia was performed. One hour later, the patient started to desaturate and was transferred to the intensive care unit. After 6 days, the patient started to

spit fresh blood from the mouth in large amounts and his pulse became rapid and weak, 2 units of fresh blood was transfused to the patient. Cricothyroidotomy was performed and laryngoscopy revealed a blood clot on the right side of the soft palate near the upper pole of the tonsil. On its removal, profuse blood was started to come from 1x1 cm opening on the right side of the soft palate near the upper pole of the tonsil and the bleeding was controlled by application of Surgicel pack (Johnson & Johnson Medical Ltd, Gargrave, North Yorkshire, UK). Tracheostomy replaced the cricothyroidotomy. One hour later, the patient started to desaturate again and he had a cardiac arrest. Resuscitation was successful. Two hours later, rebleeding from the tracheostomy site occurred and was controlled. Then, after one

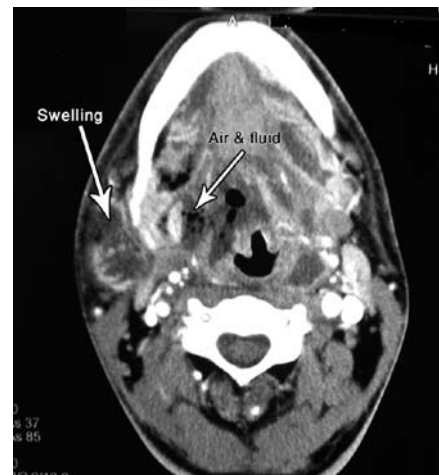

Figure 2 - Axial neck CT post-contrast shows right parapharyngeal heterogeneous soft tissue swelling with air and fluid collection at its center (abscess) extending laterally beside the right mandibular ramus. The lesion is associated with marked soft tissue edema extending to the epiglottic area.

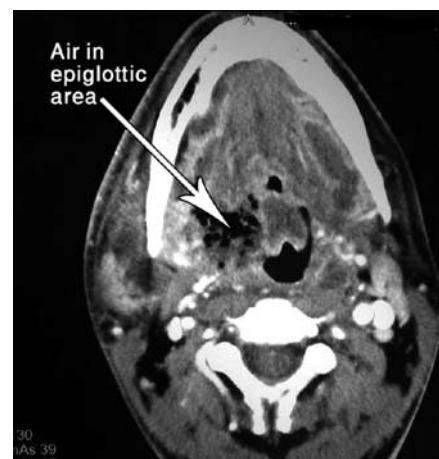

Figure 3 - Axial neck CT post-contrast shows right parapharyngeal air extending medially to the epiglottic area and glottic area.

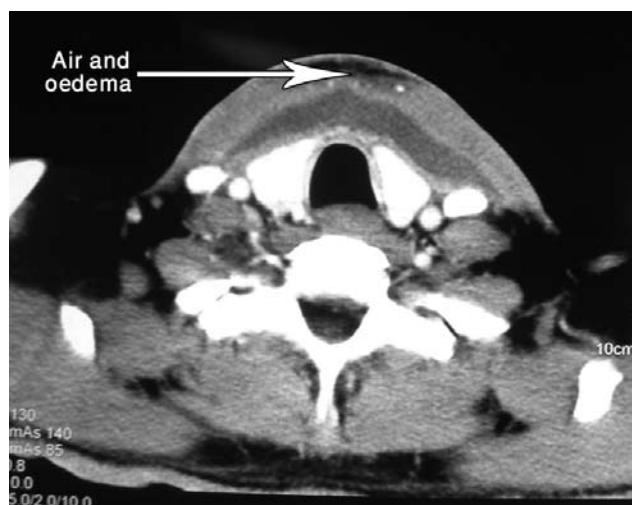

Figure 4 - Axial neck post-contrast CT shows subcutaneous air and the retro-sternal space soft tissue edema.

hour, rebleeding started from the nose. Diagnosis of disseminated intravascular coagulation was made clinically. One hour later, the patient died.

Discussion. Ludwig's angina is a diffuse inflammation of the submandibular, sublingual and submental neck spaces. It is a fatal condition if it is not treated properly in due time. It starts as cellulitis of the floor of the mouth and extends to elevate the tongue superior and posterior with development of supraglottic edema. Early aggressive medical treatment is mandatory. Proper choice of antibiotic has a great outcome. If there is no improvement, culture from the focus of infection should not be delayed (usually dental focus). The failure of isolation of the organism in many cases is a result of the prior empirical antibiotic treatment and the anaerobic nature of some organisms.⁹ Early surgical intervention is essential if an abscess was found. In a clinical review of cases of Ludwig's angina, all patients presented with fever, bilateral submandibular swelling and elevation of the tongue.⁶ In 89% of them, the cause was dental infection. Tracheostomy was performed in 11% of them. Seventy-seven percent needed surgical decompression. However, in Ludwig's angina, the tendency for abscess formation is low. In spite of this, 50% of cases present with difficulty in breathing. The causative organism is gram negative in 76% of cultured deep neck abscesses in a published series.¹⁰ In an earlier review of a large group of Ludwig's angina patients, tracheostomy was performed in 52% of adults and 10% of patients died.¹¹ Surgical drainage was performed in 81% of adults. The dental infection was the cause of Ludwig's angina in 52% of adult cases in this series. Tracheostomy was performed in 75% of a series of 16 patients.¹² The mortality rate was 29% in another series.¹³ We think

the fatal outcome of this disease despite the progress in medicine is due to many factors. They are the rarity of the presentation of the disease, the underestimation of early aggressive management of these cases and the reluctance of surgeons to perform tracheotomy in due time. However, in a series came from Liverpool in England, conservative treatment was enough in 72% of cases.¹⁴ To our knowledge, there was no publication of development of disseminated intravascular coagulation in cases of Ludwig's angina as in our second case.

In conclusion, Ludwig's angina is still a fatal medical problem in spite of the era of modern potent antibiotics and early diagnosis. Early and proper treatment of dental infections is essential to avoid its spread to the deep neck spaces. Oral examination should be in the theatre with everything ready for tracheotomy. Attention to airway patency, potent intravenous antibiotics and surgical intervention on time is the pillars of its proper management. So, monitoring of patients with Ludwig's angina in the intensive care unit with a pulse oximeter is recommended for better outcome.

References

1. Wasson J, Hopkins C, Bowdler D. Did Ludwig's angina kill Ludwig? *J Laryngol Otol* 2006; 120: 363-365.
2. Busch RF, Shah D. Ludwig's angina: improved treatment. *Otolaryngol Head Neck Surg* 1997; 117: S172-S175.
3. Baqain ZH, Newman L, Hyde N. How serious are oral infections? *J Laryngol Otol* 2004; 118: 561-565.
4. Barakate MS, Jensen MJ, Helmi JM, Graham AR. Ludwig's angina: report of a case and review of management issues. *Ann Otol Rhinol Laryngol* 2001; 110: 453-456.
5. Chow AW. Life threatening infections of the head and neck. *Clin Infect Dis* 1992; 14: 991-1002.
6. Srirompotong S, Art-smart T. Ludwig's angina: a clinical review. *Eur Arch Otorhinolaryngol* 2003; 260: 401-403.
7. Thanos L, Mylona S, Kalioras V, Pomoni M, Batakis N. Potentially life-threatening neck abscesses: Therapeutic management under CT-guided drainage. *Cardiovasc Intervent Radiol* 2005; 28: 196-199.
8. Britt JC, Josephson GD, Gross CW. Ludwig's angina in the pediatric population: report of a case and review of the literature. *Int J Pediatr Otorhinolaryngol* 2000; 52: 79-87.
9. Zeitoun IM, Danarajani PJ. Cervical cellulitis and mediastinitis caused by odontogenic infections: Report of two cases and review of literature. *J Oral Maxillofac Surg* 1995; 53: 203-205.
10. Sethi DS, Stanley RE. Deep neck abscesses-changing trends. *J Laryngol Otol* 1994; 108: 138-143.
11. Kurien M, Mathew J, Job A, Zachariah N. Ludwig's angina. *Clin Otolaryngol* 1997; 22: 263-265.
12. Esquivel Bonilla D, Huerta Ayala S, Molina Moguel JL. Report of 16 cases of Ludwig's angina: 5 year review. *Pract Odontol* 1991; 12: 24-28.
13. Iwu C. Ludwig's angina: report of seven cases and review of current concepts in management. *Br J Oral Maxillofac Surg* 1990; 28: 189-193.
14. Greenberg SL, Huang J, Chang RS, Ananda SN. Surgical management of Ludwig's angina. *ANZ J Surg* 2007; 77: 540-543.