# Accuracy of single versus combined use of ultrasonography or computed tomography in the localization of parathyroid adenoma

*Nidal A. Younes, MD, MSc, Azmi M. Hadidi, MD, Walid S. Mahafzah, MD, Emad S. Tarawneh, MD, Yumna F. Al-Khatib, MD, MSc, Ahmad S. Sroujieh, MD, FRCS.*

## ABSTRACT

**الأهداف:** الهدف من هذه الدراسة هو دقة الأشعة الصوتية أو التصوير الطبقي بشكل منفرد أو جماعي في تحديد موضع اعتلالات الغدة الدرقية.

**الطريقة:** أجريت الدراسة على (٤١) مريض تم تشخيصهم بفرط الغدة الدرقية الأولي من يناير ٢٠٠٠ وحتى ديسمبر ٢٠٠٥ تم مراجعة تقارير الأشعة فوق الصوتية والتصوير الطبقي التي أجريت لهؤلاء المرضى قبل إجراء العملية ومقارنتها مع التشخيص أثناء العملية والتشخيص الباثولوجي للغدة الدرقية المصابة.

**النتائج:** متوسط عمر المرضى في هذه الدراسة كان (٤٦) سنة (النطاق ١٦ – ٧٠ سنة) (١٥ رجال) و (٢٦ نساء) تم تشخيص الورم الدرقي في (٣٣) مريض وتضخم الغدة الدرقية في (٨) مرضى، أجري التصوير الطبقي لـ (٣٢ مريض) و بالأشعة فوق الصوتية (٢٣) مريضا قبل إجراء العملية. تم تشخيص مرض الغدة الدرقية بواسطة التصوير الطبقي لوحده عند (١٨ مريض) بينما شخص مرض الغدة الدرقية بواسطة الأشعة فوق الصوتية لوحدها عند (٩ مرضى) واحتاج (١٤) مريض إلى إجراء كل من التصوير الطبقي والأشعة فوق الصوتية لتشخيص مرض الغدة الدرقية حيث تم الحصول على تشخيص صحيح عند (١٢ مريض) معطياً حساسية ٨٦٪ و ١٠٠٪ قيمة تنبئية ايجابية بينما كانت حساسية الاستعمال المنفرد للأشعة الصوتية منخفضة (٣٩٪) ومرتفعة إلى (٧٨٪) عند استخدام التصوير الطبقي.

**خاتمه:** إن حساسية التصوير الطبقي للرقبة منفردا مقاربة لاستخدام المشترك الأشعة فوق الصوتية و التصوير الطبقى في تحديد موضع الغدد الدرقية المصابة ولكن الاستخدام المشترك لهذه التقنيات يعطي أفضل دقة في التشخيص.

**Objectives:** To assess the accuracy of a single versus combined use of ultrasound (US), or computed tomography (CT) in the localization of diseased parathyroid glands.

**Methods:** Forty-one patients with hyper-parathyroidism treated surgically between January 2000 to December 2005 at Jordan University Hospital, Amman, Jordan were included in this study. Preoperative ultrasonographic and CT findings were reviewed and compared to the intraoperative and pathologic diagnosis of diseased parathyroid glands.

**Results:** The mean age of patients was 46 years (range 16-70; 15 males and 26 females). Parathyroid adenoma was confirmed in 33 patients and hyperplasia of the parathyroid glands in 8 patients. Preoperative evaluation was carried out in 32 patients (CT scan), and in 23 patients (US). In 18 cases, the diagnosis of parathyroid disease was based on CT findings alone and in 9 patients the diagnosis was based on single US findings. Combined CT and US evaluation was carried out in 14 cases and accurate localization was reached in 12 cases yielding 86% sensitivity and 100% positive predictive value. The independent use of these techniques alone resulted in low (39%) sensitivity for US and high (78%) sensitivity values for the CT.

**Conclusion:** Neck CT scan evaluation has almost an equivalent sensitivity to combined CT and neck US in the preoperative localization of diseased parathyroid glands, however the combined use of these techniques provides the best diagnostic accuracy.

***Saudi Med J 2008; Vol. 29 (2): 213-217***

*From the Departments of Surgery (Younes, Sroujieh), and Radiology (Hadidi, Mahafzah, Tarawneh, Al-Khatib), Faculty of Medicine, Faculty of Medicine, University of Jordan, Amman, Jordan.*

*Received 6th August 2007. Accepted 12th December 2007.*

*Address correspondence and reprint request to: Dr. Nidal A. Younes, Department of Surgery, Jordan University, PO Box 13024, Amman 11942, Jordan. Tel. +962 795686312. Fax. +962 (6) 5353388. E-mail: niyounes@ju.edu.jo*

Surgical excision of diseased parathyroid glands is generally considered the treatment of choice in all patients with primary and tertiary hyperparathyroidism (HPT) and in minority of patients with secondary HPT, with a reported success rate of 90-95%.[1-3] It is increasingly being recognized that the treatment of choice for patients with primary HPT is minimally invasive surgery with limited unilateral neck exploration. This approach requires an accurate preoperative localization for complete excision of diseased parathyroid glands.[4,5] Many diagnostic protocols currently exist (combination of high-resolution ultrasound [US], radionuclide imaging, computed tomography [CT] and magnetic resonance imaging for the preoperative localization of diseased parathyroid glands).[6,7] Although it is easy to identify and treat large parathyroid adenomas by an experienced endocrine surgeon, it is the patient with small diseased parathyroid glands or patients with ectopic parathyroid adenomas that poses the greatest diagnostic dilemma. The aim of this study is to assess the accuracy of single versus combined use of US, or CT in the localization of diseased parathyroid glands in a single center over a 5-year period.

**Methods.** A cross-sectional chart review study was conducted among patients diagnosed with HPT at Jordan University Hospital, Amman, Jordan from January 2000 to December 2005. Inclusion in the study also required availability of the results of a CT scan, US either single or combined and biochemical profile including calcium (Ca), phosphorus, alkaline phosphatase, and serum intact parathyroid hormone (i-PTH). Patients with secondary and tertiary HPT and those who did not have preoperative localization studies were excluded from the study. Data were collected by chart review by independent reviewer trained for this study. The clinical diagnosis of HPT was based on the finding of elevated parathyroid hormone and elevated serum calcium concentration, or inappropriately normal or elevated Ca/i-PTH levels. The following demographic and historical data were extracted for each subject: age, gender, indications for surgery and, preoperative radiological evaluation (CT, US). Patients were divided into 3 groups; Group 1 consisted of 32 patients who underwent a CT neck evaluation of the parathyroid glands, Group 2 consisted of 23 patients who underwent neck US evaluation and Group 3 consisted of 14 patients who had combined CT and US neck evaluation. The correlation between the preoperative evaluation and the intraoperative and pathologic diagnosis of diseased parathyroid glands was established. Criteria for US diagnosis of parathyroid adenomas were the presence of discrete, oval, anechoic or hypoechoic masses usually located posterior to the thyroid gland and, frequently, medial to the common carotid artery with an echogenic line that separates the thyroid gland from the enlarged parathyroid gland. Criteria for CT diagnosis of parathyroid adenoma was an enhancing soft-tissue mass near the expected location of the parathyroid glands, which is usually hypervascular structure with variable contrast enhancement. Radiological diagnosis of parathyroid adenoma was made if it fulfilled the CT/US criteria for adenomas (single or double enlarged parathyroid glands) and hyperplasia (if all parathyroid glands were visualized). Final diagnosis of adenoma versus hyperplasia of the parathyroid glands was confirmed histopathologically. The Scientific Research Committee at the Faculty of Medicine approved the study protocol.

We calculated sensitivity (the number of diseased parathyroid glands at imaging and the number of diseased parathyroid glands at histology). Positive predictive value (the number of diseased parathyroid at imaging and the number of diseased parathyroid at imaging) was also calculated.

**Results.** Forty-one patients met the inlcusion criteria. The mean age was 46 years (range 16-70), (15 males and 26 females). Serum phosphate, calcium, alkaline phosphatase, and i-PTH levels were measured (**Table 1**). Indications for surgery are shown in **Table 2**. Sixty diseased parathyroid glands were obtained from 41 patients who underwent surgery. All 41 patients were diagnosed with hyperparathyroidism, 33 patients with parathyroid adenoma, and 8 patients with hyperplasia of the parathyroid gland. Among the 23 cases with preoperative US evaluation, the diagnosis of 9 cases was based on the US alone, 5 patients had false positive results (sensitivity 39%; positive predictive value 64%) (**Table 3**), and in 14 cases the U/S results were non-conclusive and a subsequent CT was performed and revealed parathyroid disease in 12 cases with no false positive results (sensitivity 86% and positive predictive value 100%). Preoperative parathyroid localization using the CT scan was carried out in 32 patients. In 18 cases the diagnosis was based on single CT findings, and in 14 cases on combined CT and U/S results. Abnormal parathyroid glands were diagnosed in 25 patients and 2 patients had false positive findings (CT sensitivity 78%, positive predictive value 92.5%) and 7 patients had negative findings of parathyroid disease (**Table 3**). Diseased parathyroid glands were missed by CT or U/S or both in 13 patients, the average size of the glands in these patients was 990 mg. In the 5 cases missed by the CT scan alone, the parathyroid adenomas were strongly enhancing and they were

**Table 1 -** Summary of laboratory results of patients with hyperparathyroidism.

| Laboratory | n (%) |
|---|---|
| *Calcium level (mg/dl)* | |
| <8.5 | 2 (4) |
| 8.5-10 | 10 (24) |
| 10 -10.5 | 3 (7) |
| 10.5-11 | 16 (39) |
| >11 | 9 (21) |
| *Phosphorus level (mg/dl)* | |
| <2.4 | 24 (58) |
| 2.5-3 | 10 (24) |
| 3.1-4.5 | 4 (9) |
| >4.5 | 2 (4) |
| *Parathyroid hormone (mg/dl)* | |
| 54-100 | 3 (7) |
| 100-500 | 14 (56) |
| 500-1000 | 4 (16) |
| >1000 | 4 (16) |

**Table 2 -** Indications for surgery.

| Indications for surgery | n (%) |
|---|---|
| Generalized weakness and pain | 19 (46) |
| Musckle weakness | 13 (31) |
| Renal stones | 11 (26) |
| Frafture bones | 7 (17) |
| Swelling | 4 (10) |
| Asymptomatic | 4 (9) |

*not primary outcomes

**Figure 1-** A contrast-enhanced CT scan shows a small 0.7 cm inferior parathyroid adenoma (arrow) which strongly enhancing interpreted as vascular structure.

interpreted as a vascular structures (**Figures 1 & 2a**), in 3 cases the adenoma was closely attached to the thyroid and interpreted as thyroid nodule (**Figures 2b & 3**), in one case the parathyroid adenoma was interpreted as a lymph node. Among the 8 patients with parathyroid hyperplasia; 4 patients (50%) had diseased glands which were <500 mg in weight and were located in normal parathyroid position. None of these 4 patients had a positive CT evaluation. Among the 14 cases of diseased parathyroid glands, which were missed by the US, the small size of the diseased gland and the confusion with thyroid nodules or cervical lymph nodes were the main reasons for false negative results.

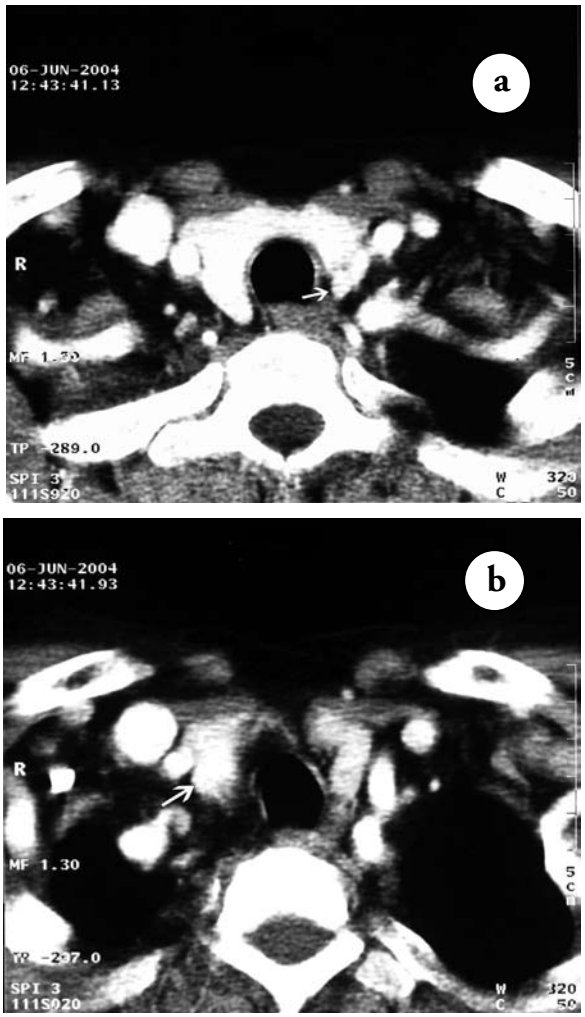


**Figure 2 -** A contrast-enhanced CT scan showing **a**) small parathyroid adenoma (0.5cm) on the left side (arrow), which was strongly enhancing and interpreted as a vascular structure, **b**) a parathyroid adenoma on the posteroinferior aspect of the right lobe (arrow) with similar density and enhancement to the adjacent thyroid interpreted as a thyroid nodule.

**Discussion.** Experienced endocrine surgeons have a 90-98% success rate in finding diseased parathyroid glands in patients with hyperparathyroidism during bilateral neck exploration with less than 5% mortality rate.[8,9] This approach however, requires relatively long operative time and post-operative hospitalization, and is associated with an increased risk of neck fibrosis resulting from extensive exploration and large neck wound. With the development of non-invasive preoperative localization techniques and intraoperative parathyroid hormone assay, minimally invasive surgery with limited unilateral neck exploration has been recommended for the treatment of primary hyperparathyroidism. This approach can be performed as an outpatient procedure under local anesthesia with shorter operating and recovery time and excellent cosmetic result.[4,5] The success of minimally invasive parathyroid surgery depends on accurate preoperative localization of diseased parathyroid glands. Several imaging procedures have been introduced for preoperative localization such as the US, CT scan, radionuclide imaging, and magnetic resonance imaging (MRI) or combination of these techniques.[6,7] Neck US is a rapid, cheap, safe, and non-invasive imaging modality with a range of benefits in evaluating neck masses. It is regarded as the first line of investigation of primary hyperparathyroidism in many centers with a reported sensitivity of 65-85%.[10-13] Neck US however, can demonstrate the presence of a nodule in the thyroid parathyroid region but not reliably differentiate between the cells of origin. The low (39%) sensitivity value of the single use of US for localization of parathyroid adenomas in our study can be explained by the high prevalence of nodular thyroid disease in Jordan, small parathyroid glands and short neck people commonly seen in Jordan either due to obesity or just part of normal variation.[14,15] Neck CT has an excellent ability to detect abnormal parathyroid adenomas with a reported sensitivity ranges from 46-87%.[16,17] It is also an excellent tool in detecting ectopic parathyroid adenoma, especially those in the mediastinum. The accuracy of the CT scan is largely dependent on the size of the adenoma and occasionally lymph nodes or tortuous vessels may be mistaken for adenomas.[18] We herein report that the combination of CT and US did not add much information over using neck CT alone in the localization of parathyroid adenomas in a cohort of 41 patients with hyperparathyroidism. The combined use of CT and US was effective in revealing 12 cases, yielding 86% sensitivity. The single use of CT or CT combined with US provided almost comparable sensitivities (78%, 86%), compared to 39% sensitivity for the single use of US. The average weight of missed parathyroid adenoma in this study was 990 mg. Of 16 parathyroid adenomas removed from 13 patients and missed by the US, CT scan or both, 7 (43%) were smaller than 500 mg in weight. Thus, the weight is a major factor in the ability of preoperative techniques in accurately localizing parathyroid adenomas. In the 5 cases missed by the CT scan, the parathyroid adenomas were strongly enhancing and mistaken for vascular structures, in 4 cases the adenoma was closely attached to the thyroid and interpreted as thyroid nodule, and in one case the parathyroid adenoma was interpreted as a lymph node. This study has several limitations,

**Figure 3-** A contrast-enhanced CT scan shows a large parathyroid adenoma in the thyroid position right side which was interpreted as a thyroid nodule. (arrow)

**Table 3 -** Accuracy of computed tomography (CT), ultrasound (US), or combination of both techniques in the localization of diseased parathyroid glands.

| Preoperative localization | No. of patients | No. of patients with true-positive results | No. of patients with false-negative results | No. of patients with false-negative results | Sensitivity (%) | Positive predictive value (%) |
|---|---|---|---|---|---|---|
| CT evaluation | 32 | 25 | 7 | 2 | (78) | (92.5) |
| US evaluation | 23 | 9 | 14 | 5 | (39) | (64.0) |
| Combined CT & US | 14 | 12 | 2 | 0 | (86) | (100) |

mainly the retrospective design and the small number of patients among each group. Patients with parathyroid hyperplasia and multinodular goiter pose another diagnostic problem, therefore further testing of the accuracy of these techniques in a prospective study with a large group of patients is required.

In conclusion, this study have shown that neck CT scan alone in our center was superior to the US in detecting diseased parathyroid adenomas and it was almost comparable to the combination of the 2 tests. However the combination of CT and US in the diagnosis of diseased parathyroid has 100% positive predictive value and therefore has the best diagnostic accuracy.

**Acknowledgment.** *This work was supported in part by the Faculty of Medicine, Jordan University, Jordan, their support is gratefully acknowledged.*

## References

1. Clark OH, Wilkes W, Siperstein AE, Duh QY. Diagnosis and management of asymptomatic hyperparathyroidism: safety, efficacy, and deficiencies in our knowledge. ***J Bone Miner Res*** 1991; 6 Suppl 2: S135-S142.
2. Bilezikian JP, Potts JT Jr, Fuleihan Gel-H, Kleerekoper M, Neer R, Peacock M, et al. Summary statement from a workshop on asymptomatic primary hyperparathyroidism: a perspective for the 21st century. ***J Clin Endocrinol Metab*** 2002; 87: 5353-5361.
3. Delbridge LW, Younes NA, Guinea AI, ReeveTS, Clifton-Bligh P, Robinson BG. Surgery for primary hyperparathyroidism 1962-1996: indications and outcomes. ***Med J Aust*** 1998; 168:153-156.
4. Stalberg P, Delbridge L, van Heerden J, Barraclough B. Minimally invasive parathyroidectomy and thyroidectomy-current concepts. ***Surgeon*** 2007; 5: 301-308.
5. Beyer TD, Solorzano CC, Starr F, Nilubol N, Prinz RA. Parathyroidectomy outcomes according to operative approach. ***Am J Surg*** 2007; 193: 368-372.
6. Scheible W, Deutsch AL, Leopold GR. Parathyroid adenoma: accuracy of preoperative localization by high resolution real time sonography. ***J Clin Ultrasound*** 1981; 9: 325-330.
7. Krubsack AJ, Wilson SD, Lawson TL, Collier BD, Hellman RS, Isitman AT. Prospective comparison of radionuclide, computed tomographic, and sonographic localization of parathyroid tumors. ***World J Surg*** 1986; 10: 579-585.
8. van Heerden JA, Grant CS. Surgical treatment of primary hyperparathyroidism: an institutional perspective. ***World J Surg*** 1991; 15: 688-692.
9. Sosa JA, Powe NR, Levine MA, Udelsman R, Zeiger MA. Profile of a clinical practice: Thresholds for surgery and surgical outcomes for patients with primary hyperparathyroidism: a national survey of endocrine surgeons. ***J Clin Endocrinol Metab*** 1998; 83: 2658-2665.
10. Gooding GA. Sonography of the thyroid and parathyroid. ***Radiol Clin North Am*** 1993; 31: 967-989.
11. Reading CC, Charboneau JW, James EM, Karsell PR, Purnell DC, Grant CS, et al. High-resolution parathyroid sonography. ***AJR Am J Roentgenol*** 1982; 139: 539-546.
12. Stark DD, Gooding GA, Moss AA, Clark OH, Ovenfors CO. Parathyroid imaging: comparison of high-resolution CT and high-resolution sonography. ***AJR Am J Roentgenol*** 1983; 141: 633-638.
13. Mazzeo S, Caramella D, Lencioni R, Molea N, De Liperi A, Marcocci C, et al. Comparison among sonography, double-tracer subtraction scintigraphy, and double-phase scintigraphy in the detection of parathyroid lesions. ***AJR Am J Roentgenol*** 1996; 166: 1465-14670.
14. Kharabsheh S, Belbesi A, Qarqash W, Azizi F. Goiter prevalence and urinary iodine excretion in schoolchildren of Jordan. ***Int J Vitam Nutr Res*** 2004; 74: 301-304.
15. Ajlouni K, Jaddou H, Batieha A. Obesity in Jordan. ***Int J Obes Relat Metab Disord*** 1998; 22: 624-628.
16. Tziakouri C, Eracleous E, Skannavis S, Pierides A, Symeonides P, Gourtsoyiannis N. Value of ultrasonography, CT and MR imaging in the diagnosis of primary hyperparathyroidism. ***Acta Radiol*** 1996; 37: 720-726
17. Gross ND, Weissman JL, Veenker E, Cohen JI. The diagnostic utility of computed tomography for preoperative localization in surgery for hyperparathyroidism. ***Laryngoscope*** 2004; 114: 227-231.
18. Ahuja AT, Wong KT, Ching AS, Fung MK, Lau JY, Yuen EH, et al. Imaging for primary hyperparathyroidism--what beginners should know. ***Clin Radiol*** 2004; 59: 967-976.