

Congenital plexiform schwannoma of the clitoris

Rooh A. Yegane, MD, Mohammadreza S. Alaei, MD, Elham Khanicheh, MD.

ABSTRACT

الأورام الشفانية عبارة عن بطء نمو الخلايا الصفائحية الجديدة للأعصاب، والتي تعتبر نادرة الوجود في الجهاز التناسلي للأنثى. وهنا نستعرض حالة مريضة تعاني من ورم الشفانوما (الورم الشفاني) متعدد الضفائر في البظر. وحسب معلوماتنا تعتبر هذه أول حالة تعاني من هذا النوع من الورم يتم الإبلاغ عنها في الأدبيات. تم إحضار طفلة تبلغ من العمر ستة أعوام إلى المستشفى لدينا وهي تعاني من وجود كتلة غير كيسية في البظر منذ ولادتها والتي قد نمت بشكل مطرد خلال السنوات السابقة. تم تحديد موعد للمريضة لإجراء العملية الجراحية. أظهرت فحوصات الأنسجة بعد العملية الجراحية وجود ورم الشفانوما (الورم الشفاني) متعدد الضفائر في البظر. لذلك، يجب الأخذ بعين الاعتبار الورم الشفانوما (الورم الشفاني) في التشخيص التفريقي للكتل البظرية.

Schwannomas are slow-growing nerve sheet neoplasms which are rarely found in the female genital system. In this article, we present a patient with Antony A congenital plexiform schwannoma of the clitoris. A 6-year-old girl was brought to our hospital with the history of a firm non-cystic clitoral mass from birth, which had been growing more rapidly during the previous year. The patient was scheduled for surgery. Histological studies revealed plexiform schwannoma of the clitoris post-operatively. Therefore, schwannoma should be considered in the differential diagnosis of clitoral masses.

Saudi Med J 2008; Vol. 29 (4): 600-602

From the Departments of General Surgery (Yegane, Khanicheh), and Pediatrics (Alaei), Loqman-Hakim Hospital, Shahid Beheshti University of Medical Sciences, Tehran, Iran.

Received 3rd October 2007. Accepted 27th January 2008.

Address correspondence and reprint request to: Dr. Elham Khanicheh, Department of Surgery, Loqman-Hakim Medical Center, Kamali St., Tehran, Iran. Tel. +98 (21) 44071656. E-mail: e_khanicheh@yahoo.com

Clitoral enlargement is frequently congenital. The differential diagnosis of this malformation can be classified into 4 groups such as: hormonal conditions, non-hormonal conditions, pseudo clitoromegaly,

and idiopathic clitoromegaly.¹ Schwannomas are nerve sheet tumors characterized by proliferation of Schwann cells of the peripheral nervous system. They are generally encountered in young, and middle-aged adults at the flexor surface of the extremities, neck, and mediastinum.² These slow-growing neoplasms are rarely found in the female genital system. They are mostly seen in neurofibromatosis patients. There have been only 4 reported cases without a history of neurofibromatosis, which presented after childhood.²⁻⁵ None of them were congenital. Here, we describe a patient with Antony A congenital plexiform Schwannoma of the clitoris. The purpose of the present study was to consider schwannoma as a possible differential diagnosis of clitoral masses regardless of age and past medical history of the neurofibromatosis type 1.

Case Report. A 6-year-old Afghan girl was brought to our hospital with the history of a clitoral mass since birth. The child was born at home by normal vaginal delivery. At first, her mother noticed the mass. She did not bring her for medical examination from neonatal period until admission to our ward due to parental belief, and absence of any growth within the first 5 years of her life. Her mother described that it has been growing more rapidly over the last year. In our interview, there was no family history of hereditary diseases. There was no fetal exposure to male hormones, such as, Danazol, and no history of any genital trauma. Physical examination revealed a 4.5 x 2.5 cm non-cystic firm pedunculated mass on the tip of the clitoris without any excess androgenic findings **Figure 1**. There was no associated pain, bleeding or urinary dysfunction. Pelvic ultrasonography showed normal infantile uterus and ovaries. Heteroecogenous mass in the clitoris area was seen. Cytogenetic studies of the buccal mucosa revealed a 46 XX female chromosome karyotype. All other laboratory results were normal. The pedunculated clitoral mass had not been extended to the deeper parts of the anatomic structure. Under general anesthesia mass excision, and clitoroplasty with preservation of the neurovascular pedicles by the Papageorgiou et al⁶

technique was carried out. During the operation, the corpora, and anatomical structure were preserved. Thus, sensation, and cosmetic appearance were preserved. On pathologic study, the resected specimen was a white, multinodular, encapsulated solid lesion. Microscopically, it was formed by packed, elongated cells arranged in areas of high cellularity with little stromal matrix (Antony A). Nuclear free zones lay between the regions of nuclear palisading (Verocay bodies) along with regions with a less densely cellularity termed Antony B (Figure 2). The pathological findings were consistent with clitoral plexiform schwannoma. During one year regular follow up after operation the patient did not have any sign of recurrence. Somatosensory of external genitalia was intact.



Figure 1 - Clitoral mass before surgical resection.

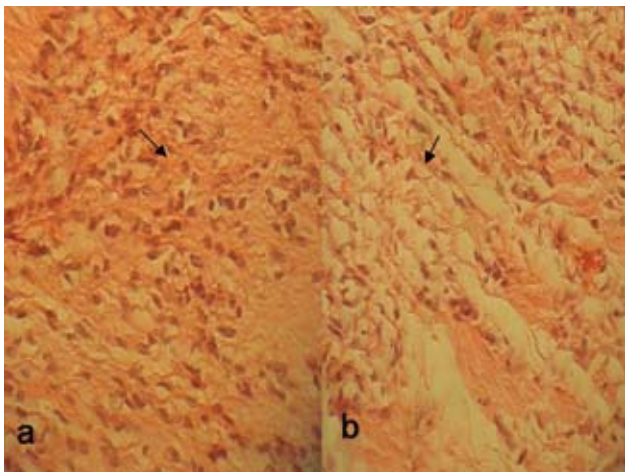


Figure 2 - Microscopic appearance of plexiform schwannoma. a) Antony A areas with high cellularity b) Antony B areas with less cellularity.

(Innervation density tests namely, Semmes-Weinstein and Threshold). After one year the patient returned to her country and we have no further follow up.

Discussion. The patient was referred to our center with a non-cystic firm pedunculated clitoral mass without any accompanying excess androgenic findings. It was similar to the presenting features of clitoral mass in previous studies.²⁻⁵ The congenital clitoral mass in our patient started to grow in size after the age of 5. In pediatric patients, such a mass is mostly referred to ambiguous genitalia, or teratoma despite the clitoral mass in adult-age group, which is associated with tumors of peripheral nervous system, and other soft tissue tumors.²⁻⁴ Ambiguous genitalia was ruled out by buccal smear, and biochemical blood studies. Due to the nonspecific, and indefinite clinical characteristics of clitoral masses, they pose diagnostic problems to the physician preoperatively, and the clitoral mass in our case was misdiagnosed before the operation. In our patient, ultrasonography was performed, and a hypoheterogeneous mass was found in the clitoris. Imaging studies such as ultrasonography or computed tomography (CT) would be applicable in non-aggressive diagnostic modalities to specify the cystic or solid characteristics of the mass, its extension to the adjacent tissue, and probable presence of testis in congenital enlarged clitoris, though only histology of either biopsy or excised specimen would be suggestive of definite diagnosis. In our study, CT-scan or MRI was not performed due to our data from the physical examination, and results from ultrasonography. Physical examination revealed a pedunculated mass in the tip of the clitoris, which had spared the base of the clitoris. There was no other pathologic feature reported in the ultrasonography of abdomen and pelvic. Owing to absence of the findings regarding the aggressive behavior of the mass, results from physical examination, and ultrasonography, biopsy was not carried out preoperatively.

In congenital tumors of the clitoris, due to possible malignancy or local recurrence, wide local resection is the treatment of choice.⁷ We performed simple excision of the tumor, preserving corpora, and anatomical structure. The previously reported patients with clitoral schwannoma underwent either simple excision of the tumor^{1,3,4} or amputation of the clitoris.⁵ During pathological evaluation, a schwannoma must be differentiated from a neurofibroma.^{2,8} In our patient, histological study of the excised specimen revealed a benign plexiform schwannoma with domination of Antony A morphologic characteristics, and high cellular differentiation with the absence of tumor necrosis, hemorrhage or atypical mitosis. Mostly, benign schwannoma presents as solitary

lesions. Multiple lesions may be seen in association with neurofibromas in von Recklinghausen's disease, or as the syndrome of schwannomatosis (neurilemmomatosis). Malignant transformation of a benign schwannoma is extremely rare, as opposed to the transformation of a neurofibroma in neurofibromatosis. Although our patient demonstrated benign plexiform schwannoma in a solitary attitude a careful search for Von Recklinghausen's disease should be a part of the evaluation as based on literature reports.⁹

We add this case to the other previously reported plexiform schwannoma of the clitoris.² Our patient is distinctive due to the congenital characteristics of the tumor. Apart from the particular characteristics of this case, most aspects are similar to previous reported cases of clitoral schwannoma. Although schwannoma of the clitoris is a rare finding, we still suggest it be regarded in the differential diagnosis of any clitoral mass, specifically in children.

References

1. Copcu E, Aktas A, Sivrioglu N, Copcu O, Oztan Y. Idiopathic isolated clitoromegaly: A report of two cases. *Reprod Health* 2004; 1: 4.
2. Chuang WY, Yeh CJ, Jung SM, Hsueh S. Plexiform schwannoma of the clitoris. *APMIS* 2007; 115: 889-890.
3. Huang H, Yamabe T, Tagawa H. A solitary neurilemmoma of the clitoris. *Gynecol Oncol* 1983; 15: 103-110.
4. Llanaez P, Fresno F, Ferrer J. Schwannoma of the clitoris. *Acta Obstet Gynecol Scand* 2002; 81: 471-472.
5. Cheng WC. Nerve tumour of the clitoris. Report of a case and commentary. *J Obstet Gynaecol Br Commonw* 1966; 73: 1016-1017.
6. Papageorgiou T, Hearn-Strokes R, Peppas D, Segars JH. Clitoroplasty with preservation of neurovascular pedicles.
7. Levard G, Podevin J, Levillain P, Podevin G. Congenital neoplasm of the clitoris. *J Urol* 1997; 157: 649.
8. Yuksel H, Odabasi AR, Kafkas S, Onur E, Turgut M. Clitoromegaly in type 2 neurofibromatosis: a case report and review of the literature. *Eur J Gynaecol Oncol* 2003; 24: 447-451.
9. Sordillo PP, Helson L, Hajdu SI, Magill GB, Kosloff C, Golbey RB, et al. Malignant schwannoma - clinical characteristics, survival, and response to therapy. *Cancer* 1981; 47: 2503-2509.

Case Reports

Case reports will only be considered for unusual topics that add something new to the literature. All Case Reports should include at least one figure. Written informed consent for publication must accompany any photograph in which the subject can be identified. Figures should be submitted with a 300 dpi resolution when submitting electronically or printed on high-contrast glossy paper when submitting print copies. The abstract should be unstructured, and the introductory section should always include the objective and reason why the author is presenting this particular case. References should be up to date, preferably not exceeding 15.