Pigmented villonodular synovitis managed by Yttrium 90 after debulking surgery

Hayati Ozturk, MD, Okay Bulut, MD, Zekeriya Oztemur MD, Sema Bulut, MD.

ABSTRACT

الهدف من هذه الدراسة هو تقييم النتيجة بالنسبة للمرضى اللذين يعانون من التهاب الزلال الزغابي العقدي المصبوغ (PVNS)، والذي تم علاجه بعقار ايتريوم-90 (^{90}Y) بعد عملية التفتيت. أجريت دراسة بشكل استرجاعي على سبع مرضى (3 رجال – 4 نساء) يعانون من التهاب الزلال الزغابي المصبوغ (PVNS). وقد كان متوسط فترة المتابعة 47.8 شهرا (المدى 24-97 شهراً). كان متوسط العمر 44.8 (المدى 20-68 عاما). تم إجراء عمليات التفتيت باستئصال السائل الزلالي من المفاصل بالمنظار لأربع حالات، وباستعمال فغر المفاصل الصغير لثلاث حالات. أعطية حقنة من عقار ايتريوم-90 (^{90}Y). وقد شمل الفحص االرنين المغناطيسي (MRI)، وقياس سماكة السائل الزلالي قبل العملية وفي آخر مقارنة. كانت نتيجة مؤشر متوسط المدى MTS 26 المدى (23-29)، ونتيجة مؤشر معدل المدى (70.4%) MTS (المدى 38.5-86.2%). كان متوسط سماكة السائل الزلالي السابق للعملية 14.9mm (المدى 20-12mm). اختفت سماكة السائل الزلالي بالكامل في آخر تصوير بالرنين المغناطيسي (MRI). وُجِدَ هناك صبيب منتشر في المفاصل بعد العملية ونقص في آخر مقارنة. لم يكن هناك أي معاودة لالتهاب السائل الزلالي الزغابي العقدي (PVNS) لدى أي من المرضى. على الرغم من قلة عدد الحالات، إلا أننا نعتقد أن الجمع بين جراحة التفتيت والحقن بعقار ايتريوم-90 (^{90}Y) لعلاج التهاب السائل الزلالي الزغابي العقدي في مفاصل الركبتين طريقة علاجية فعالة وآمنة.

The goal of this study was to evaluate outcome of patients with pigmented villonodular synovitis (PVNS) managed by Yttrium90 (^{90}Y) after debulking surgery. Seven patients (3 males and 4 females) with PVNS were studied retrospectively. Mean follow-up was 47.8 months (range 24-97months). Mean age was 44.8 years (range 20-68 years). Debulking surgeries via arthroscopic synovectomy were performed in 4 cases and in 3 cases via mini arthrotomy. After ^{90}Y injection was applied. Magnetic resonance imaging (MRI) included measurement of synovial thickness in preoperative and at last control. Main musculoskeletal tumor society score was 26 (range, 23-29), main MTS rating was 70.4% (range, 38.5-86.2%). Mean preoperative synovial thickness was 14.9mm (range 20-12mm). Synovial thickness was completely disappeared at last MRI examination. There was diffuse joint effusion preoperatively, decreasing at last control. No cases of PVNS recurrence were found. Although we had a small number of cases, we believe that combination of debulking surgery with intra-articular injection of ^{90}Y for PVNS of knee joint is an effective and safe treatment method.

Saudi Med J 2008; Vol. 29 (8): 1197-1200

From the Departments of Orthopedics and Traumatology (Ozturk, Bulut O, Oztemur), and Radiology (Bulut S), Faculty of Medicine, Cumhuriyet University School of Medicine, Sivas, Turkey.

Received 22nd February 2008. Accepted 17th June 2008.

Address correspondence and reprint request to: Dr. Hayati Ozturk, Department of Orthopedics and Traumatology, School of Medicine, Cumhuriyet University, Sivas 58140, Turkey. Tel. +346 2580635. Fax. +346 2191284. E-mail: hozturk@cumhuriyet.edu.tr

Pigmented villonodular synovitis is a benign proliferative histiocytic disorder of the synovium. It was first described in 1852 with its recidivist character, and destructive effects which may be required repeated surgical interventions and even amputation for severe cases.[1] Pigmented villonodular synovitis affects people in their third or fourth decade of life. In most cases, the disease is monoarticular and involves mainly the knee joint, the hip, and ankle joints follow in frequency. The lesion is rarely polyarticular. It has the potential to invade extensively local structures such as muscles, tendons, bones, and skin.[2,3] Although its exact cause remains unknown presence of macrophage and related proinflamatory cytokines such as tumor necrosis factor-α (TNF-α) has been described in PVNS.[4] The optimal treatment of PVNS is not known. Marginal excision for the localized disease and total or subtotal synovectomy for diffuse PVNS has been recommended.[5] External beam radiation, and intra-articular injection of ^{90}Y have been tried and shown to be effective in reducing the rate of local recurrence.[1]

The goal of this study was to evaluate outcome of patients with PVNS managed by ^{90}Y after debulking surgery.

Case Report. Three male and 4 female patients with PVNS treated by intra articular injection of Y^{90} after debulking surgery at our clinic between January 2000 and January 2006, were studied retrospectively. Mean follow-up was 47.8 months (range 24-96 months). Mean age of the patients of beginning of the surgical therapy was 44.8 years (range 20-68 years). The diagnosis was confirmed with arthroscopic biopsy in all cases. All cases had knee joint involvement. They had a history of knee pain, swelling and loss of range of motion. Non-operative treatment such as nonsteroidal anti-inflammatory drug aspiration of the knee and physical therapy failed in all patients. Five patients had Ahlbäck[1] grade II, one patient had Ahlbäck Grade I, and one patient had Ahlbäck grade III osteoarthrosis. All patients had diffused PVNS. Debulking surgery via anterior arthroscopic (patellofemoral, medial, lateral) compartment synovectomy was performed with shaver in 3 cases, but in these 3 cases posterior compartment synovectomy could not be managed. Debulking surgery was performed with open mini arthrotomy in 4 patients (**Table 1**). Intraarticular injection was applied 6 weeks after debulking surgery. The procedure was performed in the operating room. Under aseptic conditions, a needle was inserted into knee joint, and 5 mCi ^{90}Y (Amersham, UK) was injected. One ml of methylprednisolone acetate (Depomedrol 40 mg/1 ml flacon, Pharmacia & Upjohn Company, Kalamazoo, USA), and 5 ml of saline solution was injected with the same needle after ^{90}Y injection. After intraarticular ^{90}Y, a long cast splint was applied. Scintigraphic examination was used after 24 hours of procedure to investigate systemic leakage of ^{90}Y. The patients were followed with physical examination and plain radiographic evaluation monthly during follow-up. Magnetic resonance imaging examination was performed preoperative and at last control. Functional evaluation according to Musculoskeletal Tumor Society (MTS)[7] was performed.

Magnetic resonance imaging examination. For all examinations, a 1.5-T MR imaging system (MRI was performed using one of 3, 1.5-T imaging systems (Exelart, Toshiba Medical Systems; Gyroscan Intera, Philips Medical Systems, Otawara, Japan) was used. Using fat-suppressed T2-weighted sagittal imaging, the synovial thickness was measured from areas of the suprapatellar pouch time. Images were obtained both preoperatively and postopertaively at last control after the treatment of PVNS of the knee.

Results. Systemic leakage was not observed during the procedure in any of the patients. There was no postoperative or postinjection infection, or wound problem such as radiation necrosis. Deep vein thrombosis was occurred only in one patient but healed without any complication. Main MTS score was 26 (range, 23-29), main MTS rating was 70.38 % (range, 38.46%-86.2%). We noticed that there is no difference in terms of postoperative functionality among patients undergoing arthroscopic treatment versus mini-arthrotomy. Mean preoperative synovial thickness was 14.85 mm (range 20-12 mm). Synovial thickness was completely disappeared at postoperative last control. Besides, diffuse joint effusion existed preoperatively was decreased at postoperative last control (**Figures 1a & 1b**).

Discussion. Combination of debulking surgery with intra-articular injection of ^{90}Y for PVNS in knee joint is an effective and safe treatment method. Pigmented villonodular synovitis in knee is most frequent in the third and fourth decades. The gender distribution is not known, but a slight female preponderance was found in large series.[8,9] The optimal treatment for the PVNS is

Table 1 - Details of 7 patients (type of PVNS, follow-up period, MTSII score, MTSII rating and complications)

Case No	Gender	Age	Type	Follow up (month)	Ahlbäck	Debulking surgery procedure	MTS total score	MTS rating (%)	Complication
1	F	20	Diffuse	34	1	Open surgical synovectomy	23	65.21	Deep vein thrombosis
2	M	75	Diffuse	47	3	Open surgical synovectomy	29	86.20	-
3	F	44	Diffuse	24	2	Anterior artroscopic synovectomy	29	86.20	-
4	F	49	Diffuse	31	2	Open synovectomy	26	38.46	-
5	F	46	Diffuse	34	2	Anterior artroscpic synovectomy	29	86.20	-
6	M	50	Diffuse	68	2	Anterior artroscopic synovectomy	23	65.21	-
7	F	37	Diffuse	97	2	Open surgical synovectomy	23	65.21	-

F - female, M - male, PVNS - pigmented villonodular synovitis MTS - Musculoskeletal Tumor Society

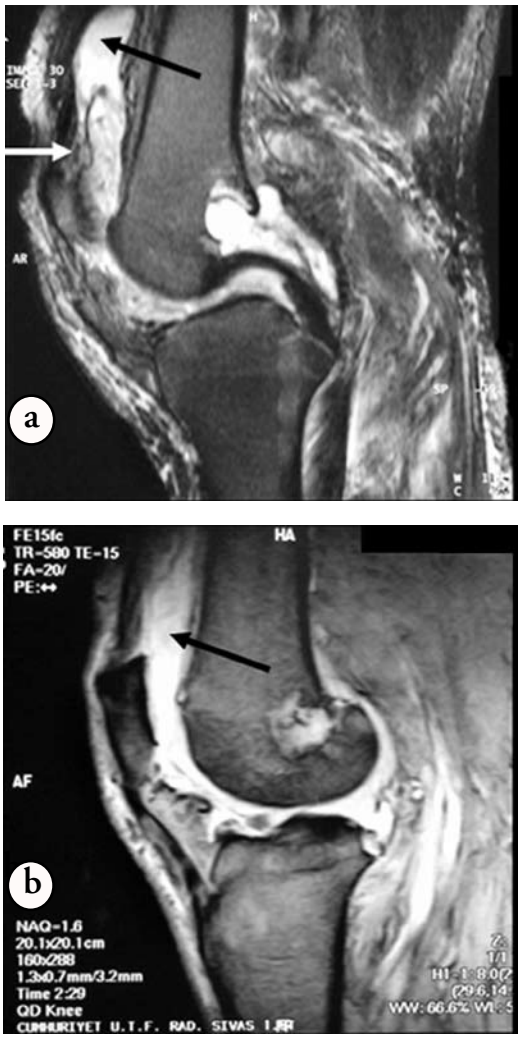

Figure 1 - Magnetic resonance images showing **a**) Preoperative, fat-suppressed T2-weighted sagittal image obtained before the intra-articular injection of Yttrium 90 after debulking surgery. Synovial thickness and diffuse joint effusion is seen in the suprapatellar region. **b**) Postoperative, 6 months after treatment shows completely disappeared synovial thickness and that joint effusion decreased significantly.

not known. Traditional effective treatment for PVNS is surgical synovectomy. It can be carried out arthroscopically or via arthrotomy. However, open surgical synovectomy causes stiffness, pain, and has a long recovery time. Arthroscopic synovectomy has reduced morbidity and is well tolerated by patients.[2] Zvijac et al[10] reported 17% rate of recurrence in diffuse forms of their PVNS series. Blanco et al,[1] reported that diffuse knee PVNS treated by arthroscopic synovectomy, and postoperative radiotherapy with 2,600 cGY. Shabat et al.[2] reported no recurrence in 6 patients with diffuse PVNS after debulking surgery after injection. Recurrence is more common in diffuse variants treated with intralesional primary treatment with incomplete synovectomy.[3] In 7 cases we have presented no evidence of local recurrence and no progressive bone and/or joint destruction was noted clinically and with MR imaging studies. Tumor necrosis factor-α (TNF-α) blockade with infliximab has been reported as an effective therapy for refractory PVNS. Larger clinical follow up is needed to determine the effects of infliximab at refractory PVNS. It may be useful for elective cases that showed immunohistology of synovial samples abundant presence TNF-α. Although TNF-α blockade with infliximab has been reported as an effective therapy, larger series with long term follow up results are needed to compare the available method of treatment.[4] Blanco at al.[1] reported that partial arthroscopic synovectomy combined with low-dose radiation therapy (RT) in anti-inflammatory doses produced good results in the treatment of PVNS without significant complications in their patient series. Partial arthroscopic synovectomy of the knee for PVNS may be combined with RT to reduce the risk of disease recurrence. De Visser[11] reported diffuse and localized PVNS evaluation of treatment of 38 patients. Three types of PVNS have been identified: localized nodules in 9 patients, diffuse PVNS of the entire synovial membrane in 26, a combination of a diffuse involvement of the synovial membrane, and an extra-articular presentation in 1, and extra-articular lesions in 2. The location of the lesions was knee (n = 31), hip (n = 3), ankle (n = 2), femoral triangle (n = 1), and gluteal region (n = 1). The procedures performed were surgery alone, surgery combined with radiosynovectomy and radiosynovectomy only. Functional evaluation was performed with MTS score. The mean functional evaluation score of 34 patients was 24 (range 15-30). Most of the ratings were excellent or good. In 6 cases fair, and in 2 cases poor. In our cases, functional evaluation was also performed with MSTS. Mean functional score evaluation of 7 patient was 26 (range 23-29). Dolphin12 calculated that if 5 mCi of ^{90}Y is distributed evenly throughout the body, the total body irradiation would be 13 rad, and the risk of cancer induction following such a dose would be 0.4 per 1000 patients treated. It is not clear that risk of malignancy and/or chromosomal mutation after ^{90}Y injection.

In conclusion, we believe that combination of debulking surgery with intraarticular injection of ^{90}Y for PVNS in knee joint is an effective and safe treatment method.

Acknowledgements. *The Authors thank Prof. Ali Cetin for assistance in the study.*

References

1. Blanco CE, Leon HO, Guthrie TB. Combined partial arthroscopic synovectomy and radiation therapy for diffuse pigmented villonodular synovitis of the knee. ***Arthroscopy*** 2001; 17: 527-531.

2. Shabat S, Kollender Y, Merimsky O, Isakov J, Flusser G, Nyska M, et al. The use of surgery and yttrium 90 in the management of extensive and diffuse pigmented villonodular synovitis of large joints. ***Rheumatology*** 2002; 41: 1113-1118.
3. Sharmaa H, Jane MJ, Reidc R. Pigmented villonodular synovitis: Diagnostic pitfalls and management strategy. ***Current Orthopaedics*** 2005; 19: 215-222.
4. Kroot EJ, Kraan MC, Smeets TJ, Maas M, Tak PP, Wouters JM. Tumour necrosis factor alpha blockade in treatment resistant pigmented villonodular synovitis. ***Ann Rheum Dis*** 2005; 64: 497-49.
5. Flandry FC, Hughston JC, Jacobson KE, Barrack RL, McCann SB, Kurtz DM. Surgical treatment of diffuse pigmented villonodular synovitis of the knee. ***Clin Orthop Relat Res*** 1994; 300: 183-192.
6. Ahlbäck S. Osteoarthrosis of the knee. A radiographic investigation. ***Acta Radiol Diagn*** 1968; S277: 7-72.
7. Enneking WF, Dunham W, Gebhardt MC, Malawar M, Pritchard DJ. A system for the functional evaluation of reconstructive procedures after surgical treatment of tumors of the musculoskeletal system. ***Clin Orthop Relat Res*** 1993; 286: 241-246.
8. Ray RA, Morton CC, Lipinski KK, Corson JM, Fletcher JA. Cytogenetic evidence of clonality in a case of pigmented villonodular synovitis. ***Cancer*** 1991; 67: 121-125.
9. Sharmaa H, Janeb MJ, R. Reidc. Pigmented villonodular synovitis: Diagnostic pitfalls and management strategy. ***Current Orthopaedics*** 2005; 215-222.
10. Zvijac JE, Lau AC, Hechtman KS, Uribe JW, Tjin-A-Tsoi EW. Arthroscopic treatment of pigmented villonodular synovitis of the knee. ***Arthroscopy*** 1999; 15: 613-617.
11. de Visser E, Veth RP, Pruszczynski M, Wobbes T, Van de Putte LB. Diffuse and localized pigmented villonodular synovitis: evaluation of treatment of 38 patients. ***Arch Orthop Trauma Surg*** 1999; 119: 401-404.
12. Dolphin GW. Biological hazards of radiation. ***Ann Rheum Dis*** 1973; 32: 23-28.

Authorship entitlement

Excerpts from the Uniform Requirements for Manuscripts Submitted to Biomedical Journals updated November 2003.
Available from www.icmje.org

The international Committee of Medical Journal Editors has recommended the following criteria for authorship; these criteria are still appropriate for those journals that distinguish authors from other contributors.

Authorship credit should be based on 1) substantial contributions to conception and design, or acquisition of data, or analysis and interpretation of data; 2) intellectual content; and 3) final approval of the version to be published. Authors should meet conditions 1, 2, and 3.

Acquisition of funding, collection of data, or general supervision of the research group, alone, does not justify authorship.

An author should be prepared to explain the order in which authors are listed.