

Penile necrosis due to calciphylaxis in a patient of end stage renal disease

Tanvir Rizvi, MD, DM, Nizar A. Al-Nakshabandi, MD, FRCPC.

ABSTRACT

نستعرض في هذا التقرير حالة رجل مريض يبلغ من العمر 72 عاماً، يعاني من مرض السكري والضغط الذي أدى إلى فشل كلوي نهائي (ESRD). وقد أدى ذلك إلى حدوث التكلس الذكري، ونذكر هنا حالة موات الحشفة القضيبيية في حالات التكلس الذكري، حيث يحدث تكلس في الشرايين الصغيرة والمتوسطة مما يؤدي إلى إحتشاء وموات. أظهرت الأشعة المقطعية (CT) للحوض وأعلى الفخذين تكلس لجدران الشرايين المتوسطة والصغيرة مع انغلاق كامل للشرايين الصغيرة. التركيب الثلاثي الأبعاد للقضيبي باستخدام تقنية الأبعاد الثلاثية (3D) أظهر تقرحات على الحشفة القضيبيية. أكدت الصور الإشعاعية الحالة بحيث لا يوجد حاجة لأخذ عينات نسيجية. كما تمت مناقشة حالات مشابهة لهذه الحالة تم ذكرها في الأدبيات.

A case of a 72-year-old diabetic, hypertensive male with end stage renal disease as a result of the underlying condition of calciphylaxis, presenting with gangrene of the glans penis is reported. In calciphylaxis, calcification of small and medium-sized arteries occurs, which may result in ischemia and gangrene. A computed tomography scan of the lower abdomen, pelvis, and the upper thigh was performed, which showed diffuse and extensive calcification of the walls of the small and medium-sized arteries, with almost complete obliteration of the lumen of the small arteries. A 3-dimensional reconstruction of the penis using volume rendering technique, demonstrated the ulceration of the glans penis in an exquisite manner. The appearance is so peculiar that no histological confirmation is needed. A review of relevant literature related to the etiopathogenesis, radiological findings, treatment, and prognosis is also discussed.

Saudi Med J 2009; Vol. 30 (1): 143-145

From the Department of Radiology (Rizvi), King Fahd Medical City, and the Department of Radiology (Al-Nakshabandi), King Khalid University Hospital College of Medicine, King Saud University, Riyadh, Kingdom of Saudi Arabia

Received 11th August 2008. Accepted 2nd December 2008.

Address correspondence and reprint request to: Dr. Tanvir Rizvi, Assistant Consultant, Department of Radiology, King Fahd Medical City, Riyadh, Kingdom of Saudi Arabia. Tel. +966 (1) 2889999 Ext. 1016. Fax. +966 (1) 2889999 Ext. 1019. E-mail: rizvi.tanvir@gmail.com

We report a case of gangrene of the glans penis caused by calciphylaxis in a 72-year-old diabetic, hypertensive man with end stage renal disease (ESRD) presenting to our institute. In this condition, calcification of small and medium-sized arteries occurs, which may result in ischemia, and gangrene. The purpose of presenting this case is that diabetes is a very common disease entity in our population, and this rare complication of penile necrosis carries a poor prognosis, and high mortality. Computed tomography (CT) with 3-dimensional (3D) reconstruction can provide us with an efficient method of documenting this entity, even in those cases where histopathological diagnosis is not feasible.

Case Report. A 72-year-old male patient of chronic renal failure on dialysis was admitted with ulceration of the glans penis, and associated excruciating pain. He was a known case of insulin dependent diabetes and was also hypertensive with poor control. He developed a painful necrotic lesion on the glans of his circumcised penis. Laboratory tests revealed serum calcium to be 1.84 mmol/L (normal range 2.22-2.49), serum phosphorus 2.36 mmol/L (normal range 0.81-1.58), and serum parathyroid hormone (PTH) 33.43 pmol/L (normal range 1.6-6.9). His plasma urea was 47.1 mmol/L (normal range 2.5-6.4), and plasma creatinine 674 μ mol/L (normal range 71-115). His white blood count (WBC) was raised at $17.5 \times 10^9/L$ (normal range 4-11) with neutrophils comprising 85.2% of the WBC. His hemoglobin was low, measuring 5.03 g/dL (normal range 13-18). Serum alkaline phosphatase was raised at 363 U/L (range 50-136). An x-ray of the pelvis revealed generalized reduction in bone density, mild osteoarthritic changes in both hip joints, and arterial wall calcifications in iliac, femoral, pudendal, and penile arteries. X-ray of the hands showed extensive arterial wall calcifications in both hands with generalized periarticular reduction of bone density. An ultrasound of both kidneys showed bilateral small, echogenic kidneys with ascites. A CT scan of the lower abdomen, pelvis, and upper thigh without intravenous contrast administration, was performed with 2.5 mm collimation, a pitch of 0.625, and a table

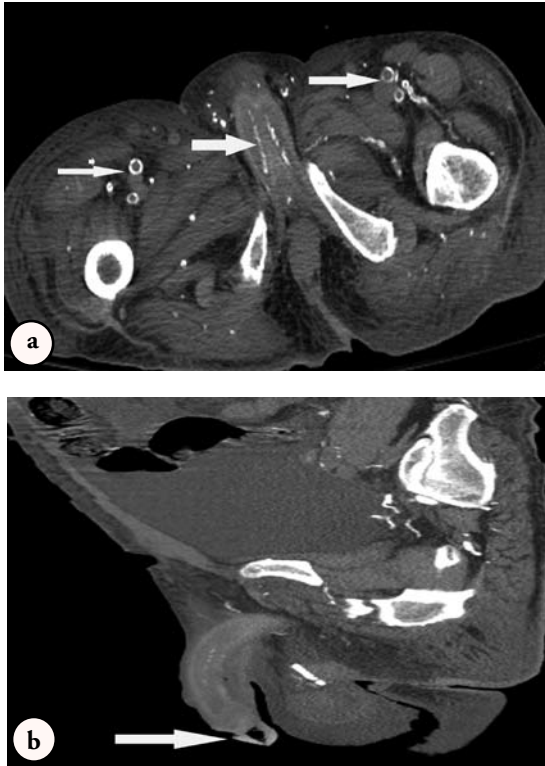

Figure 1 - Computed tomography scan of pelvis and upper thighs axial section a) and sagittal reconstruction b) shows diffuse and extensive calcification of the walls of small and medium-sized arteries including the iliac, femoral, pudendal, penile, dorsal penile and cavernosal arteries with almost complete obliteration of the lumen of small arteries. There is air in glans penis representing gangrenous changes on sagittal reconstruction.

speed of 12.5 on a 16 slice multidetector CT scanner (Milwaukee, WI, USA). Reconstruction in sagittal and coronal planes with 3D reconstruction for the penis region was also obtained. It showed diffuse and extensive calcification of the walls of the small and medium-sized arteries, with almost complete obliteration of the lumen of small arteries including the iliac, femoral, pudendal, penile, dorsal penile, and cavernosal arteries (**Figures 1a & 1b**). There was gangrenous involvement of the distal penis with soft tissue swelling, and air locules within the subcutaneous tissues. The 3D reconstruction of the penis using volume rendering technique, demonstrated the ulceration of glans penis in an exquisite manner (**Figure 2**). The patient was started on antibiotics, and the penile lesion was débrided, and dressed. The wound healed well over a period of 2 weeks, and the patient went home still having severe pain, partially responding to narcotic analgesics.

Discussion. In 1898 Bryant and White¹ reported features of the condition that was later described as calciphylaxis by Selye et al,² because of a pathophysiologic

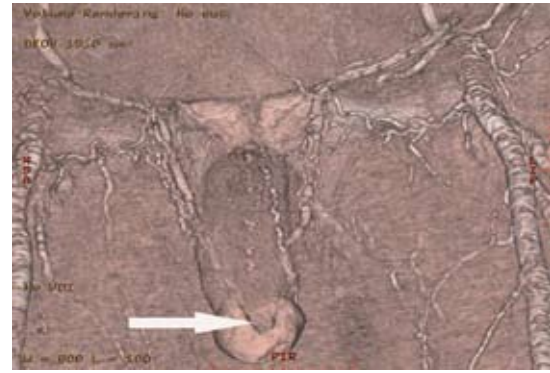


Figure 2 - Computed tomography 3 dimensional reconstruction of the penis using volume rendering technique demonstrated the ulceration of glans penis and arterial wall calcifications.

resemblance to anaphylaxis. Calciphylaxis (calcific uremic arteriopathy) is characterized histologically by small-vessel wall calcification and intimal hypertrophy, associated with small vessel thrombosis and panniculitis.³ It manifests clinically as bilateral painful violaceous plaques starting in the lower extremities, or as painful necrotizing skin lesions with ulcerations, which have a mortality of approximately 80%,^{4,5} usually from supervening infections.

The penis has an extensive collateral blood supply, which protects it from ischemic gangrene. Isolated penile gangrene is believed to be a focal manifestation of arterial calcification seen in chronic renal failure, which is aggravated by diabetes mellitus. It is an extremely rare condition with only 38 cases reported until April 2007,⁶ and only one case reported in the Saudi literature.⁷

Due to a lowered vitamin D in ESRD patients (the active metabolite of vitamin D is transformed in the kidney), there is decreased calcium absorption from the intestine. Low serum vitamin D, low serum calcium, and high serum phosphate lead to secondary hyperparathyroidism. Most patients with calciphylaxis have abnormalities of calcium-phosphate homeostasis with elevated levels of PTH, but these changes, as well as an elevation of the calcium-phosphorus product are not always present in this disease.⁷ In our case, serum phosphorus and PTH were raised, though no primary cause in parathyroid glands could be documented. It was a manifestation of abnormal calcium and phosphorus metabolism due to secondary hyperparathyroidism that occurs in renal failure patients, especially those on maintenance dialysis. Calciphylaxis has also been reported in the absence of hyperparathyroidism and other hypercalcemic states, namely, milk-alkali syndrome, rickets, infantile hypercalcemia, collagen disease, leukemia, lymphoma, and multiple myeloma.⁸ The marked anemia in our case was a result of inadequate

dialysis as his long standing, poorly controlled diabetes had resulted in renal impairment, which needed more frequent dialysis.

Vascular calcification is a well-known condition associated with ESRD. In a study of patients on long-term hemodialysis, the authors observed radiological evidence of vascular calcification in 39% of the patients at the start of dialysis, and found that this increased to 92%, and that severity progressed over 10 years.⁹ Another investigation revealed that 19% of male patients on maintenance hemodialysis show calcification of the penile artery on plain x-ray films.¹⁰ In our case, the diffuse and extensive calcification of the walls of small and medium-sized arteries with almost complete obliteration of the lumen of small arteries including the iliac, femoral, pudendal, penile, dorsal penile, and cavernosal arteries were demonstrated on plain x-rays, as well as on CT scan. The appearance is peculiar, hence, no histological confirmation is usually needed. Deposition of calcium salts in the media of the small arteries and arterioles in response to a challenging agent in a hypersensitive environment is responsible for the primary lesion. Subsequently, the intima thickens resulting in the narrowing of the lumen. Infarction of the subcutaneous tissue and skin occurs secondarily, and results in initial clinical manifestations of the syndrome. Before the skin ulcerates, the infarctions give a firm, lumpy, plaque like character to the subcutaneous tissue. Later, this progresses to painful violaceous lesions and hemorrhagic mottling of the skin, which further progresses to gangrene.¹¹

A trial of conservative treatment with meticulous wound care with, or without circumcision may be appropriate for some patients since resolution of the lesions, or autoamputation has been reported. The indications for surgical resection are pain or urinary obstruction, or both. Parathyroidectomy should be considered in patients with elevated serum PTH.¹² Different therapeutic options like parathyroidectomy, bisphosphonates, sodium thiosulfate, and cinacalcet have been used with varying success in calciphylaxis associated with hyperparathyroidism, and high bone turnover. Therapy consists of lowering serum phosphorus, calcium, and PTH levels. Local wound management including debridement and antibiotics may be necessary. In some cases, hyperbaric oxygen therapy helps heal wounds.¹² Calciphylaxis is associated with increased mortality. In

a study, calciphylaxis independently increased the risk of death by eightfold.¹³

In conclusion, this rare and interesting complication of penile gangrene in ESRD patients deserves attention due to its poor prognosis. Radiology, and in particular, CT can serve to arrive at this diagnosis, especially in cases where histopathological diagnosis is not possible. In future, other developments such as calcium scoring similar to that used in CT coronary angiography might be feasible to determine the disease load, and hence prognosis.

References

1. Bryant JH, White WH. A case of calcification of the arteries and obliterative endarteritis associated with hydronephrosis in a child aged six months. *Guys Hosp Rep* 1898; 55: 17-20.
2. Selye H, Grasso S, Dieudonne JM. On the role of adjuvants in calciphylaxis. *Rev Allergy* 1961; 15: 461-465.
3. Llach F. The evolving pattern of calciphylaxis: therapeutic considerations. *Nephrol Dial Transplant* 2001; 16: 448-451.
4. Budisavljevic MN, Cheek D, Ploth DW. Calciphylaxis in chronic renal failure. *J Am Soc Nephrol* 1996; 7: 978-982.
5. Fine A, Zacharias J. Calciphylaxis is usually non-ulcerating: risk factors, outcomes and therapy. *Kidney Int* 2002; 61: 2210-2217.
6. Soto-Miranda MA, Goné-Fernández A, Romero-y Huesca A. [Penile calciphylaxis: case report and literature review]. *Cir Cir* 2007; 75: 113-117. Spanish
7. Al-Ghamdi KM. Calciphylaxis in a 33-year-old man with end-stage renal disease. *Ann Saudi Med* 2005; 25: 415-418.
8. Karpman E, Das S, Kurzrock EA. Penile calciphylaxis: analysis of risk factors and mortality. *J Urol* 2003; 169: 2206-2209.
9. Goldsmith DJ, Covic A, Sambrook PA, Ackrill P. Vascular calcification in long-term haemodialysis patients in a single unit: a retrospective analysis. *Nephron* 1997; 77: 37-43.
10. Dalal S, Gandhi VC, Yu AW, Bhate DV, Said RA, Rahman MA, et al. Calcification in maintenance hemodialysis patients. *Urology* 1992; 40: 422-424.
11. Guvel S, Yacyoglu O, Kilinç F, Torun D, Kayaselçuk F, Ozkardes H. Penile necrosis in end-stage renal disease. *J Androl* 2004; 25: 25-29.
12. Russell R, Brookshire MA, Zekonis M, Moe SM. Distal calcific uremic arteriopathy in a hemodialysis patient responds to lowering of Ca x P product and aggressive wound care. *Clin Nephrol* 2002; 58: 238-243.
13. Mazhar AR, Johnson RJ, Gillen D, Stivelman JC, Ryan MJ, Davis CL, et al. Risk factors and mortality associated with calciphylaxis in end-stage renal disease. *Kidney Int* 2001; 60: 324-332.