

The protective effect of N^G-nitro-L-arginine methyl ester and insulin on nitric oxide inhibition and pathology in experimental diabetic rat liver

Hilmi Ozden, MD, Neslihan Tekin, Bio, Fabrettin Akyuz, PhD, Firdevs Gurer, PhD, Mehmet C. Ustuner, PhD, Fulya Kucuk, PhD, Gul Guven, MD, Faik Yaylak, MD.

ABSTRACT

الأهداف: تحديد الدور الوقائي لعقار N^G-Nitro-L-Arginine Methyl Ester (L-NAME) والأنسولين على الكبد في سترپتوزوتوسين (STZ) المحرض في الجرذان المصابة بالسكري.

الطريقة: أجريت هذه الدراسة بقسم الكيمياء الحيوية – كلية الطب – جامعة عثمان غازي – تركيا، خلال عام 2007م. تم تقسيم 40 جرذا ذكرا من نوع وسيتار ألبينو إلى خمس مجموعات. مجموعة الذين لم يتم علاجهم، مجموعة التحكم السكرية، المجموعة التي تلقت (STZ+insulin)، المجموعة التي تلقت (STZ+L-NAME)، والمجموعة التي تلقت (STZ+insulin+L-NAME). تم حقن عقار سترپتوزوتوسين داخل الجلد لثلاث مجموعات وشمل ذلك الأنسولين و (L-NAME) والعلاجات الأخرى للمجموعات كعوامل وقائية. تم تحديد جلوكوز الدم (السكر الأحادي) ومستويات أكسيد النتريك (NO). تم الحصول على عينات النسيج في نهاية الأسبوع الرابع. تم تقييم التواءات نسيج الكبد باستعمال صبغة هيماتوكسيلين وإيوسن.

النتائج: كان مستوى مصلى الجلوكوز أعلى بشكل ملحوظ في مجموعة السكري ($p=0.000$) ثم في المجموعة التي لم يتم علاجها. كان مستوى أكسيد النتريك (NO) منخفضا بشكل ملحوظ في المجموعة التي تلقت ($p=0.000$) (STZ+L-NAME) عن المجموعة التي لم يتم علاجها. تمت ملاحظة التراكم الفصيصية البؤرية الكاذبة، وزيادة في النخرة الليفية البابية، وتضيق القناة الصفراوية مع نخرة تخثرية في الخلايا الكبدية أكثر في مجموعة السكري من مجموعات عوامل الحماية، بالإضافة إلى أن الأنسولين و (L-NAME) يؤديان إلى تجديد الخلايا الكبدية ولوحظ ترشيح بسيط في الخلايا وحيدة النواة.

خاتمة: يثبط (L-NAME) مستوى أكسيد النتريك (NO) في المجموعة التي أعطيت (STZ+L-NAME). يقوم (L-NAME) إما لوحده أو مع الأنسولين بتلطيف تشوشات الكبد الشكلية بشكل ملحوظ لدى الجرذان المصابة بالسكري والمحرضة بعقار (STZ).

Objectives: To determine on protective role of N^G-nitro-L-arginine methyl ester (L-NAME), and insulin on the liver in streptozotocin (STZ) induced diabetic rats.

Methods: This study was performed in the Department of Biochemistry, Faculty of Medicine, Eskisehir Osmangazi University, Eskisehir, Turkey in 2007. Forty male Wistar albino rats were divided into 5 groups. These were untreated, diabetic control, STZ+insulin, STZ+L-NAME and STZ+insulin+L-NAME induced groups. The STZ was intraperitoneally injected into 3 groups, and includes insulin, L-NAME, and their joint administrations as protective agents. The blood glucose and nitric oxide (NO) levels were determined. The tissue samples were obtained at the end of the fourth week. The liver tissue distortions were evaluated using hematoxylin and eosin staining.

Results: The serum glucose level was significantly higher in diabetic control ($p=0.000$), than the untreated group. Nitric oxide level was significantly lower in STZ+L-NAME ($p=0.000$) than the untreated group. The focal pseudo lobular structures without vena centralis increased portal fibrillary necrosis, and bile duct stenosis with coagulation necrosis of the peripheral hepatocytes were more observed in diabetic group than the protective agent groups. In addition, insulin, and L-NAME lead to hepatocyte regeneration; and minimal mononuclear cell infiltration was noted.

Conclusion: N^G-nitro-L-arginine methyl ester inhibits NO level in STZ+L-NAME induced group. N^G-nitro-L-arginine methyl ester either alone, or with insulin combination significantly attenuates the liver morphological disarrangements in STZ induced diabetic rats.

Saudi Med J 2009; Vol. 30 (1): 30-34

From the Department of Anatomy (Ozden, Guven), Faculty of Medicine, Eskisehir Osmangazi University, Department of Biochemistry (Tekin, Akyuz), Department of Histology and Embryology (Gurer, Kucuk), Department of Medical Biology (Ustuner), and the Department of Surgery (Yaylak), Kutahya Dumlupinar University Treating and Research Hospital, Eskisehir, Turkey.

Received 16th September 2008. Accepted 9th December 2008.

Address correspondence and reprint request to: Dr. Mehmet C. Ustuner, Department of Medical Biology, Faculty of Medicine, Eskisehir Osmangazi University, Eskisehir, Turkey. Tel +90 (222) 2392979 Ext. 4594. E-mail: custuner@ogu.edu.tr

Type I diabetes (insulin dependent diabetes mellitus [IDDM]) results from auto-immune damage of the pancreatic-cells.¹ The experimental diabetic rats similar to IDDM were induced by an injection of streptozotocin (STZ).² Streptozotocin also causes picnotic, and lobular nuclei swelling in granular endoplasmic reticulum cisternae, and dilatations in intracellular areas between pancreatic B cells,³ and less enzyme activity of nitric oxide synthase (NOS) was formed as compared to untreated animal in isolated Langerhans islets from pancreas homogenate.² One of the important pathogenetic mechanisms of cell damage in experimental STZ-treated diabetic rats, is the cytokine-induced overproduction of nitric oxide (NO) by NOS, with subsequent increase of local oxidative stress in the pancreatic islets. Streptozotocin-induced experimental diabetes is associated with increased expression of pro-inflammatory cytokines, increased expression of the inducible NOS (iNOS) gene, following increased NO production. Nitric oxide is hypothesized to harmfully affect cell function by inducing apoptosis, and suppressing glucose-stimulated insulin release.⁴ Thus, other diabetic disorder is related with NOS in different tissues. The function of NO synthesized by NOS has been concerned with infections, and inflammation. In the hypertensive STZ-diabetic rats, a vitiated NOS system was remarked when treated with the NOS stimulant (L-arginine), and inhibitor (N^G-nitro-L-arginine methyl ester [L-NAME],² also STZ expose nephrotoxic, and hepatotoxic activity.⁵ The STZ-treated diabetic rat's liver exhibits dilatation of hepatic sinusoids, and Kupffer cell hyperplasia,⁶ and feathery degeneration, micro and macro cellular fatty changes, and inflammatory cells around portal tract.⁷ Therefore, L-NAME has been used extensively as an inhibitor of NO synthase in several experimental models.⁸ The aim of this study was to determine the protective effects of L-NAME and insulin in NO level, and morphological changes of liver in the STZ-treated diabetic rats.

Methods. N^G-nitro-L-arginine methyl ester (Cayman Chemical, Denver, Colorado, USA), and STZ (Sigma-Aldrich Co., S-0130, Germany) were supplied for investigation. The experiments were performed in a 3-month-old, 40 male Wistar albino rats (250-300 g). The animals were housed under natural light, with free access to food and water in the Department of Biochemistry, Faculty of Medicine, Eskisehir Osmangazi University, Eskisehir, Turkey in 2007. Animal care was in compliance with the guidelines of the Medical Faculty of Eskisehir Osmangazi University Research Council Criteria (Protocol number: 2006/423). The rats were randomized into 1-5 experimental groups. After the blood glucose levels were measured at the second week,

STZ-treated rats that had blood glucose level upper than 216 mg/dl were accepted as experimental group. The 5 groups were designated as follows: untreated, diabetic control, STZ + insulin, STZ + L-NAME, and STZ + insulin + L-NAME induced groups. The single dose STZ (65 mg/kg) was intraperitoneally administrated into the rats after it was dissolved in 0.1 ml sodium citrate.⁹ Insulin (8 IU/kg) was given via subcutaneous route,¹⁰ and L-NAME (5 mg/kg) is orally given.¹¹ Insulin, L-NAME, and their combination were administrated into the diabetic rats for 4 weeks. The rat liver tissues were removed under ether anesthesia in the fourth week of the study. One part of them were homogenized with phosphate buffer (pH=7.4), and centrifuged at 12000 x g. Lysate was stored in -80°C until nitrate measurement, because nitrate is an indicator of the NO production.¹² For NO, serum was deproteinized first, and then nitrate, the stable product of NO present in filtrate is reduced to nitrite, which is measured by diazotization of sulphanilamide, and coupling with naphthylethylene diamine as in Najwa and Nabil method.¹³ The other removed liver were fixed in formalin, and processed routinely for paraffin embedding followed by preparing liver slides in 4 µm thickness. Tissue sections were then mounted on poly-L-lysine-coated slides, and stained with hematoxylin and eosin (H&E) for routine histology.

The data were presented as mean±SEM and analyzed using SPSS for windows 15.0 and Sigmastat 3.1. If data passed the normality test, the significance of the differences between groups was determined by Tukey's test, after significant analysis of variance. P<0.05 was considered statistically significant.

Results. The serum glucose levels are shown in Table 1, and significantly higher in diabetic control ($p=0.000$) than the untreated group. The serum glucose levels was significantly lowered in the STZ + insulin ($p=0.002$), and STZ + insulin + L-NAME induced ($p=0.003$)

Table 1 - The serum glucose levels in the comparison of untreated group with other groups.

Groups	Blood glucose level (mg/dl)	P-value
Untreated	111 ± 6.04	-
Diabetic control	412 ± 20.922†	0.000
STZ+insulin	192 ± 15.215*	0.002
STZ+L-NAME	392 ± 17.009†	0.000
STZ+insulin+L-NAME	190 ± 3.525*	0.003

*p<0.01 in comparison with control, †p<0.001 in comparison with control, STZ - streptozotocin, L-NAME - N^G-nitro L-arginine methyl ester

Table 2 - The liver NO levels in the comparison of untreated group with other groups.

Groups	NO level (µmol/l)	P-value
Untreated	0.586 ± 0.006	-
Diabetic control	0.520 ± 0.004*	0.000
STZ+insulin	0.555 ± 0.005†	0.245
STZ+L-NAME	0.475 ± 0.006*	0.000
STZ+insulin+L-NAME	0.544 ± 0.008*	0.000

† $p > 0.05$ in comparison with control, * $p < 0.001$ in comparison with control, STZ - streptozotocin, L-NAME - N^G-nitro L-arginine methyl ester, NO - nitric oxide

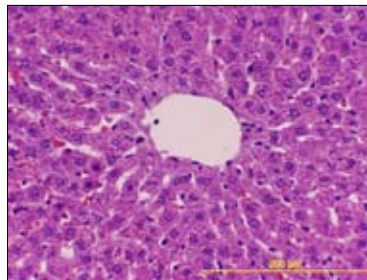


Figure 1 - Untreated group, normal liver morphology had found hematoxylin and eosin, original magnification x200.

compared to diabetic control. However, serum glucose levels were not significantly different between STZ + insulin, and STZ + insulin + L-NAME induced groups ($p=1.000$). Nitric oxide level was shown with multiple comparison according to treatment in Table 2, was significantly decreased in STZ + L-NAME ($p=0.000$), and STZ + insulin + L-NAME induced group ($p=0.000$) compared to that in the untreated group level, whereas, NO level was increased in only insulin-treated diabetic rats ($p=0.245$). This histopathological examination of the control group revealed normal liver morphology (Figure 1). In the diabetic control group, focal pseudo lobular structures without vena centralise, increased portal fibrillary necrosis, and bile duct stenosis with coagulation necrosis of the peripheral hepatocytes as shown in Figure 2. In STZ + insulin induced group, insulin treatment lead to be minimal portal mononuclear cell infiltration, minimal stasis in bile canalicules, and interlobular venules. The sparse regeneration fields of the hepatocytes, liquefaction focuses, dilated sinusoidal capillaries, and Kupffer cell proliferation were also noted (Figure 3). In the STZ + L-NAME treatment, near to

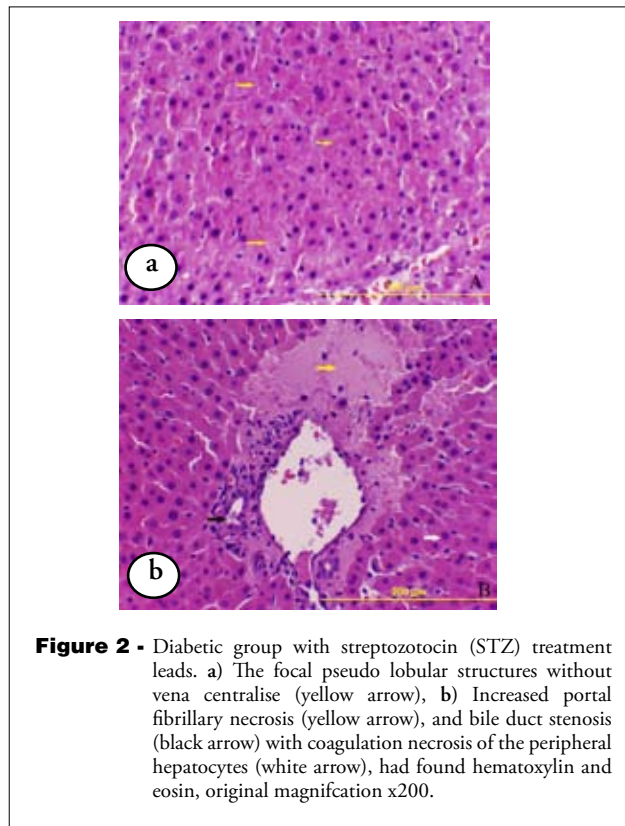


Figure 2 - Diabetic group with streptozotocin (STZ) treatment leads. a) The focal pseudo lobular structures without vena centralise (yellow arrow), b) Increased portal fibrillary necrosis (yellow arrow), and bile duct stenosis (black arrow) with coagulation necrosis of the peripheral hepatocytes (white arrow), had found hematoxylin and eosin, original magnification x200.

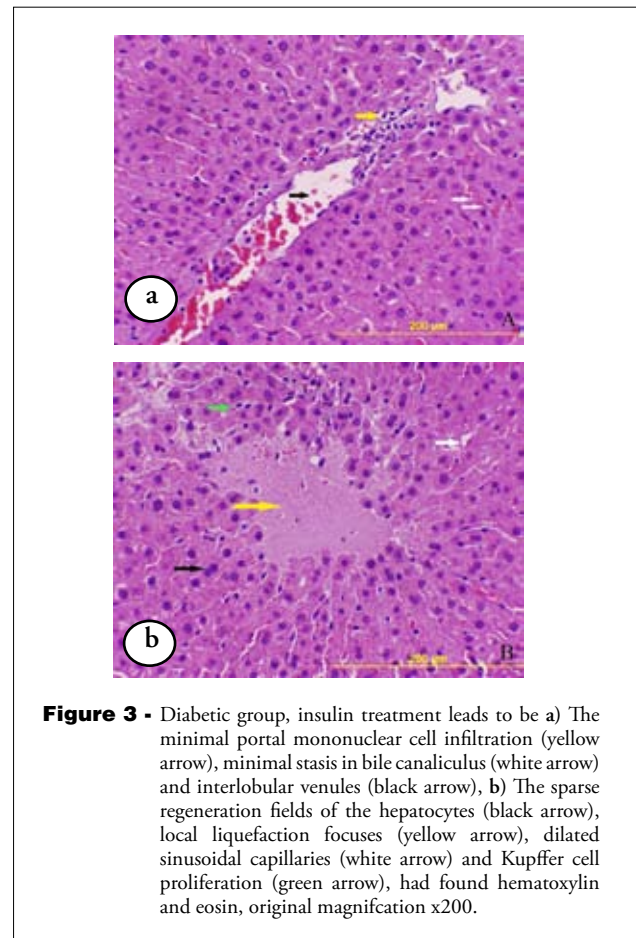


Figure 3 - Diabetic group, insulin treatment leads to be a) The minimal portal mononuclear cell infiltration (yellow arrow), minimal stasis in bile canaliculus (white arrow) and interlobular venules (black arrow), b) The sparse regeneration fields of the hepatocytes (black arrow), local liquefaction focuses (yellow arrow), dilated sinusoidal capillaries (white arrow) and Kupffer cell proliferation (green arrow), had found hematoxylin and eosin, original magnification x200.

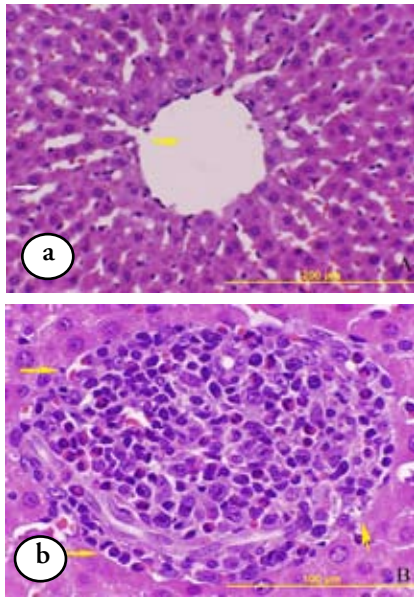


Figure 4 - Diabetic group, N^G-nitro-L-arginine methyl ester (L-NAME) treatment lead to a) normal vena centralise (yellow arrow) and sinusoidal structures (white arrow), b) The focal mononuclear cell infiltration and fibrillogenesis and polymorphonuclear cell infiltration area (yellow arrows), had found hematoxylin and eosin, original magnification x200 and 400 respectively.

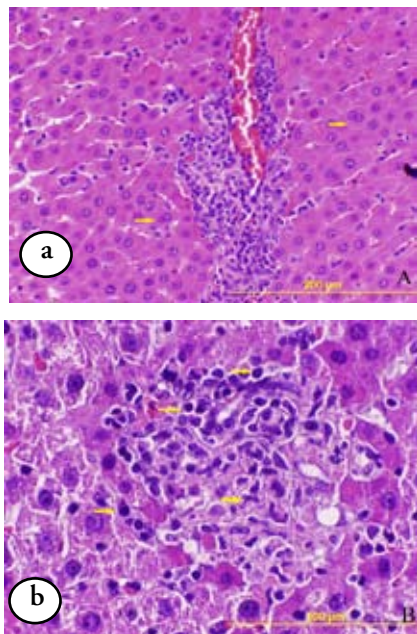


Figure 5 - Diabetic group, insulin and N^G-nitro-L-arginine methyl ester (L-NAME) treatment lead to a) the hepatocyte regeneration (yellow arrow), b) the minimal mononuclear cell infiltration in portal area (yellow arrows), had found hematoxylin and eosin, original magnification x200 and 400 respectively.

normal vena centralizes, and sinusoidal structures were observed. Pseudolobulation was not observed (Figure 4). In the STZ + insulin + L-NAME, induced group lead to hepatocyte regeneration, and minimal mononuclear cell infiltration was noted (Figure 5).

Discussion. In this present study, insulin significantly lowered the serum glucose levels in the STZ + insulin, and STZ + insulin + L-NAME induced groups, compared to the diabetic group. Insulin was effective in lowering the serum glucose levels in STZ induced diabetic rats. On the contrary, L-NAME did not affect the blood glucose level. N^G-nitro-L-arginine methyl ester decreased NO level in STZ + L-NAME than the untreated group. It was not decreased in STZ + insulin induced group. Nitric oxide liver injury was observed in diabetic rats by using STZ. The recent studies defined, that one of the possible pathomechanisms of the diabetes mellitus is the motivation of NO synthesis in pancreatic islet cells, and/or in macrophages infiltrating the islets leading to NO overproduction, the cytotoxic free radical.¹⁴ On the other hand, the protective role of endogenous NO in liver ischemic reperfusion injury is supported indirectly by raised hepatocellular injury in post ischemic animals given NOS inhibitors, such as L-NAME or N-monomethyl-L-arginine (L-NMMA). Inducible NOS of the type NOS is less clear, that it may act to mediate liver injury.¹⁵ Also, when the liver tissue was investigated in the STZ-induced diabetic rats, STZ can be assigned to increase bio activation-based liver necrosis, and progression of liver injury, which leads to hepatic failure.¹⁶ The early phase injury, is thought to be mediated by Kupffer cell activation, and super anion oxidant stress. Subsequently, it is defined that oxidant stress is thought to be a powerful activator of inflammatory pathways culminating in massive neutrophil migration, adhesion, and cellular injury.¹⁷ The preliminary STZ-treated studies have revealed results similar to this study. Insulin decrease blood glucose level, but L-NAME did not affect it against STZ-treated rats. Besides, L-NAME affects NO inhibition, and morphological disarrangements. The liver injuries were observed such as, the increase of the portal fibrillary necrosis, bile duct stenosis with coagulation necrosis of the peripheral hepatocytes, and focal pseudo lobular structures without vena centralis were observed in the diabetic control. When the insulin is administrated to STZ-treated rats, it leads to minimal portal mononuclear cell infiltration, minimal stasis in bile canalicules, and interlobular venules. The sparse regeneration fields of the hepatocytes, local liquefaction focuses, dilated sinusoidal capillaries, and Kupffer cell proliferation were also noted. N^G-nitro-L-arginine

methyl ester treatment near to normal vena centralizes, and sinusoidal structures, and hepatocytes were observed. Pseudolobulation was not observed. Both of the treatments lead to hepatocyte regeneration, and minimal mononuclear cell infiltration was noted.

In conclusion, this study revealed that L-NAME inhibit the NO level, as a result of either alone, or with insulin combination significantly attenuates the liver morphological disarrangements via inhibition of NO synthesis in STZ induced diabetic rats. Further studies are needed to evaluate the role of NO and its mechanism in diabetes with details.

References

- Dong H, Morral N, McEvoy R, Meseck M, Thung SN, Woo SL. Hepatic insulin expression improves glycemic control in type1 diabetic rats. *Diab Res Clin Prac* 2001; 52: 153-163.
- Yu WJ, Juang SW, Chin WT, Chi TC, Wu TJ, Cheng JT. Decrease of nitric oxide synthase in the cerebrocortex of streptozotocin-induced diabetic rats. *Neurosci Lett* 1999; 272: 99-102.
- Degirmenci I, Ustuner MC, Kalender Y, Kalender S, Gunes HV. The Effects of acarbose and Rumex patientia L. on ultrastructural and biochemical changes of pancreatic B cells in streptozotocin-induced diabetic rats. *J Ethnopharmacol* 2005; 97: 555-559.
- Katakam AK, Chipitsyna G, Gong Q, Vancha AR, Gabbeta J, Arafat HA. Streptozotocin (STZ) mediates acute upregulation of serum and pancreatic osteopontin (OPN): a novel islet-protective effect of OPN through inhibition of STZ-induced nitric oxide production. *J Endocrinol* 2005; 187: 237-247.
- Pagano PJ, Griswold MC, Ravel D, Cohen RA. Vascular action of the hypoglycaemic agent gliclazide in diabetic rabbits. *Diabetologia* 1998; 41: 9-15.
- Kamalakkannan N, Stanely Mainzen Prince P. Rutin improves the antioxidant status in streptozotocin-induced diabetic rat tissues. *Mol Cell Biochem* 2006; 293: 211-219.
- Saeed MK, Deng Y, Dai R. Attenuation of biochemical parameters in streptozotocin-induced diabetic rats by oral administration of extracts and fractions of cephalotaxus sinensis. *J Clin Biochem Nutr* 2008; 42: 21-28.
- Duarte ID, Ferreira SH. L-NAME causes antinociception by stimulation of the arginine-NO-cGMP pathway. *Mediators Inflamm* 2000; 9: 25-30.
- Gunes HV, Degirmenci I, Aydin M, Bozan B, Aral E, Tunalier Z, et al. The effects of Rumex patientia L. and Urtica dioica L. on some blood and urine parameters, liver and kidney histology in the diabetic rats. *Tr J Med Sci* 1999; 29: 227-232.
- Chen S, Yuan CM, Haddy FJ, Pamnani MB. Effect of administration insulin of streptozotocin-induced diabetic hypertension in rat. *Hypertension* 1994; 23: 1046-1050.
- Fang TC, Wu CC, Huang WC. Inhibition of nitric oxide synthesis accentuates blood pressure elevation in hyperinsulinemic rats. *J Hypertens* 2001; 19: 1255-1262.
- El-Mahmoudy A, Shimizu Y, Shiina T, Matsuyama H, El-Sayed M, Takewaki T. Successful abrogation by thymoquinone against induction of diabetes mellitus with streptozotocin via nitric oxide inhibitory mechanism. *Int Immunopharmacol* 2005; 5: 195-207.
- Cortas NK, Wakid NW. Determination of inorganic nitrate in serum and urine by a kinetic cadmium-reduction method. *Clin Chem* 1990; 36: 1440-1443.
- Hrabák A, Szabó A, Bajor T, Körner A. Differences in the nitric oxide metabolism in streptozotocin-treated rats and children suffering from Type 1 diabetes. *Life Sci* 2006; 78: 1362-1370.
- Kawachi S, Hines IN, Laroux FS, Hoffman J, Bharwani S, Gray L, et al. Nitric oxide synthase and postischemic liver injury. *Biochem Biophys Res Commun* 2000; 276: 851-854.
- Wang T, Fontenot RD, Soni MG, Bucci TC, Mehendale HM. Enhanced hepatotoxicity and toxic outcome of thioacetamide in streptozotocin-induced diabetic rats. *Toxicol Appl Pharmacol* 2000; 166: 92-100.
- Rogers H, Zibari GB, Roberts J, Turnage R, Lefer DJ. Nitric oxide attenuates ischaemicperfusion (I/R) injury in the diabetic liver. *Clin Transplant* 2004; 18 (Suppl 12): S7-S11.

Ethical Consent

All manuscripts reporting the results of experimental investigations involving human subjects should include a statement confirming that informed consent was obtained from each subject or subject's guardian, after receiving approval of the experimental protocol by a local human ethics committee, or institutional review board. When reporting experiments on animals, authors should indicate whether the institutional and national guide for the care and use of laboratory animals was followed.