

Pseudomyxoma peritonei

Presenting as a localized perforation of the cecum

Fraz Fahim, FCPS, FRCS, Saleh M. Al-Salamah, MBBS, FRCS.

ABSTRACT

الورم مخاطي صفاقي كاذب (PMP) والذي يعرف بالهلام البطني هو حالة نادرة، تنتشر فيها المواد المخاطية وتملأ كامل جوف البطن. يمكن أن تنشأ عن الزائدة الدودية أو القولون أو حتى من الورم المسخي، نسبة حدوثها تقارب واحد بالمليون كل سنة. نعرض حالة لمريضة عمرها 80 عام اكتشف لديها ورم مخاطي صفاقي كاذب PMP نتيجة لورم الزائدة الدودية أدى إلي حدوث انتشار موضعي للورم وانثقاب جدار المعي الغليظ الأعور. تمت أيضا مراجعة للحالات المنشورة المماثلة وعرض إمكانية العلاج لهذه الحالة النادرة.

Pseudomyxoma peritonei (PMP), also known as “jelly belly,” is a rare condition with mucinous material spread throughout the abdomen. It can arise from the appendix, colon, or even a teratoma. The documented incidence is one per million per year. We present a case report of an 80-year-old female patient presenting with PMP secondary to an appendicular tumor leading to localized infiltration, and perforation of the cecal wall. A review of the literature was carried out, with emphasis on various treatment options available for this rare condition.

Saudi Med J 2009; Vol. 30 (10): 1350-1352

From the Department of Surgery, University Unit, College of Medicine, King Saud University, Riyadh Medical Complex, Riyadh, Kingdom of Saudi Arabia.

Received 18th August 2009. Accepted 26th September 2009.

Address correspondence and reprint request to: Professor Saleh M. Al-Salamah, Consultant General Surgeon, Department of Surgery, University Unit, College of Medicine, King Saud University, Riyadh Medical Complex, PO Box 261283, Riyadh 11342, Kingdom of Saudi Arabia. Tel. +966 (1) 4671585/4350488. Fax. +966 (1) 4679493. E-mail: smsalamah@hotmail.com

Pseudomyxoma peritonei (PMP) is a rare condition that is characterized by mucinous material, spreading throughout the abdomen with peritoneal and omental mucinous implants.¹ It has an estimated incidence of one per million per year.² There is a generalized intraperitoneal dissemination of mucinous tumor, which presents clinically as “jelly belly.”² It can also be discovered as an incidental finding during a celiotomy. The entity called PMP, comprised a heterogeneous group of pathologic lesions.³ Peritoneal seedlings disseminate from a ruptured adenoma, or a well-differentiated mucinous adeno-carcinoma of the large intestine, most frequently the appendix. It can also arise from a mature cystic teratoma.⁴ And, it may present as acute appendicitis, or a pelvic mass.⁵ We present a case of localized perforation secondary to PMP, to emphasize that this rare cause may be considered in cases of acute abdomen, and also to highlight the latest treatment options available.

Case Report. An 80-year-old, bedridden female presented with vague abdominal pain, and decreased oral intake for one week, followed by persistent vomiting. She was a known case of diabetes mellitus and hypertension, on treatment with right-sided hemiplegia following a cerebrovascular accident 5 years earlier. There was no history of previous surgery. Upon examination, she had low grade fever (38°C), generalized tenderness with rebound, but no rigidity. There was an ill-defined soft mass in the right iliac fossa, extending up to the right lumbar area. The digital rectal exam revealed soft yellowish stool. The bowel sounds were sluggish. White cell count was $3.4 \times 10^9/L$, while the blood urea nitrogen was 16.7 mg/dl, and serum creatinine was 253 $\mu\text{mol/l}$. Plain radiology of the abdomen was non-specific. Contrast enhanced abdominal CT (Figure 1) revealed hydropneumoperitoneum with loculated peritoneal collection in addition to a 10 x 18 cm low attenuation mass in the right iliac fossa. The contrast was leaking

in the peritoneal cavity in the same area, however, the source of this leak could not be accurately localized. The patient was taken to the operating room with a diagnosis of perforated viscus. Exploratory laparotomy revealed 500 ml fecal smelling pus, and thickened peritoneum. The cecum and right adnexal region were formed into a 10 cm x 20 cm jelly-like mass with a 0.5 cm x 0.5 cm perforation in the cecum (Figure 2). Multiple gelatinous implants were seen all over the peritoneal surface and liver, with a large 5 cm x 5 cm implant on the terminal ileum. A right hemicolectomy was carried out, with ileostomy and mucous fistula. Extensive resection of all the tumor implants was undertaken resulting in some loss of blood. The patient had an eventful recovery necessitating intensive care unit stay. Her renal function

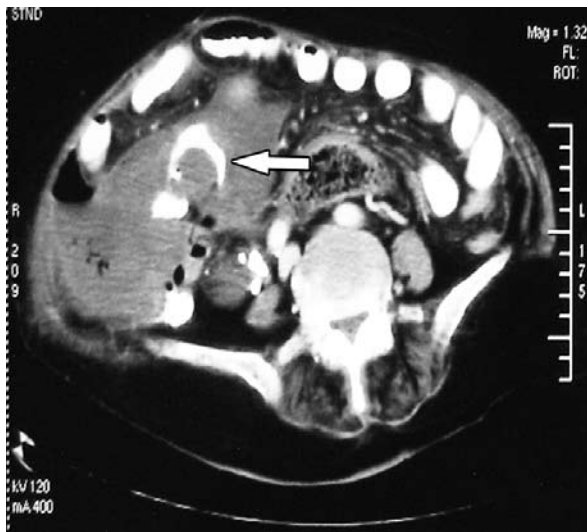


Figure 1 - Computed tomography cut of the tumor in the right iliac fossa.

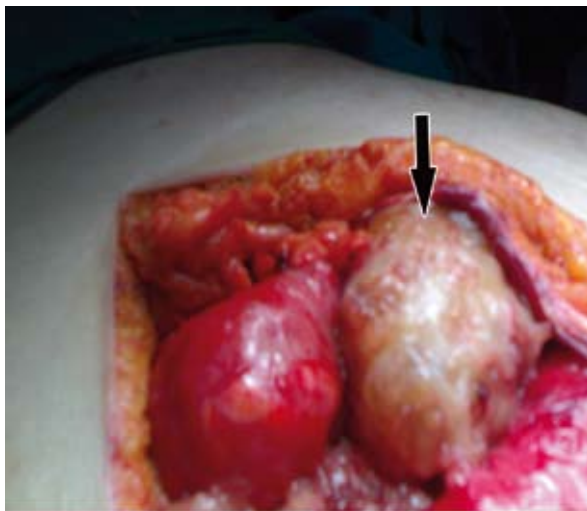


Figure 2 - Gelatinous mass in the right iliac fossa.

recovered, and she resumed oral intake. However, she was still bedridden due to her hemiplegia, and was on deep venous thrombosis prophylaxis. The fluid from the peritoneal cavity grew *Escherichia coli* and *Enterococcus faecalis*. Histopathology revealed a moderately differentiated mucinous adenocarcinoma, involving the serosa of the cecum, but extending to the mucosa in the area of perforation. The appendix could not be clearly identified, but the proximal and distal margins were free of tumor. There was no vascular, perineural, or lymph node invasion identified. Immunohistochemistry of the specimen was carried out to determine the origin of the tumor, and it was negative for cytokeratin (CK)-7, and positive for CK-20 and carcinoembryonic antigen (CEA). This pattern of CK immunoreactivity, typical of a tumor of intestinal/colonic origin, coupled with operative findings of obliterated appendix with the tumor replacing it led us to the diagnosis of appendicular origin of PMP in our patient. An oncology consult was obtained, and adjuvant chemotherapy was planned. However, on the seventeenth post-operation day, she developed massive pulmonary embolism, and could not be resuscitated.

Discussion. The PMP has been variously named as “myxomatous peritonitis” or “mucinous ascites” or “jelly belly.”⁶ It was first described by Werth in 1884.⁷ The PMP is a syndrome, in which mucinous tumor implants spread throughout the peritoneal cavity culminating in a localized, or generalized mucinous ascites, which can compress the intestines causing obstruction, and death of the patient secondary to malnutrition, or due to surgery related complications.² It is a slowly progressive disease. The characteristic PMP distribution was described by Sugarbaker⁸ as a complete redistribution phenomenon, indicating a complete sequential invasion of the peritoneal cavity with large volumes of tumor at limited sites, and no invasion at other sites. The first step is the accumulation of tumor cells at the sites of peritoneal fluid resorption, followed by implants settling in dependent areas of the peritoneal cavity.⁹ The present case was an early variety of this tumor with localized accumulation of the gelatinous tumor mass in the right iliac fossa. However, the tumor demonstrated a strong tendency towards local invasion, as demonstrated by the cecal wall involvement and perforation.

The term PMP is used to describe numerous conditions that lead to excessive accumulation of mucus in the peritoneal cavity. The tumor is thought to originate from the mucus adenoma of the appendix, a mucus producing gastrointestinal adenoma, mature cystic teratoma, or peritoneal mucinous carcinomatosis (PMCA) of unknown origin.^{4,10} Histologically, it shows

abundant extracellular mucus, with or without epithelial cells. Focal proliferation is limited, and lymphangio invasion is not seen.³ The PMP was differentiated into disseminated peritoneal adenomucinosis, and the more aggressive and invasive PMCA, which presents with cytological features of the carcinoma, as was seen in our case.¹¹ Extraperitoneal spread of the disease is unusual, as in our patient, and if it occurs, is typically iatrogenic. The PMP typically presents as abdominal distention, or abdominal pain, and not uncommonly as a mucin containing scrotal, or hernial mass, and the preoperative diagnosis is usually acute appendicitis, or a pelvic mass.¹² However, its presentation as a perforation of the viscus seems to be unique.

The traditional treatment had been repeated surgical excisions. This approach had resulted in an estimated 10-year survival rate of 10-50%.¹³ However, Sugarbaker^{13,14} introduced the current surgical approach comprising cytoreductive surgery involving peritonectomy, and complete removal of the tumor. This can be followed by locoregional/intraperitoneal chemotherapy to eliminate residual tumor cells.¹⁴ The additional effect of intraperitoneal hyperthermic perfusion using special pumps can increase the drug concentration in the tumor, and augment its efficacy.¹⁴ This multidisciplinary approach has benefited the patient, in terms of locoregional disease control, and even survival, achieving a 5-year survival rate of up to 86%.¹⁵ However, such aggressive curative therapy should be reserved for patients with relatively good performance status, and may not have been appropriate for our patient.

The CEA has been proposed as a tumor marker for PMP along with cancer antigen (CA) 125 and CA 19-9, and it has been postulated that patients with elevated CEA, or more than one abnormal serum tumor marker, are at a significant risk of developing recurrent disease.²

In conclusion, we can surmise that PMP is a rare condition that can arise from a variety of organs and has varied presentations. Treatment is multidisciplinary including cytoreductive surgery followed by locoregional chemotherapy. Newer techniques, like intraperitoneal hyperthermic chemotherapy, can further improve the results of the treatment. This has resulted in a good medium term prognosis for this rare entity.

References

1. van Ruth S, Acherman YI, van de Vijver MJ, Hart AA, Verwaal VJ, Zoetmulder FA. Pseudomyxoma peritonei: a review of 62 cases. *Eur J Surg Oncol* 2003; 29: 682-688.
2. Alexander-Sefre F, Chandrakumaran K, Banerjee S, Sexton R, Thomas JM, Moran B. Elevated tumour markers prior to complete tumour removal in patients with pseudomyxoma peritonei predict early recurrence. *Colorectal Dis* 2005; 7: 382-386.
3. Rusch VW, Niedzwiecki D, Tao Y, Menendez-Botet C, Dnistrian A, Kelsen D, et al. Intraleural cisplatin and mitomycin for malignant mesothelioma following pleurectomy: pharmacokinetic studies. *J Clin Oncol* 1992; 10: 1001-1006.
4. Hwang JH, So KA, Modi G, Lee JK, Lee NW, Lee KW, et al. Borderline-like mucinous tumor arising in mature cystic teratoma of the ovary associated with pseudomyxoma peritonei. *Int J Gynecol Pathol* 2009; 28: 376-380.
5. Esquivel J, Sugarbaker PH. Clinical presentation of the pseudomyxoma peritonei syndrome. *Br J Surg* 2000; 87: 1414-1418.
6. Long RT, Spratt JS Jr, Dowling E. Pseudomyxoma peritonei. New concepts in management with a report of seventeen patients. *Am J Surg* 1969; 117: 162-169.
7. Werth R. Pseudomyxoma peritonei. *Arch Gynecol Obstet* 1884; 24: 100-118.
8. Sugarbaker PH. Pseudomyxoma peritonei: A cancer whose biology is characterized by a redistribution phenomenon. *Ann Surg* 1994; 219: 109-111.
9. Deraco M, Santoro N, Carraro O, Inglese MG, Rebuffoni G, Guadagni S, et al. Peritoneal carcinomatosis: feature of dissemination. A review. *Tumori* 1999; 85: 1-5.
10. Murphy S, Amin AI, Tanner WA, O'Neil H, Moran BJ. Pseudomyxoma peritonei syndrome originating from a perforated retrocaecal appendiceal adenoma. *Journal of the Irish Colleges of Physicians and Surgeons* 2002; 31: 150-152.
11. Ronnett BM, Zahn CM, Kurman RJ, Kass ME, Sugarbaker PH, Shmookler BM. Disseminated peritoneal adenomucinosis and peritoneal mucinous carcinomatosis. A clinicopathologic analysis of 109 cases with emphasis on distinguishing pathologic features, site of origin, prognosis, and relationship to pseudomyxoma peritonei. *Am J Surg Pathol* 1995; 19: 1390-1408.
12. Pai RK, Longacre TA. Appendiceal mucinous tumors and pseudomyxoma peritonei: histologic features, diagnostic problems, and proposed classification. *Adv Anat Pathol* 2005; 12: 291-311.
13. Sugarbaker PH. Peritonectomy procedures. *Ann Surg* 1995; 221: 29-42.
14. Sugarbaker PH. Cytoreductive surgery and intraperitoneal chemotherapy with peritoneal spread of cystadenocarcinoma. *Eur J Surg Suppl* 1991; 561: 75-82.
15. Deraco M, Baratti D, Inglese MG, Allaria B, Andreola S, Gavazzi C, et al. Peritonectomy and intraperitoneal hyperthermic perfusion (IHP): a strategy that has confirmed its efficacy in patients with pseudomyxoma peritonei. *Ann Surg Oncol* 2004; 11: 393-398.