

Fatal abdominal sarcomatosis secondary to gastrointestinal stromal tumor with bland histology

Yasmin M. Elshenawy, MD, Charles E. Ganote, MD, Mousa A. Al-Abbadi, MD.

ABSTRACT

يعد داء ساركومي المميت من المضاعفات النادرة الثانوية لورم الأنسجة المعوية (GIST) والذي ينشأ من الأمعاء الدقيقة. يصف هذا التقرير حالة مريض يبلغ من العمر 49 عام بدأت بتشخيص استسقاء كبير الحجم مع العديد من الكتل المساريقية الصلبة. أثبت تشريح الجثة وجود كتلة ضخمة تبلغ 19x14x8.0 سم محيطة بالدقاق، بالإضافة إلى وجود العديد من الكتل الأصغر في الثرب، المساريقا والسطوح المصلية الأخرى. أظهر التحليل النسيجي وجود كثافة عالية من الخلايا المغزلية ذات فعالية انقسامية منخفضة جدا. تم إثبات تشخيص ورم الأنسجة المعوية GIST بالإيجابية الشديدة ل c-KIT (CD117). تعتبر الحالة المقدمة مثلا داء ساركومي المميت الناجم عن أورام الأنسجة المعوية GIST والتي كانت فيها الخصائص النسيجية سليمة.

Fatal abdominal sarcomatosis is a rare complication secondary to gastrointestinal stromal tumor (GIST) arising from the small intestine. Here, we describe a 49-year-old man who presented with massive ascites and multiple mesenteric solid masses. Autopsy showed large necrotic mass (19x14x8.0 cm) surrounding the terminal ileum with multiple smaller nodules on the omentum and mesentery. Histological examination revealed highly cellular, predominantly bland, spindle cells with low mitotic activity. Gastrointestinal stromal tumor was confirmed by strong positive staining for c-KIT (CD 117). Our case is an example of fatal intra-abdominal sarcomatosis of GIST where the histological features were essentially bland.

Saudi Med J 2009; Vol. 30 (11): 1469-1472

From the Department of Pathology and Laboratory Medicine, James H. Quillen VA Medical Center and James H. Quillen Medical School, East Tennessee State University, Tennessee, United States of America.

Received 28th July 2009. Accepted 30th September 2009.

Address correspondence and reprint request to: Dr. Mousa A. Al-Abbadi, Department of Pathology and Laboratory Medicine, James H. Quillen VA Medical Center, PO Box 4000 (Lamount and Veterans Way), Mountain Home TN 37684, Tennessee, United States of America. E-mail: mousa.al-abbadi@va.gov

Gastrointestinal stromal tumors (GIST) are a heterogeneous group of rare malignant mesenchymal neoplasms of the gastrointestinal tract. Early described in 1941 where they originally thought to be of smooth muscle origin including leiomyosarcoma, leiomyoma or leiomyoblastoma.^{1,2} The origin of this tumor was questioned by electron microscopic studies in the 1960s that failed to confirm the presence of smooth muscle differentiation in the so called "gastric leiomyomas". The current understanding of GIST was initiated in 1998; when Hirota et al³ and Miettinen and Lasota⁴ discovered the mutated c-KIT (CD117) gene in GIST. The term GIST was then used to describe tumors with c-KIT mutation with ability to differentiate similarly to interstitial cells of Cajal (ICC); the physiological pacemaker of gastrointestinal tract.² Both ICCs and GISTs express KIT protein and have similar ultra structural features. However, not all GISTs arise from ICC, as some arise from the mesentery or omentum which lack ICCs, suggesting an origin from multi-potent mesenchymal stem cell.⁴ Gastrointestinal stromal tumors harbor one of several characteristic mutations which yield abnormal protein products that can be detected by ancillary studies. There are 2 main mutations in the family of tyrosine kinase gene receptors. First, is the prototype mutation leads to expression of c-KIT (CD 117).^{1,2} It involves mutation exons 11 (most common), 9, 13 or 17.^{1,2} The second mutation involves the platelet derived growth factor receptor antigen (PDGFR) where exons 12, 14 and 18 are mostly affected.^{1,2} A third group is the wild type GIST which lack cKIT/PDGFR but 10% are associated with BRAF mutation of exon 11 and 15. Consequently, testing for the exact type and location of a mutation in the KIT, PDGFR or BRAF genes can be used to predict responsiveness of tumors to tyrosine kinase inhibitor Imatinib Mesylate (Gleevec™).^{2,5,6} In the United States of America the annual incidence of GIST is 4500-6000.¹ The tumor usually affects adults over 50 years of age without gender predilection. Gastrointestinal stromal tumors occurs anywhere along the gastrointestinal tract, with stomach being the most common site

(approximately 60%), followed by small intestine (20-30%) and <10% are located in colon and rectum.² In all cases, symptoms are site and size dependent. Most benign GISTs are solitary, asymptomatic and are discovered incidentally. Symptomatic patients can present with pain, bleeding, obstruction or a mass with a size ranging between 1.0 and 35 cm in maximum dimension. On gross examination, most tumors are sub mucosal with well-circumscribed borders; cut surface is fleshy and solid, lacking the typical whorled bulging appearance of leiomyoma. Large tumors commonly exhibit central cystic degeneration; hemorrhage and/or necrosis.² Histological features are variable and often site dependent. Tumors can be of spindle cell, epithelioid cell or mixed cell type. Malignant GISTs commonly disseminate through peritoneum and then metastasize to liver and rarely to bone, lymph nodes and lung. Hematogenous spread is the most common pathway.² Disseminated intra-abdominal GIST is a rare incident occurring in less than 5% of the reported cases.² Herein we report a unique case of fatal widely disseminated intra-abdominal GIST with bland histological features and interestingly negative cytological examination of ascitic fluid. We are emphasizing the role of pathological prognostic parameters in clinical categorization for this group of tumors.

Case Report. A 49-year-old white male with past medical history of hypertension, gastro-esophageal reflux disease, benign prostatic hyperplasia and infertility, who was admitted to our institution through the emergency department with abdominal distention that had been present for 6 months, but which worsened in the week preceding admission. The patient also reported progressive shortness of breath and a 2 day history of

diarrhea with intermittent hematochezia. Physical examination revealed a tense distended abdomen with massive ascites. There was focal tenderness in the right upper quadrant and a slightly bulging umbilicus but palpable masses were not evident. A computerized tomography (CT) abdominal scan showed massive ascites, multiple mesenteric solid masses and a quite large distal mesenteric (19 x 14 cm) mass. Bone scan was negative for metastatic disease. There were no liver masses or adenopathy. Abdominal paracentesis recovered 3.2 liter of yellow-cloudy ascitic fluid with elevated LDH. Cultures grew 4+ *Escherichia coli*. Differential diagnosis at this time included metastatic neoplasm, lymphoma or GIST. Cytological examination of the ascitic fluid was performed twice and was negative for malignant cells with only reactive mesothelial cells and scattered mixed inflammatory cells identified. Following admission, antibiotic and supportive therapy was initiated. One day after admission, the patient's condition worsened, necessitating transfer to the intensive care unit. He subsequently developed irreversible septic shock with multi-organ failure and he died on the fourth hospital day. Consent for a restricted autopsy (abdomen only) was granted by the family.

Autopsy findings. The abdominal bloc contained numerous round, both sessile and pedunculated gray tan tumor implants of the omentum, mesentery and the serosal surfaces of both the large and small intestines (Figure 1a). The largest tumor nodule measured 19 x 14 x 8.0 cm and was attached to the ileum, 80 cm proximal to the ileocecal valve (Figure 1b). The cut surface of the tumor was necrotic and cystic. Focally, the tumor protruded into the lumen in "dumbbell" shape fashion with ulceration of the mucosa continuous with necrotic

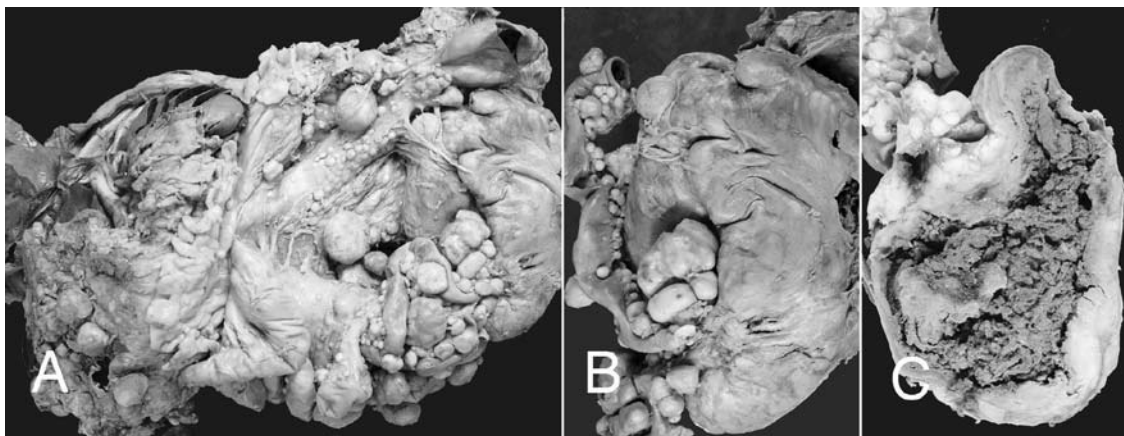

Figure 1 - Autopsy specimen demonstrating the a) numerous gray tan tumor implants of the omentum, mesentery and the serosal surfaces of both the large and small intestines. b) Largest tumor nodule surrounding the terminal ileum with other multiple implants on surface. c) Cut section of largest tumor nodule demonstrating the tract connecting the tumor necrotic center with the intestinal lumen.

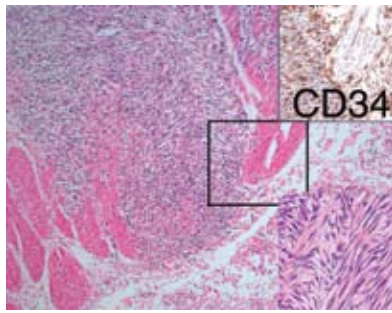


Figure 2 - Ileal wall, with highly cellular spindle cell tumor infiltrating and separating the bundles of smooth muscle of muscularis mucosa. The tumor spindle cells in interlacing herring bone pattern of growth. Tumor cells demonstrate focal positive immunohistochemical staining for CD34 (Hematoxylin-eosin, original magnification x 10).

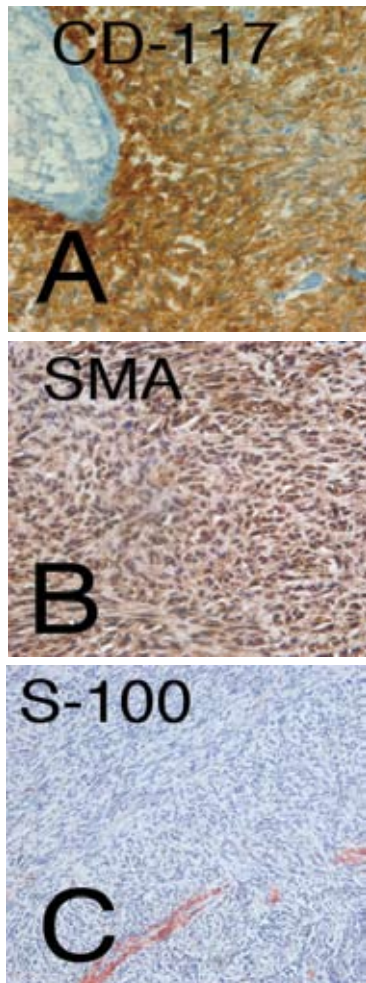


Figure 2 - Immunohistochemical stains for the proteins S-100, smooth muscle actin (SMA) and CD117(c-KIT). Tumor cells demonstrate diffuse positive staining for a) CD117 and b) positive staining for SMA. c) Negative staining for S-100 (original magnifications x 40).

tumor, forming a tract connecting the tumor necrotic center with the intestinal lumen (Figure 1c). However, and interestingly, there was no luminal obstruction. Mesenteric and retroperitoneal lymph nodes were not enlarged, and on histological examination they proved to be negative for tumor.

Microscopic examination. Extensive sampling was performed where 20 blocks were taken from the tumor and multiple levels were examined. At low power, the histological sections of the tumor revealed a highly cellular whorling spindle cell tumor with pseudo palisading bands of short intersecting fascicles. Cells had pale to eosinophilic cytoplasm with plump nuclei containing inconspicuous nucleoli. Rare mitoses were seen and calculated at 2 per 50 HPFs, on 3 separate counting settings. There was no significant cellular or nuclear pleomorphism (Figure 2). The tumor cells stained with CD117 (Figure 3a), smooth muscle actin (Figure 3b), and focally with CD 34 (Figure 2), but were negative for S-100 protein (Figure 3c).

Discussion. Abdominal sarcomatosis (AS) is the occurrence of diffuse abdominal soft tissue sarcoma without extra-abdominal dissemination.⁷ It usually occurs with retroperitoneal soft tissue sarcoma, liposarcomas, GIST, and pelvic tumors such as leiomyosarcoma. Widely metastatic abdominal sarcomatosis due to GIST is rare and has been reported in approximately 5% of the cases and most commonly following tumor recurrence.² This type of abdominal sarcomatosis usually carries an ominous prognosis.^{7,8} Prediction of malignant behavior of GIST is problematic and sometimes controversial. Gastrointestinal stromal tumors can be categorized into very low, low, intermediate, and high risk for malignancy based on mitotic index and tumor size.^{1,6} The most important prognostic predictors for malignant behavior of GIST include size, mitotic count and anatomic site of primary tumor.^{1,2} Gastric GIST has more favorable prognosis than intestinal GISTs. Tumors less than 20 mm with less than 5/50 Hpf mitotic figures have a very low risk for malignant behavior. Other pathological parameters associated with high malignant potential are increased cellularity, diffuse mucosal invasion, and ulceration.⁹ In their recent study, Previous study⁶ attempted to define more specific parameters that help determine the stage and histological grade of such tumors. Peritoneal dissemination along with liver metastasis were considered the important gross spread parameters. They divided the malignant GIST into 2 clinical stages, (I and II) depending on the gross spread parameters. Clinical stage II had the most aggressive behavior regardless of the number of other parameters. Our patient could fit

into the second group. In contrast, Katz and DeMatteo⁹ study of 200 patients with GIST found that mitotic activity is the dominant predictor of outcome over size and site. Other variables associated with poor outcome include tumor rupture, which may lead to peritoneal recurrence, diffuse mucosal invasion and tumor cell aneuploidy. The cellular proliferation index, expressed by Ki-67 immunostaining, was an independent prognostic factor.⁹ In addition, the same group reported that telomerase expression which occurred in 29% of primary GIST and was expressed in all cases of metastatic disease, may harbor a strong prognostic significance.⁹ Nowadays, interventional diagnostic biopsy can aid in establishing a correct preoperative diagnosis of GIST utilizing endoscopic ultrasound guided fine needle aspiration biopsy (EUS-FNA). The procedure is safe and currently a well-established quick and cost effective diagnostic approach.¹⁰ However, GIST tumors remain of interest because of the unresolved issue concerning the usefulness of morphological features in predicating tumor malignant behavior and prognosis.

In summary, this report is of a case having bland histological and cytological features, but with an aggressive and eventually fatal clinical behavior. This case is also unique to document the absence of recognizable tumor cells after peritoneal fluid cytological examination despite extensive peritoneal sarcomatosis.

References

1. Rubin BP. Gastrointestinal stromal tumours: an update. *Histopathology* 2006; 48: 83-96.
2. Miettinen M, Lasota J. Gastrointestinal stromal tumors: review on morphology, molecular pathology, prognosis, and differential diagnosis. *Arch Pathol Lab Med* 2006; 130: 1466-1478.
3. Hirota S, Isozaki K, Moriyama Y, Hashimoto K, Nishida T, Ishiguro S, et al. Gain-of-function mutations of c-kit in human gastrointestinal stromal tumors. *Science* 1998; 279: 577-580.
4. Miettinen M, Lasota J. Gastrointestinal stroma tumors-definition, clinical, histological, immunohistochemical, and molecular genetic features and differential diagnosis. *Virchows Arch* 2001; 438: 1-12.
5. Agaimy A, Terracciano LM, Dirnhofer S, Tornillo L, Foerster A, Hartmann A, et al. V600E BRAF mutations are alternative early molecular events in a subset of KIT/PDGFR α wild-type gastrointestinal stromal tumours. *J Clin Pathol* 2009; 62: 613-616.
6. Hou YY, Lu SH, Zhou Y, Qi WD, Shi Y, Tan YS, et al. Stage and histological grade of gastrointestinal stromal tumors based on a new approach are strongly associated with clinical behaviors. *Mod Pathol* 2009; 22: 556-569.
7. Rossi CR, Casali P, Kusamura S, Baratti D, Deraco M. The consensus statement on the locoregional treatment of abdominal sarcomatosis. *J Surg Oncol* 2008; 98: 291-294.
8. Bilimoria MM, Holtz DJ, Mirza NQ, Feig BW, Pisters PW, Patel S, et al. Tumor volume as a prognostic factor for sarcomatosis. *Cancer* 2002; 94: 2441-2446.
9. Katz SC, DeMatteo RP. Gastrointestinal stromal tumors and leiomyosarcomas. *J Surg Oncol* 2008; 97: 350-359.
10. Soper NJ, Swanström LL, Eubanks WS. *Mastery of Endoscopic and Laparoscopic Surgery*. 3rd ed. Philadelphia (PA): Lippincott Williams & Wilkins; 2009. p. 231.

Related topics

Hussain D, Baliga SK, Al-Madhi S, Hartung RU. Malignant gastrointestinal stromal tumor of the rectum with prolapse. *Saudi Med J* 2007; 28: 1291-1292.

Al-Moundhri MS, Al-Thahli K, Al-Kindy S, Salam J, Rao L. Metastatic gastrointestinal stromal tumor and hypercalcemia in a patient with ulcerative colitis *Saudi Med J* 2006; 27: 1585-1587.

Al-Salam S, El-Teraifi HA, Taha MS. Could imatinib replace surgery in esophageal gastrointestinal stromal tumor. *Saudi Med J* 2006; 27: 1236-1239.

Kara IO, Gonlusen G, Sahin B, Ergin M, Erdogan S. A general aspect on soft-tissue sarcoma and c-kit expression in primitive neuroectodermal tumor and Ewing's sarcoma. Is there any role in disease process? *Saudi Med J* 2005; 26: 1190-1196.