Post-keratoplasty emergency visits at a hospital in Jordan

Wafa M. Asfour, MD, FRCS, Reham I. Shaban, MD, DRCOphth.

ABSTRACT

الأهداف: تقييم الأعراض و الشكاوي المرضية التي تتم معاينتها كحالات طارئة بعد عمليات زراعة ترقيع القرنية (PKP) مع بيان طرق و نتائج العلاج.

الطريقة: تم تسجيل 60 حالة كمراجعة طارئة ل 55 من مرضى عمليات زراعة القرنية PKP في عيادة العيون – مدينة الحسين الطبية خلال الفترة ما بين يناير 2007 إلى يناير 2008.

النتائج: تقدم مجموعة 55 مريض كمراجعة طارئة خلال مدة سنة، بمختلف التشخيصات السابقة لعملية الزراعة منها: قرنية مخروطة 66.7%. وقد كان الألم و الشعور بجسم غريب في العين من أكثر الشكاوي شيوعاً بسبب وجود غرز مرتخية أو مقطوعة تحتاج لإزالة في 26.7%، كما كان تدني الرؤية المفاجئ من أهم الشكاوي لدى المرضى الذين لديهم علامات رفض للقرنية 25%. كما تم إدخال 14 مريض 23% للمستشفى لتلقي العلاجات المركزة أو لإعادة خياطة غرز مقطوعة، وبحمد الله فقد تم الحفاظ على سلامة نسيج القرنية في كل الحالات وعلى مستوى قوة الإبصار عند 96.3% من المرضى.

خاتمة: إن العناية المناسبة المشددة بعد عمليات زراعة القرنية بالغة الأهمية لنجاح العملية، كما أن التدخل السريع والمبكر للمضاعفات التي قد تؤثر على قوة الأبصار لتزيد من فرص بقاء نسيج القرنية وتؤدي لنجاح العملية و تحسن قوة الإبصار.

Objectives: To evaluate the different complaints and presentations, such as emergency visits, after penetrating keratoplasty (PKP), ways of management, and the outcome of these visits.

Methods: This prospective study included a total of 60 consecutive emergency visits by 55 post-PKP patients at the eye clinic in King Hussein Medical Center, Amman, Jordan between January 2007 and January 2008.

Results: Fifty-five patients were included (66.7%) with a preoperative diagnosis of keratoconus. Pain and gritty sensation were the main presenting symptoms; loose irritating sutures (26.7%), and graft rejection (25%) were the most common diagnoses. Fourteen patients (23%) were admitted to the hospital for either re-suturing or intensive treatment, the graft survived in all patients, while the visual acuity was preserved in 96.3%.

Conclusion: Proper postoperative care is critical for a successful penetrating keratoplasty; early intervention of sight threatening complications increases the chance of graft survival and best-obtained vision.

Saudi Med J 2009; Vol. 30 (12): 1568-1571

From the Eye Department, Royal Medical Services-King Hussein Medical Center, Amman, Jordan.

Received 23rd August 2009. Accepted 13th October 2009.

Address correspondence and reprint request to: Dr. Wafa M. Asfour, Cornea and Refractive Surgery Specialist, Royal Medical Services-King Hussein Medical Center, PO Box 3433, Amman 11181, Jordan. Tel. +962 (77) 7742725. Fax. +962 (6) 5814827. E-mail: wlasfour@hotmail.com

Modern microsurgical techniques and improved methods of eye banking and cornea preservation have resulted in a decreased incidence of postoperative complications of penetrating keratoplasty (PKP). The proper diagnosis and management of complications in the critical early postoperative period may prevent early graft failure, and improve long term graft survival.[1,2] Prevention of suture-related complications requires frequent monitoring and timely intervention.[3] Pre operative education of patients to recognize symptoms and signs of potential complications, and seek treatment immediately can improve graft survival.[2] The aim of this prospective study is to evaluate the different complaints and presentations as emergency visits after PKP, ways of management, and the outcome of these visits.

Methods. This prospective study was performed at the Ophthalmology Department, King Hussein Medical Center (KHMC), Amman, Jordan, and included 60 consecutive emergency visits (between January 2007

and January 2008) to the eye clinic, by 55 post-PKP patients of a cohort of 250 patients.

Inclusion criteria. Post-PKP patients who presented as Emergency visits and who were operated at KHMC, during the last 5 years (March 2003 and February 2007) were all included in the study, while patients who presented as emergency visit post-PKP, who underwent surgery in other hospitals, as well as patients with primary graft failure were excluded from this study. As per KHMC protocol, all of these surgeries were performed by 3 expert surgeons using well-adjusted buried-interrupted sutures, with a minimum follow-up period of 15 months. Patients were followed up for a minimum of 2 years, and the follow-up protocol normally included 12 scheduled examinations in the first year, 4 examinations in the second year, and 6 monthly, thereafter. Postoperative treatment normally included: prednisolone acetate 1% (Pred Forté), and Ofloxacin eye drops. Finally, the sutures were not normally removed before 12 months unless they were loose, causing irritation, or severe astigmatism by topography. The mean age of patients included in the study was 25 years, with a range of 8-67 years, and 60% were males. All patients who underwent PKP at KHMC were instructed to visit the eye clinic as soon as they experienced any unusual complaint without prior appointment (open access system). These patients were educated and informed on different symptoms they might experience; such as pain or gritty sensation, red eye, discharge, tearing, severe sensitivity to light, and sudden blurring of vision, patients were also educated on graft rejection, and the risk of late presentation. Patients were evaluated on the same day, and prompt treatment is commenced as early as possible, and preoperative information was recorded from patient's files. Patients were usually examined by their caring doctor, if available, or by the senior resident on call. All were assessed regarding symptoms, best-corrected vision (BCV), slit lamp examination, and treatment was given as indicated. Data collected included time from surgery, reason for presentation, duration of symptoms, and number of emergency visits by a single patient, clinical management, and outcome of each emergency visit. Informed patient consent was received from all study participants, and ethical approval was obtained from the Medical Research Committee of KHMC prior to commencement of the study.

Statistical analysis was carried out using Statistical Package for Social Sciences version 16.0 (SPSS Inc., Chicago, IL., USA) . A logistic regression model using background selection was constructed to identify prognostic variables for complications requiring inpatient management with a view to find out whether certain variables were prognostic for a patient being admitted to the hospital.

Results. The main indications for grafting are presented in **Table 1**. Pain and gritty sensation were the most common symptoms due to loose sutures, and occurred in 16 emergency visits (26.7%) as shown in **Figure 1** and **Table 2**. Spontaneous loosening or breakage of sutures was seen 2 weeks post surgery in 2 patients, and required admission for re-suturing due to early wound dehiscence, or manifest leakage from the wound. Blurring of vision was the most common symptom for emergency visits in patients with graft rejection, which occurred in 25% of the visits, and the duration post surgery was more than one year in 60% of patients. The types of rejection that presented as emergency visits are shown in **Figure 2**. These patients were treated with topical steroids (1% prednisolone), one patient with a history of 2 previous sub-epithelial rejection episodes, presented with Khodadoust endothelial rejection line and keratic precipitates, and he was admitted for pulse intravenous methyl prednisolone for 3 successive days, and all patients improved. Pain, blurred vision, and sensitivity to light were the presenting symptoms in patients with infective keratitis and abscesses post-PKP, which occurred in 6 patients. One was contact lens related, while all others were suture related, they had ulcerative epithelial defects with stromal infiltrates adjacent to loose irritating sutures, while one presented

Table 1 - Preoperative diagnosis.

Preoperative diagnosis	n (%)
Keratoconus	40 (66.7)
Corneal scars (post infection or trauma)	12 (20)
Pseudophakic bullous keratopathy	5 (8.3)
Corneal dystrophy	3 (5)

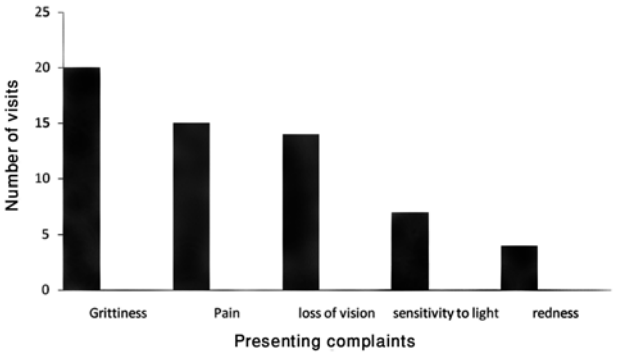

Figure 1 - Presenting complaints of patients during visits.

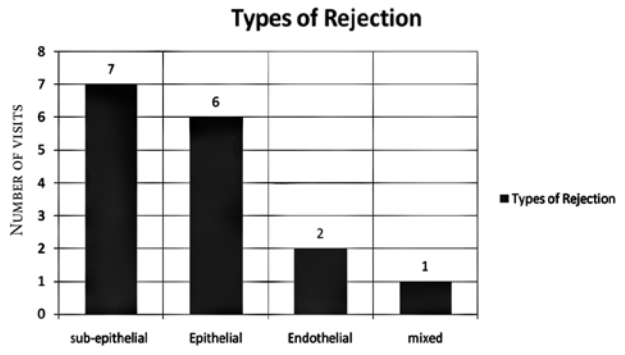

Figure 2 - Types of rejection at emergency visits.

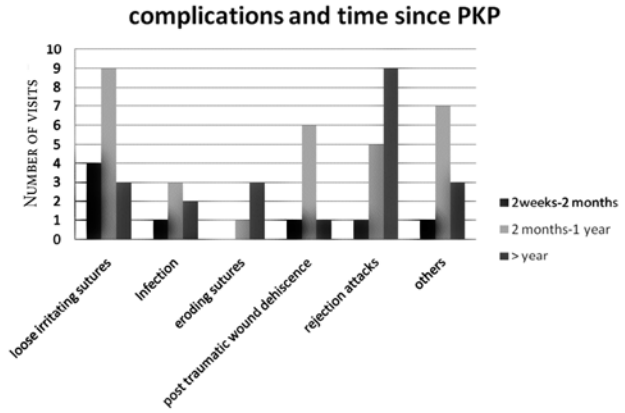

Figure 3 - Number of visits, complications at visits, and duration from penetrating keratoplasty surgery.

Table 2 - Diagnosis made on presentation at emergency visits.

Diagnosis	n=60
Loose irritating sutures	16
Rejection	15
Post-traumatic wound dehiscence	8
Infection/abscess	6
Eroding sutures	4
Others	11
Allergic conjunctivitis	4
Suture infiltrates	3
Filamentary keratitis	1
Foreign body (cornea)	1
Sub-conjunctival hemorrhage	1
Drug allergy	1

Table 3 - Probability of admission in relation to presenting vision.

Vision on presentation	Admission n (%)	Out-patient treatment n (%)
≤6/60	10 (55.6)	8 (44.4)
≥6/36	4 (9.5)	38 (90.5)

with infiltrates and hypopyon one week following selective suture removal. All lesions were cultured, the results revealed *Streptococcus pneumoniae* in 3 of them, *Staphylococcus aureus* in 2, and no growth in the fourth patient. All patients were treated with topical fortified Fortum, and fortified Vancomycin eye drops hourly, 2 patients were admitted with endophthalmitis and were also treated with daily sub-conjunctival antibiotic injections and vigorous topical fortified eye drops and they responded well, however, the visual acuity worsened in these 2 patients due to corneal scarring. Eight patients presented after trauma, they presented complaining of painful loss of vision, broken sutures, and leaking corneal wound. Two of them were due to accidental traumas, while the other 6 cases were due to assault; these patients were young and had PKP for keratoconus with age range of 13-18 years, all were admitted and surgically repaired. One patient had prolapsed vitreous and cataract, and required multiple surgeries with final postoperative visual acuity of less than 6/60. Suture erosions over the nylon sutures were also seen in 4 patients (8.3%), and in patients reporting grittiness and foreign body sensation (FB), the eroding sutures were removed, and broad-spectrum topical antibiotics were prescribed. Another 11 patients presented as emergency visits; they were complaining of red eyes, itching or FB sensation, and this was due to either allergic reaction in the other eye, suture infiltrates, corneal FB, or filamentary keratitis. There was no significant association between the number of attendance and age (r=0.20, p=0.13), and presenting vision (r=-0.17, p=0.21). We studied the probability of complications that needed admission in relation to the presenting vision (VA) (**Table 3**), as well as with presenting complaints. There was a significant association between the decreased VA on presentation (<6/60) and hospital admission (r=0.5, p=0.00). Traumatic wound dehiscence among patients with keratoconus was the cause of re-suturing in 8 patients, while a few broken sutures were the cause of re-suturing in 2 patients.

Discussion. The PKP creates a permanent weakness in the eyeball making it amenable to a lifelong risk of wound related problems.[4,5] In our study, the main cause of wound dehiscence was trauma in 75%, followed by broken sutures, that is in agreement with previous studies.[4-7] Patients with keratoconus usually belong to a younger age group, and may be prone to ocular trauma and possible wound rupture.[5,6,8,9]

Twelve patients (15 visits) in our study presented with signs of rejection, because of early presentation, and the open access system, and 96.3% of patients had graft survival with preservation of VA, and this is

comparable with Gnanaraj et al's[2] study. As shown in **Figure 3**, 60% of patients with rejection presented more than a year post-PKP surgery, similar to Gnanaraj et al's[2] study. For patients with attacks of graft rejection, we treated them according to attack of rejection, usually starting with an increase of the frequency of the topical prednisolone 1% eye drops, and in 2 patients, pulse therapy of intravenous methyl prednisolone was given for 3 days, while oral systemic steroids were sometimes added. However, Imuran 50 mg twice daily was needed for 2 of our young patients after consultation with the Pediatrics and Rheumatology specialists.

The only limitation of the study was that many of our patients came from far villages in the north and south of Jordan, some with poor hygiene. In this study, infectious keratitis was seen in 10% of visits, however, in Western countries the incidence of late infectious keratitis after PKP has ranged from 1.8-4.9%,[6] while Al-Hazzaa and Tabbara[10] reported an incidence of 11.9%, similar to our results, and can be attributed to similarities in both environment and ethnic groups in the Middle East.

Infection and suture abscesses occurred at an average of 10 months (**Figure 3**), and this is similar to the average time reported by Tseng et al[6]of 10.4 months, and 8.6 months according to Huang et al.[11] The microorganism reported in the studies performed by Leahy et al,[12] Christo et al,[3] and Tseng et al[6] were similar to the species found in the culture results of our study.

Prompt removal of broken sutures is essential to avoid sight threatening complications such as graft rejection and/or infection.[2,3] The suture erosions were mainly recognized to occur approximately 2 years, in patients with late retained sutures post surgery (**Figure 3**), and according to Dana et al,[13] suture erosions tend to escalate with increased elapsed time from surgery, especially beyond the 2 year postoperative period. The author reported them at 33 months,[14] while Siganos et al[14] reported suture erosions at 31.6 months.

In conclusion, proper postoperative care is critical for a successful PKP, early intervention of sight threatening complications increases the chance of graft survival and best-obtained vision. Although some patients could infrequently misuse the open access system, almost all emergency visits in our study were highly relevant.

Future studies should include a larger number of patients, with comparison among patients of different age groups, preoperative diagnosis, or indication of PKP surgery, and different patient's background.

Acknowledgment. *The authors gratefully acknowledge Ms. Manal Abu Dahab, for her valuable help in the statistics of this study.*

References

1. Scharf BH. Cornea: Surgery of the Cornea and Conjunctiva. In: Krachmer JH, Mannis MJ, Holland EJ, eds. 2nd ed. Edinburgh (London): Elsevier Mosby; 2005. p. 1513.
2. Gnanaraj L, Sandhu S, Hildreth AJ, Figueiredo FC. Postkeratoplasty emergency visits--a review of 100 consecutive visits. ***Eye*** 2007; 21: 1028-1032.
3. Christo CG, van Rooij J, Geerards AJ, Remeijer L, Beekhuis WH. Suture-related complications following keratoplasty: a 5-year retrospective study. ***Cornea*** 2001; 20: 816-819.
4. Jeganathan SV, Ghosh S, Jhanji V, Lamoureux E, Taylor HR, Vajpayee RB. Resuturing following penetrating keratoplasty: a retrospective analysis. ***Br J Ophthalmol*** 2008; 92; 893-895.
5. Renucci AM, Marangon FB, Culbertson WW. Wound dehiscence after penetrating keratoplasty: clinical characteristics of 51 cases treated at Bascom Palmer Eye Institute. ***Cornea*** 2006; 25: 524-529.
6. Tseng SH, Ling KC. Late microbial keratitis after corneal transplantation. ***Cornea*** 1995; 14: 591-594.
7. Das S, Whiting M, Taylor HR. Corneal wound dehiscence after penetrating keratoplasty. ***Cornea*** 2007; 26: 526-529.
8. Brown SI, Tragakis MP. Wound dehiscence with keratoplasty: complication of the continuous-suture technique. ***Am J Ophthalmol*** 1971; 72: 115-116.
9. Javadi MA, Motlagh BF, Jafarinasab MR, Rabbanikhah Z, Anissian A, Souri H, et al. Outcomes of penetrating keratoplasty in keratoconus. ***Cornea*** 2005; 24: 941-946.
10. Al-Hazzaa SA, Tabbara KF. Bacterial keratitis after penetrating keratoplasty. ***Ophthalmology*** 1988; 95: 1504-1508.
11. Huang SC, Wu SC, Wu WC, Hong HL. Microbial keratitis--a late complication of penetrating keratoplasty. ***Trans R Soc Trop Med Hyg*** 2000; 94: 315-317.
12. Leahey AB, Avery RL, Gottsch JD, Mallette RA, Stark WJ. Suture abscesses after penetrating keratoplasty. ***Cornea*** 1993; 12: 489-492.
13. Dana MR, Goren MB, Gomes JA, Laibson PR, Rapuano CJ, Cohen EJ. Suture erosion after penetrating keratoplasty. ***Cornea*** 1995; 14: 243-248.
14. Siganos CS, Solomon A, Frucht-Pery J. Microbial findings in suture erosion after penetrating keratoplasty. ***Ophthalmology*** 1997; 104: 513-516.