

Intrabursal vein abrasion and thrombosis

An unusual complication of femoral osteochondroma

Seyed M. Mahmoodi, MSc, MD, Ramesh K. Bahirwani, MS (Ortho), Badr A. Abdull-Gaffar, MD, FRC (Path),
Ihab F. Habib, MSc, MD.

ABSTRACT

نعرض حالة امرأة تبلغ من العمر 21 عام تعاني من ورم عظمي غضروفي متدلي في الفخذ اليمنى البعيدة. تم إدخالها المستشفى بسبب آلام شديدة وتورم في أسفل الطرف السفلي لمدة أسبوع. تؤيد النتائج السريرية تخثر الأوردة العميقة (DVT)، ولكن أشعة دوبلر للموجات فوق الصوتية، و الأشعة الوريدية كانت عادية. كشف التنقيب الجراحي عن وجود كيس حول الورم مع وريد كبير مكشوط و متخثر داخل الكيس. ولأول مرة في الأدبيات الطبية الإنجليزية يتم الإبلاغ عن كشط وتجلط الدم بالوريد داخل الكيس بسبب ورم عظمي غضروفي.

A 21-year-old female with right distal femoral pedunculated osteochondroma is presented. She was admitted for severe lower limb pain, and swelling of one week duration. Clinical findings supported deep vein thrombosis (DVT) but Doppler ultrasound, and venography were normal. Surgical exploration revealed a large bursa around the tumor with a big vein abraded and thrombosed inside the bursa.

Saudi Med J 2009; Vol. 30 (12): 1604-1606

From the Department of Orthopedics (Mahmoodi, Bahirwani), the Department of Histopathology (Abdull-Gaffar), and the Department of Radiology (Habib). Dubai Hospital, Dubai, United Arab Emirates.

Received 14th September 2009. Accepted 5th November 2009.

Address correspondence and reprint request to: Dr. Seyed M. Mahmoodi, Department of Orthopedics, Dubai Hospital, PO Box 7272, Dubai, United Arab Emirates. Tel. +971 (4) 2195000. Fax. +971 (4) 2719340. E-mail: smmahmoodi@dha.gov.ae

Osteochondroma is the most common benign bone tumor, constituting around 20-50% of all benign, and 10-15% of all skeletal tumors. It occurs frequently as a solitary osteocartilaginous exostosis and rarely as hereditary multiple lesions. The most common sites of occurrence are the long bones of the lower extremity usually the lower end of the femur and upper end of

the tibia.¹ Complications are commonly associated with these exophytic masses and include cosmetic and osseous deformity, fracture, vascular compromise, neurologic sequelae, overlying bursa formation, and malignant transformation. Variants of osteochondroma include subungual exostosis, dysplasia epiphysealis hemimelica, turret exostosis, traction exostosis, bizarre parosteal osteochondromatous proliferation, and florid reactive periostitis. Although radiography is often diagnostic, additional imaging modalities including bone scintigraphy, ultrasonography, computed tomography, and magnetic resonance imaging is frequently employed in evaluation of these lesions, particularly when they are symptomatic or in unusual locations.² Vascular complications associated with osteochondroma include vessel displacement, stenosis, occlusion, and formation of pseudoaneurysm.³ The aim of this report is to present a patient with clinical signs of right lower limb deep vein thrombosis (DVT) due to osteochondroma intrabursal vein thrombosis. The patient consented to publish medical information of her osteochondroma.

Case report. In January 2008, a 21-year-old female was admitted to Dubai hospital with one week history of acute right leg pain that started, while she stood up from squatting position. Prior to this, she was perfectly fit and healthy. Her medical history was unremarkable and had no history of trauma. Examination of her right lower limb showed diffuse swelling on the medial aspect of mid thigh. The right thigh circumference was 57 cm compared to the left thigh of 48 cm and right calf was 46 cm against 38.5 cm on the left side. Neurological examination of both legs was normal and all distal pulses were felt. The x-ray of the right femur showed pedunculated osteochondroma located medially between middle and lower thirds of the femoral shaft. Complete blood count, creatine phosphokinase, prothrombin time, partial thromboplastin time, liver function test, creatinine, and glucose tests were normal, but D-dimer was 0.8 mg/L, then increased to one

(range: less than 0.5); erythrocyte sedimentation rate 40 mm/1hr (range: 1-12 mm/1hr), and fibrinogen 662 mg/dL (range: 200-400 mg/dL). Clinical findings and laboratory tests were highly suspicious of deep vein thrombosis (DVT) of right lower limb, but Doppler ultrasound showed no evidence of DVT in the right common femoral, deep femoral, great saphenous, and popliteal veins. The computed tomography (CT) angiography of the right lower leg showed solitary irregular shaped osteochondroma posterior to distal right femur with multiloculated fluid collection around the tumor (Figure 1). The distal part of femoral artery was running through a narrow track, posterior and lateral to the tumor's stalk (Figure 2). It did not show significant narrowing, aneurysmal formation or extravasation of

the contrast media. Popliteal artery and its bifurcations were also normal. Venography of right anterior tibial, peroneal, posterior tibial, popliteal, femoral and external iliac veins showed no signs of aneurysm, stricture, filling defects or extravasation of the contrast media. She was operated on by a medial femoral approach, dissecting and retracting the femoral artery. There was a very large bursa (Figure 3) filled with hematoma and big vein inside the bursa showing abrasions and thrombosis (Figure 4). The vein was ligated, the bursa and the osteochondroma were excised, and the wound was managed routinely with no postoperative complications. Retrospective study of preoperative CT angiography showed the patent vein inside the bursa (Figure 5). Histopathology of the removed tumor was consistent with osteochondroma.

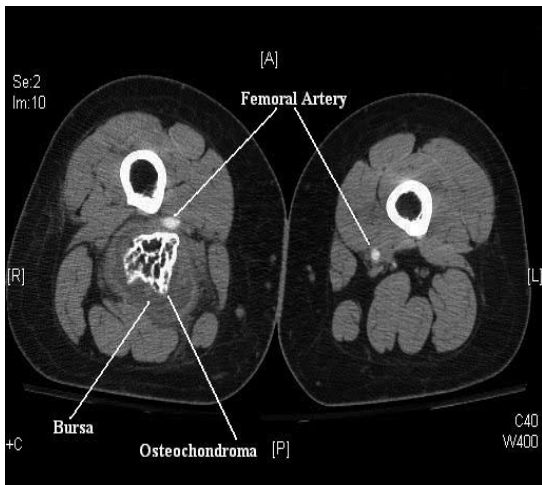


Figure 1 - The CT angiogram showing a large bursa around the tumor. CT - computed tomography.

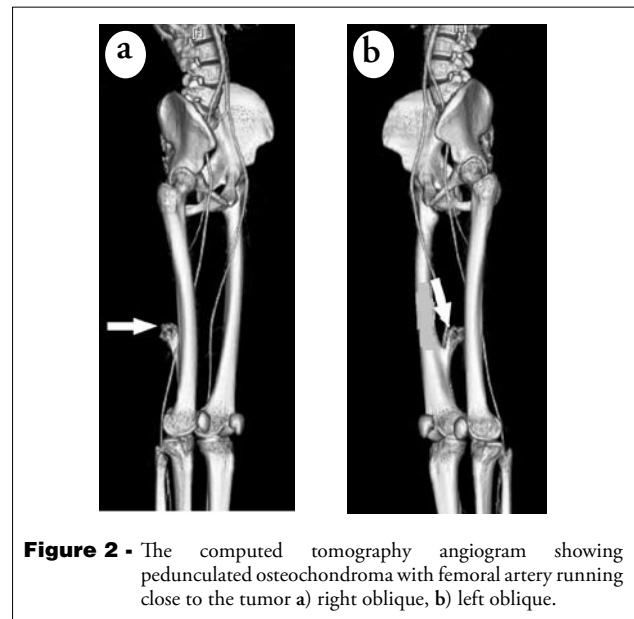


Figure 2 - The computed tomography angiogram showing pedunculated osteochondroma with femoral artery running close to the tumor a) right oblique, b) left oblique.

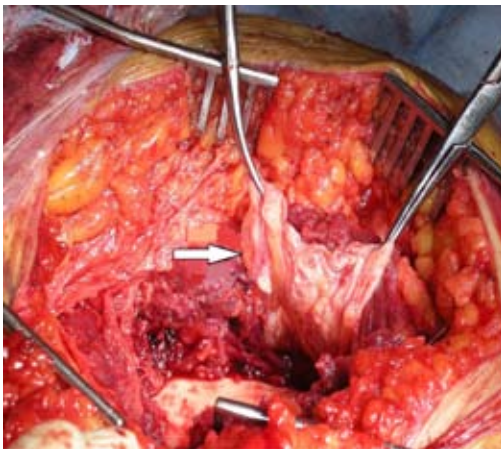


Figure 3 - Very large bursa around the tumor.

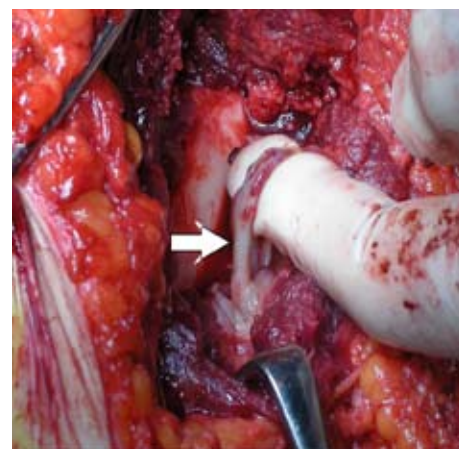


Figure 4 - Large vein inside the bursa showing abrasions and thrombosis.

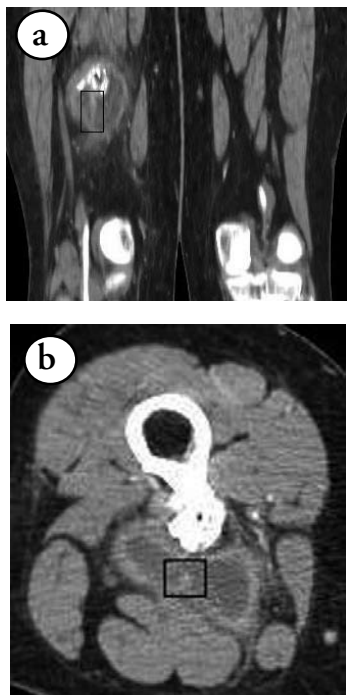


Figure 5 - Preoperative computed tomography angiogram showing the vein inside the bursa still patent a) coronal reformat, b) axial view.

The excised bursa showed features of chronic bursitis with foci of organized hematoma and granulation tissue. One and half years postoperative follow up did not reveal any new vascular compromise and no recurrence of the tumor.

Discussion. Osteochondromas are primary bone tumors, which are usually located in the distal femur, upper tibia, or upper humerus. Although the exact etiology of the tumor is not known, a peripheral portion of the physis is thought to herniate from the growth plate. This metaplastic cartilage grows to form the exostosis, which is connected to the bone by a thin stalk.⁴ Vascular complications associated with osteochondroma include vessel displacement, stenosis, occlusion, and pseudoaneurysm. Displacement of vessels by osteochondroma is common, but it is typically asymptomatic. Clinical symptoms in cases of vascular compromise include pain, swelling, and rarely claudication or a palpable pulsatile mass.⁵ Osteochondromas lying adjacent to an artery or vein can chronically abrade and ultimately lacerate the

vessel with normal movement or repetitive trauma. The predominance of popliteal artery involvement is related to the frequency of osteochondromas in this location as well as due to immobility of the vessel proximally at the adductor canal and distally by its branches. The abrasion is attributed to conversion of soft surface of the tumor's cap to ossified irregular surface at or near the skeletal maturity.⁶ In our patient, also the cap was irregular and ossified. Her symptoms started when she stood up from a squatting position. Probably sudden extension of the knee abraded and damaged the vein close to the tumor resulting in hematoma and thrombosis. She did not have any symptoms earlier, and so her osteochondroma was not diagnosed. If such tumor is detected close to a major vessel it should be operated urgently.⁷ The proximity of the intrabursal vein to the tumor's irregular surface abraded the vein. Since this vein was inside the bursa and was not a main branch of the deep venous system, the Doppler ultrasound and venography could not detect it.

In conclusion, a case of femoral osteochondroma intrabursal vein abrasion and thrombosis is reported that was presenting clinical signs of right lower limb DVT.

Acknowledgment. We wish to express our sincere gratitude to Dr. Nooruddin K. Moosa for his help on preparation, and proof reading of this paper.

References

1. Andrikopoulos V, Skourtis G, Papacharalambous G, Antoniou I, Tsolias K, Panoussis P. Arterial compromise caused by lower limb osteochondroma. *Vasc Endovascular Surg* 2003; 37: 185-190.
2. Murphey MD, Choi JJ, Kransdorf MJ, Flemming DJ, Gannon FH. Imaging of osteochondroma: variants and complications with radiologic-pathologic correlation. *Radiographics* 2000; 20: 1407-1434.
3. Hershey SL, Lansden FT. Osteochondromas as a cause of false popliteal aneurysms. Review of the literature and report of two cases. *J Bone Joint Surg Am* 1972; 54: 1765-1768.
4. Essadki B, Moujtahid M, Lamine A, Fikry T, Essadki O, Zryouil B. Solitary osteochondroma of the limbs. Clinical review of 76 cases and pathogenic hypothesis. *Acta Orthop Belg* 2000; 66: 146-153.
5. Smits AB, vd Pavoordt HD, Moll FL. Unusual arterial complications caused by an osteochondroma of the femur or tibia in young patients. *Ann Vasc Surg* 1998; 12: 370-372.
6. Ballaro A, Fox AD, Collin J. Rupture of a popliteal artery pseudo-aneurysm secondary to a fibular osteochondroma. *Eur J Vasc Endovasc Surg* 1997; 14: 151-152.
7. Vasseur MA, Fabre O. Vascular complications of osteochondromas. *J Vasc Surg* 2000; 31: 532-538.