

The handmade endoloop technique

A simple and cheap technique for laparoscopic appendectomy

Fabrettin Yildiz, MD, Alpaslan Terzi, MD, Sacid Coban, MD, Nazif Zeybek, MD, Ali Uzunkoy, MD.

ABSTRACT

الأهداف: المقارنة بين أسلوبين من أساليب استئصال الزائدة الدودية بالمنظار.

الطريقة: نقدم هنا وصفا لأسلوب جراحي معدل، وهو أسلوب العقدة الداخلية المصنوعة يدويا من أجل إغلاق قاعدة الزائدة الدودية. أُجريت هذه الدراسة، والتي يتوقع أن تحقق نجاحا على أيدي أربعة جراحين، في قسم الجراحة العامة – الكلية الطبية بجامعة حران، وبأكاديمية جولهان الطبية العسكرية – تركيا، خلال الفترة ما بين سبتمبر 2006م وحتى فبراير 2008م. وقد قدرنا مدى سلامة هذا النوع من الجراحة ومدى فاعليته في 98 حالة خطيرة من حالات الإصابة بالزائدة الدودية، وكانت على النحو التالي: 57 من المرضى في العقدة الداخلية المصنوعة يدويا و41 مريضا بأسلوب العقدة الداخلية على مدى 19 شهرا الماضية. وقد تم قياس كل من: زمن الجراحة، المضاعفات المحتملة حدوثها، الحاجة إلى مسكنات الألم، وكذلك تكلفة إجراء العملية في كل من المجموعتين. وقد تم إدراج أسعار العقدة الداخلية والعرض التي استخدمت من أجل التعامل مع استئصال الزائدة الدودية في إطار الأسعار الحالية، وتم تلخيصها في صورة العدد المستهلك لكل حالة، ثم جرى بعد ذلك مقارنتها. وتلا ذلك تحليلا للبيانات التي تم الحصول عليها باستخدام اختبار مناسب.

النتائج: يبلغ متوسط التكلفة التي يتحملها المريض عن غلق قاعدة الزائدة الدودية مقدارا 81 دولارا أمريكياً بالنسبة لاستئصال الزائدة الدودية بالمنظار بالعقد الداخلية، في حين لم تتجاوز التكلفة حدود 8 دولارات أمريكية عند استخدام الأسلوب الجراحي الذي تم وصفه في هذا المقال. وبشكل عام، لم تظهر فروق ذات دلالة إحصائية عند مقارنة المجموعتين فيما يتعلق بحدوث المضاعفات بعد إجراء العمليات، وزمن العمليات وكذلك الحاجة إلى المسكنات.

خاتمة: يتسم هذا الإجراء الجراحي بكونه بسيطاً وآمناً، إضافةً إلى كونه منخفض التكلفة.

Objectives: To compare 2 laparoscopic appendectomy techniques.

Methods: We describe a modified technique, the handmade endoloop technique, for closing the base of the appendix. This prospective study was carried out at Harran University Medical Faculty, Sanliurfa, and Gulhane Military Medical Academy, Ankara, Turkey from September 2006 to February 2008. We evaluated the safety and efficacy of the procedure in 98 acute appendicitis cases: 57 patients handmade endoloop patients, and 41 endoloop technique patients. Operative time, postoperative complications, need for analgesics, and procedure cost were measured for both groups. The endoloops and sutures used to manage appendectomy were listed at current prices, summarized as number consumed per case, and compared. Data were analyzed by appropriate test.

Results: The average price of material used for closing the base of appendix was 81 American Dollars (USD) for laparoscopic appendectomy with endoloop, and 8 USD for the technique described by this article. Overall, postoperative complications, operative time, and the need for analgesia did not show a statistical difference in comparing both groups.

Conclusion: This procedure is simple, safe, and cheap.

Saudi Med J 2009; Vol. 30 (2): 224-227

From the Department of General Surgery (Yildiz, Terzi, Uzunkoy), Harran University Medical Faculty, Sanliurfa, and the Department of General Surgery (Coban), Gaziantep University Medical Faculty, Gaziantep, and the Department of General Surgery (Zeybek), Gulhane Military Medical Faculty, Ankara, Turkey.

Received 28th October 2008. Accepted 5th January 2009.

Address correspondence and reprint request to: Dr. Fabrettin Yildiz, Department of General Surgery, Harran University Medical Faculty, Sanliurfa 63300, Turkey. E-mail: fabrettinyildiz@hotmail.com

Laparoscopic appendectomy is preferred by many surgeons due to numerous documented advantages of this approach. Studies have shown advantages of laparoscopic appendectomy to include precise operative diagnosis, lower morbidity, decreased intra-abdominal scarring, shortened length of stay, and fewer intraoperative and postoperative complications.¹⁻³ However, increased cost often is cited against the general use of laparoscopic appendectomy.⁴ The most important reason that contributes largely to the elevated cost of laparoscopic appendectomy is the disposable equipment used during the procedure. The use of the endoloop or endostapler, as disposable equipment, in laparoscopic appendectomy for closing the base of appendix is more common. To diminish the cost of laparoscopic appendectomy, several methods have been essayed, such as the one- or 2-trocar techniques,⁵ instrument-assisted knotting,⁶ and closure of the stump by clip applicator⁷ rather than endoloop suture or endostaplers. The objectives of the present study were to establish the feasibility of the closure of the appendicular stump by using a handmade Vicryl loop; to establish whether differences exist in the postoperative course, in comparison with those patients whose appendicular stump was closed with endoloop; and to compare the cost of both techniques and evaluate whether the use of a handmade Vicryl loop is a safe alternative for laparoscopic appendectomies. We carried out the following prospective study, because we believe that using the handmade loop knot, which has been used in many open procedures, is a safe method for closure of the appendiceal stump during laparoscopic appendectomy.

Methods. This prospective study was carried out at Harran University Medical Faculty, Sanliurfa and Gulhane Military Medical Academy, Ankara, Turkey from September 2006 to February 2008; and 98 consecutive laparoscopic appendectomies were performed. We consulted with the Chair of the local Research Ethics Committee of Harran University Medical Faculty on the procedures. The patients were verbally informed about the details, risks, and benefits of the technique, and consents were obtained under the supervision of Bioethics consultant in some cases. The choice of the approach was made by the operating surgeon with the approval of the patients. Patients in the study included one group of 57 patients (group I) who underwent laparoscopic appendectomy with a handmade endoloop technique for closing the base of the appendix. A second group included 41 patients (group II) who underwent laparoscopic appendectomy technique by using endoloop. All of the patients received the same preoperative antibiotics according to the institutional protocol. In both techniques, access

to the peritoneum was carried out and the peritoneum was opened in direct vision, than the 10-mm, reusable first trocar was placed in the subumbilical position. Two reusable 5-mm ports were placed in the left iliac fossa position and median suprapubic position. After the initial laparoscopic evaluation of the abdominal cavity, the appendicular mesentery was dissected meticulously by unipolar forceps. Ligation of the appendicular base was carried out using 3 endoloops (Ethicon Endosurgery, Cincinnati, Ohio, USA), placing 2 of them in the proximal portion of the appendicular base and one a few millimeters distally, in the endoloop group. In the other group, we formed a loop using no. 2.0 Vicryl as shown in **Figure 1**, and by pulling one end of the loop, the knot has slid down the base of the appendix. To form the loop, firstly, we made one short limb and one long limb. We formed a loop with the long limb and wrapped the limb 4 times around both limbs by passing posteriorly and then anteriorly. Then we passed the terminal end of the long limb inside the loop that we had formed beforehand. Finally, we tightened the loop. As no literature reports on the safety and the efficacy of the handmade endoloop, we examined the efficacy and safety of the handmade endoloop on the rubber material of several consistencies over 500 times and witnessed no slippage. While using the knot, it was easy to seat it correctly and slide. Once the knot is in place and tightened well, it does not unravel. This is inserted into the abdominal cavity, and the loop is moved over to the base of appendix, which was ligated by 3 manually made loops, placing 2 of them in the proximal portion of the appendicular base, and one a few millimeters distally. Then, in both groups, appendectomy was performed by cutting the appendix between the 2 proximal knots and the distal knot, using endoscopic scissors and retrieved through the umbilical

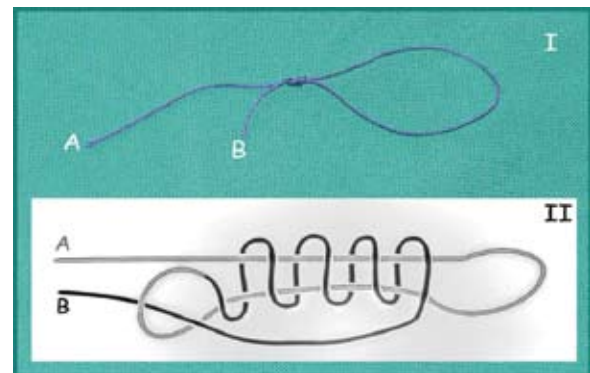


Figure 1 - When the suture is pulled from A, it slides down and ligates the base of the appendix. (I - photographic image of the “prepared-knot”, and II - graphical image of the preparation of the knot).

trocar site. Cost of the equipment, minutes of operative time, need for analgesics, intraoperative or postoperative complications were analyzed. In both techniques, we used reusable instruments for laparoscopic cases, except the endoloops and endocatch bags.

The results were analyzed with SPSS for Windows version 11.5 software (Chicago, Illinois, USA), and the differences between the groups were compared with the chi-square, and Mann-Whitney U test. Two sided p values <0.05 was regarded as statistically significant.

Results. During the 19 months period, 98 patients who underwent laparoscopic appendectomy for appendicitis were studied. Table 1 shows the demographic details and outcomes of both groups. Two patients in group I had a conversion to an open procedure; one for failure to progress, and one gangrenous base of appendix. Five of the specimens (13.5%) were normal on histological examination. The recorded complications included 2 patients who had perforated appendicitis with peritonitis. The young female required a laparoscopic drainage of interloop abscesses. This patient required prolonged hospitalization for 4 days, until afebrile status was achieved. The other patient had a wound infection at the umbilical trocar site, requiring a wound exploration for an organized abscess and was discharged after 72 hours of hospitalization and treated on an outpatient basis. In group II, 3 patients required conversion from laparoscopic to open, 2 due to dense adhesions secondary to prior operation, and one due to gangrenous base of appendix. Three of the specimens (7.3%) were normal on histological examination. One patient in group II developed an intraabdominal abscess, and percutaneous drainage of abscesses was achieved. The other recorded complications included 2 patients with superficial wound infections treated on an outpatient basis. There were no cases of stump blowout or cecal fistulae in either group. Laparoscopic appendectomy using endoloop incurred significantly more intraoperative equipment charge than group I.

Table 1 - Demographics and outcomes.

Variables	Group I n=57	Group II n=41	P-value
Age, years	29	32.5	0.122
Gender (Male/Female)	22/35	14/27	0.677
Median operating time (minutes)	44.3	43.8	0.718
Average hospital stay, days	2.3	2.1	0.139
Morbidity	2	3	0.647

There was no significant difference between groups.

In all cases of group II, 3 endoloops were applied on the appendiceal stump at a cost of 81 USD (27 USD x 3). In laparoscopic appendectomies with handmade endoloop procedures, only a single package of Vicryl ligatures-2.0 was enough to form the 3 loops, at a cost of 8 USD.

Discussion. It is reported that laparoscopic appendectomy has advantages such as accurate preoperative diagnosis, less wound infection, less need for postoperative analgesia, earlier discharge, earlier return to normal activities, and better cosmetic effect.^{3,8-11} However, laparoscopic operative procedures are still more expensive than open surgery, and this is one of the main drawbacks.^{4,11,12} The cost of laparoscopic appendectomy is based on the disposable equipment, such as endostaplers, endoloops, and trocars. In our study, we used 3 endoloops for closing the base of the appendix in group II at a cost of 81 USD. In group I, only a single package of Vicryl ligatures-2.0 was enough for closing the base of the appendix by 3 loops, at a cost of 8 USD. The cost was a significant difference between the groups. In some studies, it is concluded that one endoloop was as safe as using 2 or more if the appendix is inflamed minimally.¹³ Nevertheless, in most studies, 2 endoloops were placed at the base of the appendix, and another endoloop, clips, or ligature is used to ligate the appendix distal to the endoloops before dividing the appendix.^{7,14} In our study, we also preferred placing 2 ligatures in the proximal portion of the appendicular base, and one a few millimeters distally. The operating room time was similar between both groups, due to the similarity of the techniques. Moreover, the time spent for tying the loop was approximately 5 seconds. In addition, there were no significant differences in length of hospital stay and complication rates in both groups. As reported for endoloops in the literature,⁶ we also noticed no slippage in both groups during the intraoperative and postoperative periods, which could lead to complications, after precisely ligating the base of appendix in all cases.

The technique provided satisfactory results. The absence of any stump blowout or fistula, or any communication between the stump and an abscess in either group was in favor of their comparability in securing the stump. The small number of the study population forms the main limitation of this study. The lack of control cases operated on with open appendectomy may also be regarded as a limitation; however, significant cost advantage makes the handmade endoloop the preferred operative method.

In conclusion, laparoscopic appendectomy by closing the base of appendix using the handmade endoloop technique may be a more cost-effective technique,

potentially offsetting the cost difference between laparoscopic appendectomy and open appendectomy without any impact on surgical outcomes.

Acknowledgment. *We are grateful for the Ethical Consultation of Dr. Sahin Aksoy, Faculty of Medicine, Department of Medical Ethics and History of Medicine, Harran University, Sanliurfa, Turkey.*

References

1. Champault A, Polliand C, Mendes da Costa P, Champault G. Laparoscopic appendectomies: retrospective study of 2074 cases. *Surg Laparosc Endosc Percutan Tech* 2008; 18: 168-172.
2. Schick KS, Hüttl TP, Fertmann JM, Hornung HM, Jauch KW, Hoffmann JN. A critical analysis of laparoscopic appendectomy: how experience with 1,400 appendectomies allowed innovative treatment to become standard in a university hospital. *World J Surg* 2008; 32: 1406-1413.
3. Hay SA. Laparoscopic versus conventional appendectomy in children. *Pediatr Surg Int* 1998; 13: 21-23.
4. Ortega AE, Hunter JG, Peters JH, Swanstrom LL, Schirmer B. A prospective, randomized comparison of laparoscopic appendectomy with open appendectomy. Laparoscopic Appendectomy Study Group. *Am J Surg* 1995; 169: 208-212.
5. Konstadoulakis MM, Gomatos IP, Antonakis PT, Manouras A, Albanopoulos K, Nikiteas N, et al. Two-trocar laparoscopic-assisted appendectomy versus conventional laparoscopic appendectomy in patients with acute appendicitis. *J Laparoendosc Adv Surg Tech A* 2006; 16: 27-32.
6. Arcovedo R, Barrera H, Reyes HS. Securing the appendiceal stump with the Gea extracorporeal sliding knot during laparoscopic appendectomy is safe and economical. *Surg Endosc* 2007; 21: 1764-1767.
7. Hanssen A, Plotnikov S, Dubois R. Laparoscopic appendectomy using a polymeric clip to close the appendicular stump. *JSLS* 2007; 11: 59-62.
8. Konstantinidis KM, Anastasakou KA, Vorias MN, Sambalis GH, Georgiou MK, Xiarchos AG. A decade of laparoscopic appendectomy: presentation of 1,026 patients with suspected appendicitis treated in a single surgical department. *J Laparoendosc Adv Surg Tech A* 2008; 18: 248-258.
9. Romy S, Eisenring MC, Bettschart V, Petignat C, Francioli P, Troillet N. Laparoscope use and surgical site infections in digestive surgery. *Ann Surg* 2008; 247: 627-632.
10. Nguyen NT, Zainabadi K, Mavandadi S, Paya M, Stevens CM, Root J, et al. Trends in utilization and outcomes of laparoscopic versus open appendectomy. *Am J Surg* 2004; 188: 813-820.
11. Williams MD, Miller D, Graves ED, Walsh C, Luteran A. Laparoscopic appendectomy, is it worth it? *South Med J* 1994; 87: 592-598.
12. Cothren CC, Moore EE, Johnson JL, Moore JB, Ciesla DJ, Burch JM. Can we afford to do laparoscopic appendectomy in an academic hospital? *Am J Surg* 2005; 190: 950-954.
13. Beldi G, Muggli K, Helbling C, Schlumpf R. Laparoscopic appendectomy using endoloops: a prospective, randomized clinical trial. *Surg Endosc* 2004; 18: 749-750.
14. Lukish J, Powell D, Morrow S, Cruess D, Guzzetta P. Laparoscopic appendectomy in children: use of the endoloop vs the endostapler. *Arch Surg* 2007; 142: 58-61.

Related topics

Al-Saadi AS, Al-Wadan AH, Hamarnah SA, Amin H. Is abandoning routine peritoneal cultures during appendectomy justified? *Saudi Med J* 2007; 28: 1827-1829.

Hosseini SV, Haghbeen M, Yarmohammadi H, Lankarani KB, Kaviani MJ, Sharifzad HR. The therapeutic value of elective laparoscopic appendectomy in the management of chronic abdominal pain. *Saudi Med J* 2005; 26: 1482-1483.

Al-Bassam AA. Laparoscopic appendectomy in children. *Saudi Med J* 2005; 26: 556-559.