

Novel technique for the treatment of stress urinary incontinence

Early experience

Mahmoud O. Mustafa, MD, Bassem S. Wadie, MD.

ABSTRACT

الأهداف: تقييم كفاءة العلاقة الأمامية لجدار المهبل، وتعزيزها بشبكة البوليبيروبين في معالجة ضائقة عدم التحكم في البول (SUI).

الطريقة: خضعت 17 مريضة بمتوسط عمر 51.29 عاماً، تراوحت أعمارهن ما بين (27-73 عاماً) لعملية جراحية من أجل لعدم التحكم في البول (SUI)، خلال الفترة ما بين أغسطس 2006م وحتى أغسطس 2007م. من بين 17 مريضة، خضعت مريضتين في السابق لعملية تدخل جراحية لمضاد عدم التحكم في البول، بينما كانت حالة الباقيات أولية. تم استعمال علاقة جدار المهبل الأمامية والمعززة بشبكة البوليبيروبين كإجراء لعلاج عدم السيطرة على البول. بلغ متوسط فترة المتابعة 9.29 شهر، بمتوسط (4-16 شهراً).

النتائج: كان إجراء تركيب علاقة في جدار المهبل الأمامي وتعزيزها بشبكة البوليبيروبين ناجحة في 16 مريضة (94.1%)، 14 منهن شفوا واثنتان تحسنتا من الناحية السريرية. لم يكن هنالك تقرير عن حدوث إصابة في المبال، المثانة أو الأمعاء. أصيبت مريضة واحدة باحتباس في البول وقد شفيت منه بعد انخفاض حدة الغرز، بينما تعرضت مريضة أخرى لجرح منتن فوق العانة، وقد تمت معالجته بالمضادات الحيوية عن طريق الفم والأدوية المضادة للالتهابات. لم يتم اكتشاف وجود بقايا ملحوظة بعد طرح البول بعد العملية الجراحية (PVR).

خاتمة: تعتبر النتائج المبكرة لهذه التقنية مشجعة. فهي سهلة التعلم واقتصادية مع معدل نجاح جيد. يظهر تأكل الخالب على الأرجح نتيجة لوجود الغشاء المخاطي المهبل المتدخل. في المستقبل، يوصى بإجراء دراسة استيعابية تتضمن عدد كبير من المريضات الخاضعات لهذه التقنية مع فترة متابعة طويلة.

Objectives: To evaluate the efficacy of *in situ* anterior vaginal wall sling, reinforced with polypropylene mesh, in the treatment of stress urinary incontinence (SUI).

Methods: Seventeen patients with mean age of 51.29 years (range: 27-73) underwent surgery for SUI from August 2006 to August 2007 at Osmaniye State Hospital, Osmaniye, Turkey. Two out of 17 patients gave history of previous anti-incontinence surgical intervention, while the remaining were primary cases. *In situ* anterior vaginal wall sling, reinforced with semi-size monofilament polypropylene tape (size of the mesh was similar to size of *in situ* sling), was used as an anti-incontinence procedure. The mean follow-up period was 9.29 months (range: 4-16).

Results: *In-situ* anterior vaginal wall sling reinforced with polypropylene mesh was successful in 16 (94.1%) patients, 14 of them were cured, and 2 had clinical improvement. There was no report of preoperative urethral, bladder, or bowel injury. One patient developed postoperative urinary retention that resolved after decreasing the tension of the suspension sutures, and one patient had suprapubic wound sepsis treated by oral antibiotics and anti-inflammatory drugs. No postoperatively significant post-voiding residue was detected.

Conclusion: The early results of this technique are encouraging. It is easy to learn, economical, with a good success rate. Urethral erosion is less likely to occur due to the presence of intervening vaginal mucosa. In the future, a prospective study recruiting a larger number of patients undergoing this technique with long-term follow-up is recommended.

Saudi Med J 2009; Vol. 30 (2): 234-237

From the Urology Department (Mustafa), Osmaniye State Hospital, Osmaniye, Turkey, and the Urology and Nephrology Center (Wadie), Mansoura University, Mansoura, Egypt.

Received 11th November 2008. Accepted 5th January 2009.

Address correspondence and reprint request to: Dr. Mahmoud Mustafa, Department of Urology, Izmir Atatürk Teaching Hospital, Izmir, Turkey. Tel. +90 (232) 2454545. Fax. +90 (232) 2431530. E-mail: dr_mahmoud68@yahoo.com

Tension-free vaginal tape (TVT) represents the well-established surgical procedure for the treatment of stress urinary incontinence (SUI). The technique described by Ulmsten¹ in 1996, which is based on a midurethral Prolene tape support, is accepted worldwide as an easy to learn, effective, and safe surgical technique with low incidence of complications.¹⁻⁵ However, the reported failure rate following TVT procedure was 5-15%, and other possible alternative techniques were developed.^{2,3,5,6} Another well-known complication is a bladder outlet obstruction, which has a negative influence on patients rehabilitation.^{2,3,5,7} Bladder penetration, bowel injury, intra-operative bleeding, and post-operative infection^{2,3,5-9} are examples of reported complications. In one of the largest studies, Kuuva et al³ reported that the percentages of postoperative complications after anti-incontinence surgery were; 2.3% for urinary retention, 3.8% for bladder perforation, 0.07% for urethral erosion, and 0.8% for wound infection. Similarly, Neuman et al⁶ reported 8% of bladder perforation, 5% of voiding dysfunction, 2.7% of therapeutic failures after TVT procedure. The place of urodynamic study in patients with pure SUI is not universally accepted. While some studies emphasize its importance,^{10,11} others are not in support of its routine use before anti-incontinence surgery.^{11,12} In this study, the efficacy of a new surgical technique utilizing *in situ* anterior vaginal wall sling, reinforced with polypropylene mesh for the treatment of pure SUI is evaluated.

Methods. This prospective trial included 17 female patients with a mean age of 51.29 years (range: 27-73) who were planned for surgery due to SUI from August 2006 to August 2007, at Osmaniye State Hospital, Osmaniye, Turkey. The diagnosis of SUI was based on positive stress test, and the presence of urethral hypermobility confirmed by cotton swab test. The SUI was defined as involuntary leakage on effort, exertion, sneezing or coughing, and urge incontinence was defined as the complaint of involuntary leakage accompanied by, or immediately preceded by urgency.¹³ Urethral hypermobility was assessed with Q-tip test. The degree of cystocele was assessed according to the Baden-Walker prolapse classification.¹⁴ Cystocele of various degrees were observed in 10 patients; grade III in 2, grade II in 5, and grade I in 3 patients. Urodynamics were performed only for 7 (41.2%) patients who did not define pure stress incontinence. All patients included in the study were diagnosed to have pure stress incontinence and showed no benefit of anti-cholinergic therapy. Any patient that suffered from urodynamically documented urge incontinence was excluded from the study. No patient received preoperative pelvic floor muscle training for the

treatment of SUI. Two out of 17 patients gave a history of previous anti-incontinence surgical intervention. One patient underwent a retropubic procedure of unknown nature, and another one underwent transobturator tension-free vaginal tape. All patients were informed about the operation and consent was obtained from the patients. Ethical approval was obtained from the hospital for this study. The operation was performed under spinal or general anesthesia. In the lithotomy position, 18 F Foley catheter was inserted to evacuate the bladder. Then, a placard-shaped incision was made in the anterior vaginal wall (Figure 1), and dissection of the vaginal flap was carried out to prepare midurethral *in situ* anterior vaginal wall sling (Figure 2). The length of midline incision at anterior vaginal wall was determined according to the degree of cystocele. The dissection at the lateral side of the *in situ* sling was carried out until the index finger could be easily felt from the suprapubic area. Semi-size monofilament polypropylene mesh (I-STOP CL Medical, France) was prepared, then at the lateral side of the placard incision, 2 suspension sutures of 1/0 polypropylene were inserted in the flap and the mesh (Figure 3), and passed lateral to the urethra. Two fixation sutures were placed at the lower and upper edges of the *in situ* sling to keep the mesh over the sling (Figure 3). A small transverse incision of 4-5 cm was made over the symphysis pubis without cutting the rectus fascia. Before fixation of the suspension sutures to the symphysis pubis periosteum, the bladder was filled with 250-300 ml isotonic solution, and manual pressure was applied to the suprapubic area to test for leakage, thus adjusting the tension of the sutures. Then, closure of the placard incision followed over the *in situ* sling. Per-operative cystoscopy was performed in each patient to exclude urethral or bladder injury. All patients were hospitalized for 24-48 hours. An 18 F Foley catheter was left for 7 days. The vaginal sponge was placed at the end of the operation, and removed 24 hours later. Operative time varied from 45-90 minutes (mean 60 minutes). Postoperatively, patients were advised to avoid sexual intercourse and carrying heavy weights for 2 months. The mean follow up period of patients was 9.29 months (range: 4-16). The postoperative follow up schedule was 1, 3, 6 months, and then every 6 months. It included clinical history for possible urinary leakage, physical examination, stress test, and estimation of the post-voiding residue (PVR) volume (50 ml or less was considered insignificant). Real abdominal ultrasound was used to measure the PVR during the postoperative follow up. Cure of SUI after the procedure was defined as the absence of complaint of leakage, and the absence of leakage on stress testing. Improvement was defined as no urine loss on stress plus patients report of some leakage but overall satisfaction. Therapeutic failure was defined as sustained SUI.

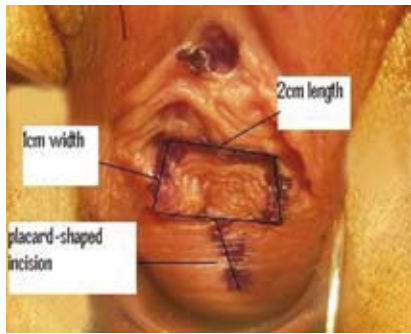


Figure 1 - Schematic illustration of placard-shaped incision at the anterior vaginal wall showing the dimensions of the *in situ* sling, which will be prepared after dissection.

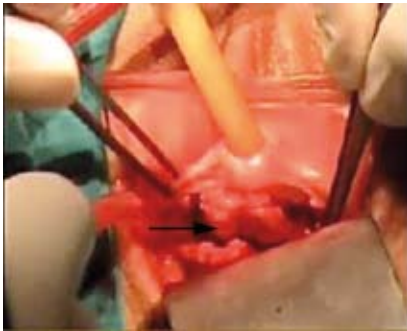


Figure 2 - *In situ* sling (arrow) prepared from the anterior vaginal wall.

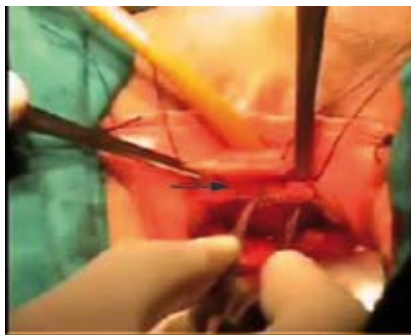

Figure 3 - Polypropylene mesh (arrow) supporting the midurethral *in situ* sling with 2 suspension sutures at the lateral sites

Results. The surgical technique used in this study was successful in 16 (94.1%) patients, as 14 of them were cured, and 2 patients had clinical improvement. The ages of these 2 patients were 73 and 69 years, and the later was diabetic. One patient (5.8%) did not benefit from the surgery (64-year-old, diabetic, body mass index [BMI]=44.98). One patient (5.8%) had urinary retention that was not resolved after a further 5 days of catheterization, therefore, the tension of suspension sutures was relieved in the theater under

anesthesia. This resulted in spontaneous voiding shortly after one day of catheterization. No intra-operative bleeding, bladder or intestinal penetration was observed. Two patients (11.7%) had asymptomatic vaginal tape erosion detected during the gynecological examination at the first month postoperatively, and a conservative approach (watchful waiting) was adopted. One patient had temporary urgency without urge incontinence, starting at the third week postoperative, and improved on anti-muscarinic for 3 weeks. There was no clinically significant PVR urine detected by real time abdominal ultrasound after the catheter removal. One patient had wound sepsis in the form of suprapubic tenderness and redness, which was treated by oral antibiotics and anti-inflammatory drugs for one week.

Discussion. The integral theory of incontinence and the basis of midurethral sling procedure was developed by Petros et al.¹⁵ The current view in incontinence surgery is in favor of pubovaginal fascial sling over traditional abdominal colposuspension techniques, as the results of the former are much better long term regarding efficacy, morbidity, hospital stay, and cost to public health care.¹⁶⁻¹⁸ However, many publications reported no significant differences between various midurethral sling procedures.^{19,20} In a recent study, we reported encouraging results using the placard technique, utilizing *in situ* sling of anterior vaginal wall for the treatment of SUI, especially in patients with average BMI.²¹ In the current description, a slight modification by supporting the *in situ* vaginal sling with semi-size mesh was adopted, aiming to increase the efficacy of the surgical procedure. Cost effectiveness and low risk of urethral or bladder erosion are the most important potential advantages of this technique. The length of the mesh used in our technique is 2 cm (>15 times less than the length of the same mesh [I-STOP] used for TVT). Urethral erosion is theoretically less likely to occur due to the presence of vaginal mucosa between the mesh and urethra. The success of curing SUI by this technique is also related to the good feasibility of cystocele correction. Cystocele was reported to be one of high risk factors for persistence of stress incontinence.²² Modest long-term success is one of the dilemmas that face the patients undergoing anti-incontinence surgery. The overall 5-year cure rate for anti-incontinence surgery was reported to be 76.8%.^{23,24} With this technique, we hope that long term success is achieved as the urethra is supported by the *in situ* sling and semi-size mesh, and no relaxation in the suspension sutures is expected. The patient who did not benefit from the surgery was diabetic and obese (BMI=48.98). Obesity and co-morbid diseases are among factors (high BMI, urge incontinence, low leak point pressure, high grade

incontinence, severe grade of cystocele) that may have a negative impact on cure rate after anti-incontinence surgery.^{22,23}

Preoperative PVR determination is recommended for any women with voiding dysfunction or history of recurrent urinary tract infection.^{25,26} In our study, all patients (7 patients) who underwent urodynamic evaluation had no detected PVR, and the remaining females had no history of inadequate bladder emptying, so it is difficult to comment on the effect of preoperative PVR volume on the clinical outcomes of the technique. Due to the low number of patients included in the study, it is difficult to evaluate the statistical correlation between the failure of the technique and the development of certain complications (urgency, retention) with certain risk factors such as age, BMI, parity, menopausal status, diabetes mellitus, the presence of cystocele, and previous incontinence surgery. The use of this procedure in secondary cases of SUI seems to be acceptable. Out of 2 patients, who were "re-do", both were cured. However, performing this technique for secondary cases may carry some difficulties in preparing the *in situ* sling due to fibrosis because of the previous surgeries. To reduce the rate of vaginal erosion, enough dissection at the lateral side of the *in situ* sling is recommended. The high rate of vaginal erosion in our study may be due to the low number of patients who were included in the study.

In conclusion, early therapeutic results of this technique are encouraging. The cost-effectiveness and the low risk of urethral erosion are the most important considerations of this technique. Long-term success is expected, hoping that relaxation of the suspension sutures is less likely. Long term follow up and larger sample size are required to enable drawing solid conclusions regarding this operative procedure.

References

- Ulmsten U, Henriksson L, Johnson P, Varhos G. An ambulatory surgical procedure under local anesthesia for treatment of female urinary incontinence. *Int Urogynecol J Pelvic Floor Dysfunct* 1996; 7: 81-85.
- Olsson I, Kroon U. A three-year postoperative evaluation of tension-free vaginal tape. *Gynecol Obstet Invest* 1999; 48: 267-269.
- Kuuva N, Nilsson CG. A nationwide analysis of complications associated with the tension-free vaginal tape (TVT) procedure. *Acta Obstet Gynecol Scand* 2002; 81: 72-77.
- Paraiso MF, Muir TW, Sokol AI. Are midurethral slings the gold standard surgical treatment for primary genuine stress incontinence? *J Am Assoc Gynecol Laparosc* 2002; 9: 405-407.
- Waetjen LE, Subak LL, Shen H, Lin F, Wang TH, Vittinghoff E, et al. Stress urinary incontinence surgery in the United States. *Obstet Gynecol* 2003; 101: 671-676.
- Neuman M. Tension-free vaginal tape bladder penetration and long-lasting transvesical Prolene material. *J Pelvic Med Surg* 2004; 10: 307-309.
- Neuman M. Low incidence of post-TVT genital prolapse. *Int Urogynecol J Pelvic Floor Dysfunct* 2003; 14: 191-192.
- Neuman M. Post tension-free vaginal tape voiding difficulties-prevention and management. *J Pelvic Med Surg* 2004; 10: 19-21.
- Neuman M. Trans vaginal tape readjustment after unsuccessful tension-free vaginal tape operation. *Neurourol Urodyn* 2004; 23: 282-283.
- Summitt RL Jr, Stovall TG, Bent AE, Ostergard DR. Urinary incontinence: correlation of history and brief office evaluation with multichannel urodynamic testing. *Am J Obstet Gynecol* 1992; 166: 1835-1840.
- Weidner AC, Myers ER, Visco AG, Cundiff GW, Bump RC. Which women with stress incontinence require urodynamic evaluation?. *Am J Obstet Gynecol* 2001; 184: 20-27.
- Lemack GE, Krauss S, Litman H, FitzGerald MP, Chai T, Nager C, et al. Normal preoperative urodynamic testing does not predict voiding dysfunction after Burch colposuspension versus pubovaginal sling. *J Urol* 2008; 180: 2076-2080.
- Abrams P, Cardozo L, Fall M, Griffiths D, Rosier P, Ulmsten U, et al. The standardisation of terminology of lower urinary tract function: report from the Standardisation Sub-committee of the International Continence Society. *Neurourol Urodyn* 2002; 21: 167-178.
- Baden WF, Walker TA. Statistical evaluation of vaginal relaxation. *Clin Obstet Gynecol* 1972; 15: 1070-1072.
- Petros PE, Woodman PJ. The Integral Theory of continence. *Int Urogynecol J Pelvic Floor Dysfunct* 2008; 19: 35-40.
- Appell RA. The use of bone anchoring in the surgical management of female stress urinary incontinence. *World J Urol* 1997; 15: 300-305.
- Coucke K, Kesteloot K. A comparison of health care financing policies for incontinence products in European countries. *Eur Urol* 2000; 37: 36-42.
- Albo ME, Richter HE, Brubaker L, Norton P, Kraus SR, Zimmern PE, et al. Burch colposuspension versus fascial sling to reduce urinary stress incontinence. *N Engl J Med* 2007; 356: 2143-2155.
- Abdel-Fattah M, Barrington JW, Arunkalaivanan AS. Pelvic pubovaginal sling versus tension-free vaginal tape for treatment of urodynamic stress incontinence: a prospective randomized three-year follow-up study. *Eur Urol* 2004; 46: 629-635.
- Tseng LH, Wang AC, Lin YH, Li SJ, Ko YJ. Randomized comparison of the suprapubic arc sling procedure vs tension-free vaginal taping for stress incontinent women. *Int Urogynecol J Pelvic Floor Dysfunct* 2005; 16: 230-235.
- Mustafa M, Wadie BS. Placard-shaped in situ vaginal wall sling for the treatment of stress urinary incontinence. *Int J Urol* 2006; 13: 132-134.
- Paick JS, Cho MC, Oh SJ, Kim SW, Ku JH. Factors influencing the outcome of mid urethral sling procedures for female urinary incontinence. *J Urol* 2007; 178: 985-989.
- Doo CK, Hong B, Chung BJ, Kim JY, Jung HC, Lee KS, Choo MS. Five-year outcomes of the tension-free vaginal tape procedure for treatment of female stress urinary incontinence. *Eur Urol* 2006; 50: 333-338.
- Chêne G, Amblard J, Tardieu AS, Escalona JR, Viallon A, Fattouh B, et al. Long-term results of tension-free vaginal tape (TVT) for the treatment of female urinary stress incontinence. *Eur J Obstet Gynecol Reprod Biol* 2007; 134: 87-94.
- Ghoniem G, Stanford E, Kenton K, Achari C, Goldberg R, Mascarenhas T, et al. Evaluation and outcome measures in the treatment of female urinary stress incontinence: International Urogynecological Association (IUGA) guidelines for research and clinical practice. *Int Urogynecol J Pelvic Floor Dysfunct* 2008; 19: 5-33.
- Thüroff J, Abrams P, Andersson KE, Artibani W, Chartier-Kastler E, Hampel C, et al. Guidelines on Urinary Incontinence. *European Association of Urology (EAU) Guidelines* 2008: 5.