

# Seven years experience of bronchogenic cysts

Soner Gursoy, MD, Ahmet Ucvet, MD, Ali A. Ozturk, MD, Ahmet E. Erbaycu, MD, Oktay Basok, MD, Nur Yucel, MD.

## ABSTRACT

**الأهداف:** كشف النتائج السريرية، الإشعاعية والجراحية للأكياس القصيبية.

**الطريقة:** أجريت هذه الدراسة الإستيعادية على 28 مريض الذين تم تشخيص حالتهم (بكيس قصيبي)، وذلك عن طريق فحص الأنسجة، وتقييمهم بواسطة العمر، الجنس، الأعراض والعلامات الإشعاعية والسريرية، إجراءات العلاج الجراحي، والمضاعفات بعد العملية. وقد تمت هذه الدراسة خلال الفترة مابين يناير 2000 وحتى يونيو 2007م، المستشفى التعليمي، أزمير - تركيا.

**النتائج:** كان هنالك 12 أنثى و 16 ذكر، وبلغ متوسط العمر 45.3 (25-73) عاماً. كانت الأكياس موجودة في النسيج الحشوي الرئوي لدى 53.5%، وفي الحيزوم لدى 43%، وفي داخل الصدر غير متعلق بالرئتين لدى 3.5%. لم يكن هنالك صلة بين الموقع الأكياس والجنس المريض ( $p=0.276$ )، وبين موقع الأكياس ووجود الأعراض ( $p=0.409$ ). كانت أكثر الأعراض تكراراً هي ضيق في التنفس وألم الصدر. كان هناك التهاب في الأكياس لدى 11%، وسليمة لدى 89%. بلغ متوسط قطر الأكياس 6.18/2-12. أجريت علمية الاستئصال الكامل عن طريق شق الصدر لجميع المرضى. بلغ متوسط فترة المتابعة 36 شهراً، ولم يكن هنالك أي حالة وفاة. ظهرت بعض المضاعفات البسيطة بعد العملية الجراحية لدى ثلاثة مرضى فقط.

**خاتمة:** قد تكون الأشعة لوحدها غير كافية لتشخيص الأكياس القصيبية في جميع المرضى. يقترح التدخل الجراحي المبكر من أجل التشخيص الدقيق ومنع صعوبات العملية الجراحية والمضاعفات.

**Objectives:** To reveal the clinical, radiological, and surgical results of bronchogenic cysts.

**Methods.** Patients that underwent surgical procedure between January 2000 and June 2007, at Izmir Dr. Suat Seren Chest Disease and Thoracic Surgery Training Hospital, Izmir, Turkey with a radiological diagnosis of bronchogenic cyst were assessed retrospectively. Patients with confirmed histopathologically bronchogenic cyst (n=28) were evaluated for age, gender, symptoms, clinical and radiological signs, procedure of surgical treatment, and post-operative complications.

**Results:** There were 12 females, 16 males, and the mean age was 45.3 (25-73) years. Cysts were located at the pulmonary parenchyma in 53.5%, at the mediastinum in 43%, and at the intrathoracic extrapulmonary in 3.5%. There was no relation between localization and gender ( $p=0.276$ ), and localization and the presence of symptoms ( $p=0.409$ ). Frequently seen symptoms were dyspnea and chest pain. Cysts were infected in 11%, and intact in 89%. The average diameter of the cysts was 6.18 cm (2-12). Surgical complete resection was performed via thoracotomy in all patients. Mean follow-up time was 36 months, and there was no death. Minor postoperative complications occurred in 3 patients.

**Conclusion:** Radiology alone may not be enough for diagnosis of bronchogenic cysts in all patients. Early surgical intervention is suggested for the exact diagnosis and prevention of operative difficulties and complications.

*Saudi Med J 2009; Vol. 30 (2): 238-242*

*From the Departments of Thoracic Surgery (Gursoy, Ucvet, Ozturk, Basok), Chest Disease (Erbaycu), and Pathology (Yucel), Izmir Dr. Suat Seren Chest Disease and Thoracic Surgery Training Hospital, Izmir, Turkey.*

*Received 9th August 2008. Accepted 31st December 2008.*

*Address correspondence and reprint request to: Dr. Soner Gursoy, 2040/7 Sokak Albatros 10 Giris 4 D: 47, Mavisehir, Bostanli 35540, Izmir, Turkey. Tel. +90 (532) 3532403. Fax. +90 (232) 4587262. E-mail: grssooner@gmail.com*

**B**ronchogenic cysts are formed by the abnormal branching of the tracheobronchial tree between 3 and 6 weeks of the embryonic period. It is a rare congenital abnormality with an incidence of 1/42,000.<sup>1</sup> Cysts formed in the early period of gestation are usually located in the mediastinal, while those formed later are located intraparenchymal.<sup>2</sup> A frequently seen localization is the inner part of the thorax; wide and heterogenous localization may be seen at the head, neck, retroperitoneal area, mucosa of stomach, shoulder, tongue, and subcutaneous tissue.<sup>3-5</sup> In a large series in the literature, adult patients are usually symptomatic,

and they suffer chest pain and dyspnea, caused by direct compression of the tissues. In symptomatic cysts, surgical excision is preferred because of the lower incidence of complications. In asymptomatic patients, a decision should be made after the diagnosis, on whether surgical resection should be performed or not.<sup>6,7</sup> In this study, we report our experience with bronchogenic cyst with the evaluation of patients' characteristics, surgical indications, results of treatment, and follow up.

**Methods.** Patients radiologically diagnosed with bronchogenic cyst pre-operatively, and who underwent operation at Izmir Dr. Suat Seren Chest Disease and Thoracic Surgery Training Hospital, Izmir, Turkey between January 2000 and June 2007, were included in the study. The study was approved by the hospital ethics committee, and informed consent was obtained from all patients. Of 34 patients, histopathological confirmation was achieved in 28 patients; those not confirmed by histopathology were excluded. Precise diagnosis confirmed perforated hydatid cyst in 3, infected air cyst in 2, and lung abscess in one of the other 6 patients. On histopathology, bronchogenic cyst was defined as a cystic mass containing mucus and ciliary columnar bronchial epithelium in the inner side. Standard chest radiography and thorax CT was performed in all patients. The sizes of the cysts were calculated using measurements of thorax CT. A cyst being surrounded with visceral pleura was accepted as an intraparenchymal cyst and others as extraparenchymal. Patients were classified according to localization to intraparenchymal and mediastinal groups. The age, gender, symptoms, clinical and radiological findings, procedure of surgical treatment, and post-operative complications were evaluated.

Statistica version 5.1 software (StatSoft Inc., USA) was used for statistical analysis. Fisher's exact test was used for the comparison of frequencies and a difference of  $p < 0.05$  was accepted to be statistically significant.

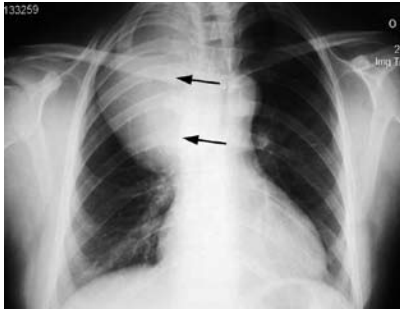
**Results:** Of 28 patients, 16 (57%) were male and 12 (43%) were female. The mean age was  $45.33 \pm 14.19$  (25-73) years. Eleven (39%) patients were smokers. The percentage of smokers was 17% in females, and 56% in males. Twenty patients out of 28 (71.4%) were symptomatic, and they usually suffered from dyspnea and chest pain. Ten (35.7%) patients had one complaint, and other 10 (35.7%) had more than one. The frequencies of symptoms are shown in Table 1. The occurrence period of the symptoms varied between one week and 5 years. The diagnosis was achieved coincidentally in 8 asymptomatic patients. No significant relation was detected between the presence of the symptoms and localization of the cysts ( $p = 0.409$ ). Cysts were located in the pulmonary parenchyma in 15

(53.5%), in the mediastinum in 12 (43%) (Figures 1 & 2), and in the intrathoracic extrapulmonary region in one (3.5%) patient. This patient was considered with the mediastinal group due to similar clinical findings and surgical approach. The localization was the intraparenchymal region in 43% ( $n = 7$ ) of males, and 53% ( $n = 8$ ) of females. Fifteen cysts inside the pulmonary parenchyma, were in the right upper lobe in 4 (14.3%), in the left upper lobe in 3 (10.7%), in the left lower lobe in 4 (14.3%), and in the right lower lobe in 4 (14.3%). Twelve cysts were located in the mediastinum, and the other between the lower lobe and the diaphragm. There was no relation between gender and localization ( $p = 0.276$ ). Of 28 cysts, 25 (89.3%) were intact, and 3 (11%) were infected (Figure 3). All infected, and 17 (60.7%) intact lesions had one or multiple symptoms, but there was no relation between symptoms and infection ( $p = 0.536$ ). All patients were evaluated with a thorax CT, and it was found that 96% ( $n = 27$ ) of the patients had unilocular, and 4% ( $n = 1$ ) had bilocular cystic structure. There was air-fluid level in 2 (7%) patients with evidence of infection and distortion at the lower third part of the esophagus in one patient, who had localization at the mediastinum. There were 4 tracheobronchial communications of 15 intraparenchymal located cysts (Table 2). The average cyst diameter was  $6.18 \pm 2.88$  (2-12) cm. Surgical resections were carried out by standard thoracotomy incision. The surgical method used according to the location, operative findings, and complications are shown in Table 3. All of the cysts were resected completely. The methods of cauterization or ablation were not used. Adhesions between cysts and pleura of surrounding tissues were removed, without harming the surrounding tissues. The mean postoperative period in hospital was  $6.6 \pm 2.8$

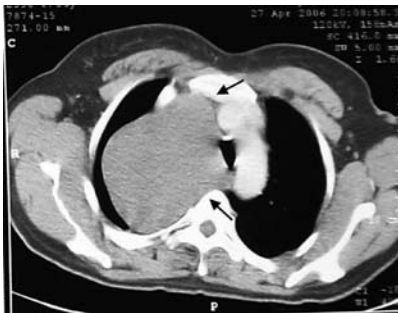**Table 1** - Clinical characteristics of patients with bronchogenic cysts.

Clinical characteristics	Mediastinal (n=13)	Intrapulmonary (n=15)	Significance
Average age, years	$43.77 \pm 14.03$	$46 \pm 14.50$	NS
Gender, M/F	8/4	7/8	NS
Average size, cm	$6.15 \pm 2.34$	$6.20 \pm 3.38$	NS
Symptomatic (%)	8 (61.5)	12 (80)	NS
<i>Presenting symptoms</i>			
Cough	1	5	
Pain	5	7	
Dyspnea	2	2	
Fever	-	3	
Hemoptysis	-	1	
Sputum expectoration	-	2	
Tachycardia	4	-	

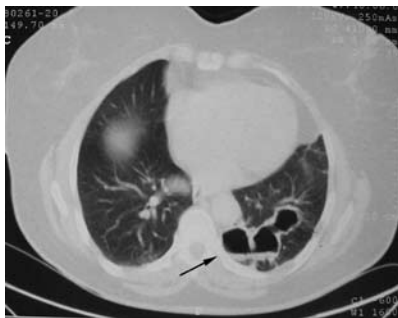Data are expressed as mean $\pm$ SD, NS - non significant



**Figure 1** - Roentgenogram of the chest demonstrates a huge bronchogenic cyst of the mediastinum.



**Figure 2** - Huge mediastinal bronchogenic cyst compresses the mediastinal structures and right lung.



**Figure 3** - Computerized tomography of a patient with an air-fluid level in an infected bronchogenic cyst.

(4-14) days. Postoperative complications were seen in 3 (11%) patients, while there was no mortality. In 2, infection of the incision site was treated conservatively. The last one, with a longer air leakage, was discharged on the fourteenth day, after pneumoperitoneum. The mean follow-up time was 36 months (2-72 months) and there was no death. In this period, 2 patients were hospitalized due to complications. The first one was admitted with breathlessness and treated with medical drugs. The second one had a pneumothorax on the twelfth postoperative month and was treated by a tube thoracostomy. None of the others suffered any symptoms or recurrence.

**Table 2** - Radiological and pathological findings.

Cyst characteristics	Mediastinal (n=13)	Intrapulmonary (n=15)
Unilocular	13	14
Multilocular	-	1
Evidence of infection	-	2
Rupture/intact	0/13	3/11
Tracheobronchial communication	0	4

**Table 3** - Operative procedures, findings, and complications.

Operative parameters	Mediastinal (n=13)	Intrapulmonary (n=15)
<i>Procedures</i>		
Thoracotomy	13	15
Lobectomy	-	5
Segmentectomy	-	1
Wedge resection	1	6
Excision	11	3
Mediastinoscopic excision	1	-
<i>Operative findings</i>		
Adhesion to adjacent tissue	8	-
Pleural adhesion	-	12
<i>Complications</i>		
Intra-operative	-	-
Post-operative	1	2

**Discussion.** The frequently seen localization for bronchogenic cysts is the intraparenchymal area. However, there are some series in which mediastinal localization is dominant. Mediastinal bronchogenic cysts comprise 5-10% of all mediastinal tumors, and 50-60% of all mediastinal cystic pathologies.<sup>6,8</sup> Chest pain is the major symptom.<sup>7,9,10</sup> In a serial of 17 patients that underwent surgical treatment, there were 16 adults and one child, and 11 were located in the mediastinum, and the other 6 were located in the pulmonary parenchyma. The frequency of being symptomatic was 29.4% and were generally the ones in whom cysts were located intrapulmonary.<sup>6</sup> In this serial, the incidence of intraparenchymal localization is higher than the others. It was interesting that one of the bronchogenic cysts was located intrathoracic, extrapulmonary.

Bronchogenic cysts may cause various symptoms and complications despite their benign structure. Adult patients usually have symptoms. Most of the asymptomatic patients have some symptoms at the time of diagnosis.<sup>6,8,11</sup> The percentage of the symptomatic patients in our serial was 71.4%, where frequently seen symptoms were chest pain and dyspnea. There was no significant relation between the presence of the symptoms and localization of the cysts. In a serial of 22

patients, 91% were symptomatic and the preoperative complications were infection in the lung, in the cyst, and dysphagia due to esophageal compression. All the cysts were completely excised, and there were no postoperative or late complications or recurrence.<sup>9</sup>

Complications of the bronchogenic cysts are not rare. Mediastinal cysts cause complications, generally because of compression to the surrounding tissues. Infection may be seen in intraparenchymal cysts due to their bronchial connections. Cysts may perforate the trachea and pleural area.<sup>12</sup> Pneumothorax caused by pleuritis and hemoptysis may also be seen.<sup>13</sup> We observed findings of infection in 3 patients with intraparenchymal localization. It was important to distinguish lung abscess, complicated hydatid cyst, and infected bullae in these patients. We did not meet any of other complications in this patient serial.

Preoperative diagnosis is made by chest radiography and CT, and recently by MRI. Chest radiography may direct us to a tumor, but it is inefficient to make a differential diagnosis, and to recognize the characteristics of the lesion. Though CT is a more useful method to reveal the localization and characteristics of the cyst, the rate of the accurate diagnosis is lower (45-61%).<sup>6,11</sup> It was confirmed by the operation findings in this serial, that the rate of the accurate diagnosis by CT was 82.4%. Most of the CT appearance of the bronchogenic cysts may lead a lower level of Hounsfield unity (HU [-20, +20]). Rarely, the mucoid content of the cyst may cause higher levels of HU, and it may be misdiagnosed as a solitary mass.<sup>14</sup> Chest radiography is generally ineffective for accurate preoperative diagnosis, while diagnosis is possible with 69.2% of CT scans, and 100% of MRI scans. Magnetic resonance imaging is very useful for qualitatively diagnosing the mediastinal tumors as cystic or solid.<sup>6</sup> All the patients in the serial were evaluated with a thorax CT. Six of 34 patients with a preoperative radiological diagnosis of bronchogenic cyst could not be confirmed in operation, and they were excluded. In a serial of 33 patients, the average diameter was 5.7 (2-16) cm, where cysts were unilocular in 31, bilocular in one and multilocular in one patient.<sup>7</sup> In the present serial, the average diameter and the unilocular presentation were similar, and there was air-fluid level in 7%.

The major treatment is surgical resection.<sup>7,8,12</sup> There is a tendency to perform surgery in symptomatic patients. However, there is always a possibility of being symptomatic for asymptomatic patients, and of malign transformation of cysts.<sup>8,11,15</sup> In the serial of Kanemitsu et al,<sup>6</sup> complete resection was achieved in 16 of 17 patients, and the surgical procedures were thoracotomy in 14, video assisted thoracoscopic surgery (VATS) in 3 patients. Surgical treatment was recommended to relieve

symptoms and prevent complications. In the serial of Limaem et al,<sup>7</sup> surgical excision was approached via thoracotomy in 32 patients, and via thoracoscopy in one. There were no post-operative deaths, but there were complications in 4 patients, pneumothorax, hemorrhage, pleural effusion, and seizure.<sup>7</sup> We also reported no mortality, while there were postoperative complications in 3 (11%) patients, 2 infections of the incision site, and one longer air leakage. Occurrence of possible complications of anatomic structure without any previous symptom should be considered while a decision is being made for surgical indication.<sup>6</sup> Therefore, we think all the diagnosed bronchogenic cysts should undergo a surgical resection, even if the patient is asymptomatic. In our serial, thoracotomy was used to perform resection. This method provided a complete resection, control of harm in surrounding tissues, and parenchymal resection safely when needed.

Recently, it has been reported that non-invasive methods are especially used in the resection of mediastinal cysts.<sup>16</sup> A recurrence after incomplete resection is an undesired condition. It should be avoided to perform incomplete resections. Although there are literature reports that recurrence may be prevented by ablation of residual tissue in incomplete resections, the border of resection area has to be made safe.<sup>2</sup> In our serial, it was taken care of by performing complete resection. The endoscopic approach was made only in one patient, who was diagnosed by coincidence during a diagnostic procedure, and he is still being followed. It is important to evaluate the long follow up period results of the minimal invasive technique. It is still a reality that the open invasive technique provides an opportunity for the surgeon to perform complete resections safely. Resection of bronchogenic cysts using VATS is a recent development. As a limitation of the study, we could not report the experience of VATS.

Bronchogenic cysts, especially symptomatic ones, and those diagnosed radiologically should undergo surgical resection. Surgical resection should be also considered in asymptomatic patients because of the possibility of malign transformation, and anatomic complications occurring in a period of being symptomatic. Complete resection, performed by non-invasive to open surgical methods, should be the major approach.

In conclusion, early surgical intervention, suggested for the exact diagnosis of bronchogenic cysts, may prevent operative difficulties and complications.

**Acknowledgment.** *The authors would like to thank Dr. Seber Susam, Consultant at the Department of Radiology, Izmir Dr. Suat Seren Chest Disease and Thoracic Surgery Training Hospital, for her help in the assessment of the radiological features.*

## References

1. Ribet ME, Copin MC, Gosselin B. Bronchogenic cysts of the mediastinum. *J Thorac Cardiovasc Surg* 1995; 109: 1003-1010.
2. La Quaglia MP. Congenital Anomalies. In: Pearson FG, Deslauriers J, Ginsberg RJ, editors. Thoracic Surgery. New York (NY): Churchill Livingstone Inc.; 1995. p. 411-432.
3. Liang MK, Marks JL. Congenital bronchogenic cyst in the gastric mucosa. *J Clin Pathol* 2005; 58: 1344.
4. Ustundag E, Iseri M, Keskin G, Yayla B, Muezzinoglu B. Cervical bronchogenic cysts in head and neck region. *J Laryngol Otol* 2005; 119: 419-423.
5. Ech-Cherif El Kettani N, Dafiri R. Bronchogenic cyst of the tongue: a very rare localization. *J Radiol* 2004; 85: 1736-1738.
6. Kanemitsu Y, Nakayama H, Asamura H, Kondo H, Tsuchiya R, Naruke T. Clinical features and management of bronchogenic cysts: report of 17 cases. *Surg Today* 1999; 29: 1201-1205.
7. Limaïem F, Ayadi-Kaddour A, Djilani H, Kilani T, El Mezni F. Pulmonary and mediastinal bronchogenic cysts: a clinicopathologic study of 33 cases. *Lung* 2008; 186: 55-61.
8. Patel SR, Meeker DP, Biscotti CV, Kirby TJ, Rice TW. Presentation and management of bronchogenic cysts in the adult. *Chest* 1994; 106: 79-85.
9. Ge F, Liao Q, Xiao S, Ren H, Zhang Z, Li Z. Diagnosis and surgical treatment of bronchogenic cysts. *Chin Med Sci J* 1995; 10: 61-62.
10. Zambudio AR, Lanzas JT, Calvo MJ, Fernández PJ, Paricio PP. Non-neoplastic mediastinal cysts. *Eur J Cardiothorac Surg* 2002; 22: 712-716.
11. St-Georges R, Deslauriers J, Duranceau A, Vaillancourt R, Deschamps C, Beauchamp G, et al. Clinical spectrum of bronchogenic cysts of the mediastinum and lung in the adult. *Ann Thorac Surg* 1991; 52: 6-13.
12. Sarper A, Ayten A, Golbasi I, Demircan A, Isin E. Bronchogenic cyst. *Tex Heart Inst J* 2003; 30: 105-108.
13. Lardinois D, Gugger M, Ris HB. Bronchogenic cyst of the left lower lobe associated with severe hemoptysis. *Eur J Cardiothorac Surg* 1999; 16: 382-383.
14. Nakata H, Nakayama C, Kimoto T, Nakayama T, Tsukamoto Y, Nobe T, et al. Computed tomography of mediastinal bronchogenic cysts. *J Comput Assist Tomogr* 1982; 6: 733-738.
15. Okada Y, Mori H, Maeda T, Obashi A, Itoh Y, Doi K. Congenital mediastinal bronchogenic cyst with malignant transformation: an autopsy report. *Pathol Int* 1996; 46: 594-600.
16. Lewis RJ, Caccavale RJ, Sisler GE. Imaged thoracoscopic surgery: a new thoracic technique for resection of mediastinal cysts. *Ann Thorac Surg* 1992; 53: 318-320.

## References

- \* References should be primary source and numbered in the order in which they appear in the text. At the end of the article the full list of references should follow the Vancouver style.
- \* Unpublished data and personal communications should be cited only in the text, not as a formal reference.
- \* The author is responsible for the accuracy and completeness of references and for their correct textual citation.
- \* When a citation is referred to in the text by name, the accompanying reference must be from the original source.
- \* Upon acceptance of a paper all authors must be able to provide the full paper for each reference cited upon request at any time up to publication.
- \* Only 1-2 up to date references should be used for each particular point in the text.

Sample references are available from:  
[http://www.nlm.nih.gov/bsd/uniform\\_requirements.html](http://www.nlm.nih.gov/bsd/uniform_requirements.html)