

Clinical application of scrotal flap on penis lengthening

Qinqiang Zhuo, MD, Shirong Li, MD, Julong Wu, MD, Zhenxiang Wang, MD, Dongyun Yang, MD, Ling Tao, MD.

ABSTRACT

الأهداف: لفحص التطبيق السريري لقطعة صغنية على عملية إطالة القضيب .

الطريقة: خضع 152 مريضاً لعملية جراحية تم فيها استعمال قطعة صغنية خلال الفترة ما بين يوليو 1998م وحتى يناير 2008م، في قسم الجراحة التجميلية والتخديرية - مستشفى الشمال الغربي - الصين. تم تصميم شق على شكل (+) بقياس 1.5cm فوق جذور القضيب، كما تم تسليخ وتحرير قطعة سطحية من عصابة دعم الخصيتين وجزء من رباط دعم الخصيتين، ثم تغطية الإطالة الكهفية بقطعة صغنية مناسبة.

النتائج: أظهرت المتابعة من 6 أشهر وحتى 5 سنوات أن جميع المرضى كانوا راضين مع كفاية ووظيفة القضيب. كانت العملية ناجحة.

خاتمة: هنالك مميزات باستخدام قطعة صغنية لإطالة القضيب: أنها عملية بسيطة ومعتمدة في تزويد الدم إلى القطعة، كما أنها عملية من مرحلة واحدة ونتائجها مرضية. تعد تقنية العملية هذه مفضلة لإطالة القضيب.

Objectives: To investigate the clinical application of the scrotal flap on penis lengthening.

Methods: One hundred and fifty-two patients were operated using the scrotal flap from July 1998 to January 2008 at the Department of Plastic and Aesthetic, Surgery Southwest Hospital, Chongqing, China. The procedure consisted of designing a positive sign shaped incision 1.5cm above the root of the penis, dissect and release the superficial suspensory ligament and part of the deep suspensory ligament, then cover the elongated cavernosum with proper scrotal flap.

Results: Six-month to 5-year follow-up showed that all patients were satisfied with the good contour and function of the penis. The operation was successful.

Conclusion: The method of using scrotal flap on penis lengthening has the following advantages: simple operation, reliable blood supply of the flap, one-stage

operation, and satisfactory postoperative results. It is a preferable operation technique for penis lengthening.

Saudi Med J 2009; Vol. 30 (3): 418-421

From the Department of Plastic and Aesthetic Surgery, Southwestern Hospital, Third Military Medical University, Chongqing, China.

Received 11th October 2008. Accepted 4th February 2009.

Address correspondence and reprint request to: Dr. Shirong Li, Department of Plastic and Aesthetic Surgery, Southwestern Hospital, Third Military Medical University, Chongqing 400038, China. Tel. +86 (23) 65410744. Fax. +86 (23) 65410744. E-mail: sulishirong@yahoo.com.cn

The penis is a generative and urinary organ of males. Penis minor malformation, either configuration or function, has great influence on patients' psychology and physiology.¹⁻³ Developing a procedure for penis lengthening is a great sign. In recent years, many methods have been established for penis plasty. Through years of anatomical investigation and clinical practice, our group believe the scrotal flap has obvious advantage on covering the elongated cavernosum of penis lengthening.⁴ We operated on patients using the scrotal flap. After 6-months to 5-years' follow-up, we acquired favorable results on both configuration and function. The aim of this study is to investigate the clinical application of the scrotal flap on penis lengthening.

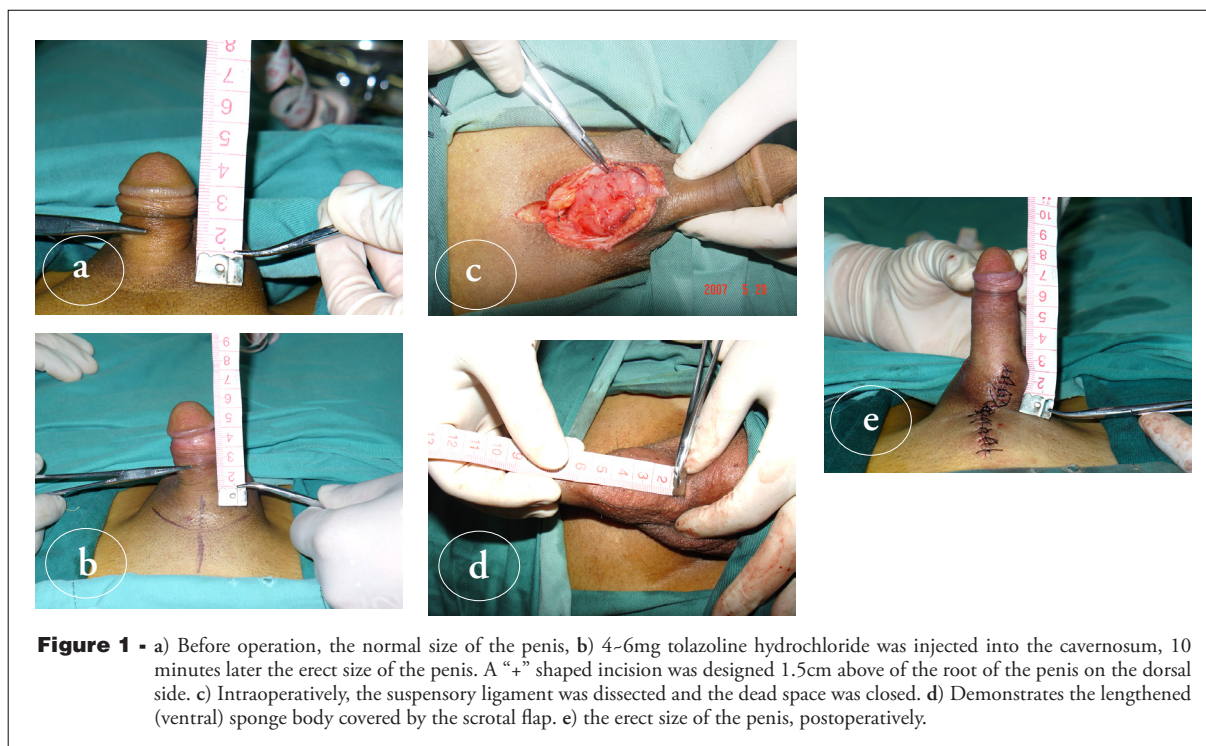
Methods. Our study includes 152 patients, 21-48 years old with an average age of 27 years. All procedure were performed between July 1998 to January 2008 at the Department of Plastic and Aesthetic, Surgery Southwest Hospital, Chongqing, China. One hundred and nine patients were married or had been married before the operation, 43 patients were unmarried. Penile length was measured on the dorsum of the penis beginning from the pubopenile junction to the tip of the glans. The average penile length preoperatively was 4.2 cm (2.5-6.5 cm). The scrotal skin of all patients were undamaged. The protocol of the study was approved by the Ethics Committee of the Southwestern Hospital and consent from the patients was obtained.

All patients received local anesthesia at the root of the penis with a 50 ml narcotic drug comprised of 10 ml 2% dolocaine, 0.5 mg adnephrin, and normal sodium. First, 4-6 mg tolazoline hydrochloride was injected in the cavernosum, and a rubber band was placed around the root of the penis for approximately 10 minutes for induction of an artificial erection, then the rubber band was removed and a "+" shaped incision was made 1.5 cm above the root of the penis on the dorsal side. The superficial suspensory ligament and all surrounding fascial bands were completely released on the upper part of the pubic symphysis. The deep suspensory ligament was dissected and released partly through the surface of the pubic symphysis, followed by suturing the stump of the suspensory ligament and closing of the dead space to prevent adhesion postoperation. A proper scrotal flap was designed and transferred to cover the elongated cavernosum from the root of the penis, after hemostasis by ligation was completed. The scrotal incision was sutured longitudinally directly (Figure 1). The whole operation takes approximately 25-40 minutes. Local pressurization with ice bag and elevation of the buttocks were conducted to abate edema and improve blood reflux. On the second day, 5 mg stilbestrol and 5 mg diazepam were taken orally by patients half an hour before sleep to reduce painful nocturnal erections. This therapy was discontinued after 3-5 days. Appropriate glans stretch was carried out after 3-6 weeks. The anti-scar treatment

was carried out after removal of stitches, if necessary. We used Statistical analysis SPSS version 10.01.

Results. All of the 152 patients were primary healed after operation, the scrotal flap was alive, without ischemic necrosis and wound dehiscence. The penile length increased from 1.5-5.3cm (Table 1). There was an average decrease in length of 0.2-1.0cm within the first 6 months of the procedure, and then there was no significant change. The color, luster, texture, and shape of the scrotal flap were all good and the patients' erection and sexual function were improved after the operation (Figure 2).

Discussion. The rudiment of penis lengthening is to dissect the suspensory ligament of the penis partly, and to liberate the cavernosum fixed on the pubic symphysis. If we want to extend the penis longer, the wound surface should be formed on the suprapubic region. Considerable experts have designed various kinds of skin flaps to cover the wound surface, such as inverted V-Y plasty, Z plasty, lower abdominal pedicled fascia flap, paraumbilical island flap, and pudendum and thigh flap,⁵ and so forth. The methods have different features and superiorities targeting different patients, but they all have considerable defect. The weak extensibility of the flap will affect the normal erection of the penis, and the complicated progress of operation



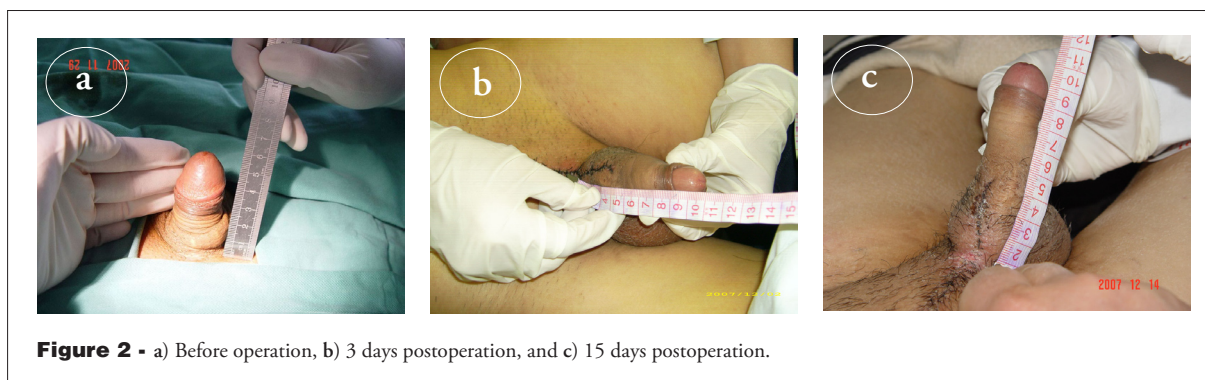


Figure 2 - a) Before operation, b) 3 days postoperation, and c) 15 days postoperation.

Table 1 - Length of penis.

Length	Preoperative	Postoperative	Postoperative (6 months)
Minimum (cm)	2.5	5.9	5.3
Maximum (cm)	6.5	10.8	10.2
Average (cm)	4.2	7.5	7.1

will induce a severe wound. If the length is over 4 cm, it is difficult to completely cover using the traditional inverted V-Y plasty or Z plasty. In order to overcome the insufficiency of the above mentioned skin flaps, we designed a “+” shaped incision and transferred the scrotal flap to cover the wound surface. The skin of the scrotum is thin, soft, and extensible. The membranous superficial fascia of the scrotum has no adipose layer. The feeding arteries' course of the scrotal flap is in the dartos fascia of the scrotum, which makes the scrotal flap be attributed to myocutaneous flap.^{6,7} Hence, the scrotal flap has little scar tissue and is feel good after operation.

Each side of the scrotum has 4 blood vessels: anterior scrotal arteries, lateral scrotal arteries, lateral branch of posterior scrotal arteries and septal scrotal arteries.⁸ These arteries form the multi-originated blood supply system of the skin of scrotum. Ischemic necrosis seldomly occurs in the scrotal flap. All of the 152 patients were primary healed postoperation. The postoperative hydrophallus is the most common complication, and the hydrophallus will last approximately 10 days to 3 months.⁹ The penile vein and the lymphatic return concentrate on the root of the penis. We made the incision 1.5cm above the root of the penis to protect the penile vein and lymphatic return and relieve the postoperative hydrophallus. The postoperative hydrophallus relieved with complete regression in one week.¹⁰ The wound surface formed by the cavernosum between normal situation and erection situation of penis length is different. The wound surface

formed in the erection penis is much larger than that of the normal penis and requires more flap to cover. Therefore, we inject 4-6 mg tolazoline hydrochloride into the cavernosum for the induction of an artificial erection. On one hand, we can transfer the appropriate scrotal flap and avoid the drag of flap during erection postoperation. On the other hand, the erected penis is easily hold and discriminated from other tissue. Injury to cavernosum should be avoided during operation. The scrotal flap has abundant blood supply, good flexibility, thin skin, fewer adipose layer and postoperative scar, and is similar to the physiological characters of the skin of the penis. The scrotal incision can be sutured directly after the flap is transferred, and the shape of the scrotum has little change. For patients with abundant hair, we suggest shearing the hair follicles to achieve a better appearance. If the scrotal skin is damaged and not adequate to cover the wound, other surgical methods should be adopted.

In conclusion, among various kinds of flap on penis lengthening, our approach can make full use of the flabby character of the scrotal skin and transfer the scrotum skin to cover the infrapubic wound formed by penis lengthening. It has obvious superiority over plastic operation and should be used widely.

References

- Colombo F, Casarico A. Penile enlargement. *Curr Opin Urol* 2008; 18: 583-588.
- Spyropoulos E, Christoforidis C, Borousas D, Mavrikos S, Bourounis M, Athanasiadis S. Augmentation phalloplasty surgery for penile dysmorphophobia in young adults: considerations regarding patient selection, outcome evaluation and techniques applied. *Eur Urol* 2005; 48: 121-127.
- Panfilov DE. Augmentative phalloplasty. *Aesthetic Plast Surg* 2006; 30: 183-197.
- Shirong L, Xuan Z, Zhengxiang W, Dongli F, Julong W, Dongyun Y. Modified penis lengthening surgery: review of 52 cases. *Plast Reconstr Surg* 2000; 105: 596-599.

5. Hu ZQ, Hyakusoku H, Gao JH, Aoki R, Ogawa R, Yan X. Penis reconstruction using three different operative methods. *Br J Plast Surg* 2005; 58: 487-492.
6. Mendez-Fernandez MA, Hollan C, Frank DH, Fisher JC. The scrotal myocutaneous flap. *Plast Reconstr Surg* 1986; 78: 676-678.
7. Giraldo F, Mora MJ, Solano A, González C, Smith-Fernández V. Male perineogenital anatomy and clinical applications in genital reconstructions and male-to-female sex reassignment surgery. *Plast Reconstr Surg* 2002; 109: 1301-1310.
8. Grossman JA, Caldamone A, Khouri R, Kenna DM. Cutaneous blood supply of the penis. *Plast Reconstr Surg* 1989; 83: 213-216.
9. Masuda H, Azuma H, Segawa N, Iwamoto Y, Inamoto T, Takasaki N, et al. Surgical correction of buried penis after traffic accident - a case report. *BMC Urol* 2004; 4: 6.
10. Li S, Tao L, Wang Z, Wu J, Yang D. Postoperative hydrophallus after penile lengthening: an experimental and clinical study. *Plast Reconstr Surg* 2007; 119: 768-770.

Illustrations, Figures, Photographs

Four copies of all figures or photographs should be included with the submitted manuscript. Figures submitted electronically should be in JPEG or TIFF format with a 300 dpi minimum resolution and in grayscale or CMYK (not RGB). Printed submissions should be on high-contrast glossy paper, and must be unmounted and untrimmed, with a preferred size between 4 x 5 inches and 5 x 7 inches (10 x 13 cm and 13 x 18 cm). The figure number, name of first author and an arrow indicating "top" should be typed on a gummed label and affixed to the back of each illustration. If arrows are used these should appear in a different color to the background color. Titles and detailed explanations belong in the legends, which should be submitted on a separate sheet, and not on the illustrations themselves. Written informed consent for publication must accompany any photograph in which the subject can be identified. Written copyright permission, from the publishers, must accompany any illustration that has been previously published. Photographs will be accepted at the discretion of the Editorial Board.