

The healing effects of *Teucrium polium* in the repair of indomethacin-induced gastric ulcer in rats

Davood Mehrabani, MPH, PhD, Aminallah Rezaee, MD, Negar Azarpira, MD, Mohammad R. Fattahi, MD, Masoud Amini, MD, Nader Tanideh, DVM, PhD, Mohammad R. Panjehshahin, PhD, Mehdi Saberi-Firouzi, MD.

ABSTRACT

الأهداف: لتحديد أثر شفاء تيوكروم بوليوم في القرحة المعدية المحرّضة بعقار اندوميثاسين في الجرذ كنموذج حيواني.

الطريقة: تم إحضار عدد 250 جرذ من نوع سبارجيو-داولي من مركز مختبر الحيوان بجامعة شيراز - إيران، خلال عام 2007م، وتم تقسيمهم إلى أربع مجموعات متساوية بما فيها مجموعة التحكم (70) وثلاث مجموعات للتجربة (60 جرذ في كل مجموعة) وتلقوا مختلف الجرعات من عقار تي. بوليوم. تم استخدام عشرة جرذان لدراسة القرحة المعدية المحرّضة بعقار اندوميثاسين (25mg/kg/stat). تم تقييم معدات الحيوانات لوجود غشاء مخاطي بعد 24 ساعة من إعطاء عقار تي. بوليوم عبر الفم. في مجموعة التجربة، تم التضحية بعشرة جرذان بعد 24، 48 و 72 ساعة، وبعد أسبوع، أسبوعين و 4 أسابيع بعد إعطائهم عقار تي. بوليوم وفي مجموعة التحكم بعد تلقي الماء المقطر.

النتائج: الجرذان الذين تمت معالجتهم بعقار اندوميثاسين، تبين وجود قرحات متعددة. بعد 4 أسابيع من العلاج بعقار تي. بوليوم، تبين وجود المزيد من إعادة التحول الظهاري، التشعب، زيادة في التنسج المخاطي، هجرة الخلايا الظهارية المعدية وانخفاض في الخلايا الالتهابية. خفض تي. بوليوم القرحة بنسبة >50% بعد أسبوع واحد، >80% بعد أسبوعين، >90% بعد أربعة أسابيع.

خاتمة: قد يكون سبب التأثير الشفائي لعقار تي. بوليوم ناتج عن نشاط مضاد الأكسدة القدرة على تعديل إفراز المخاط من الإثني عشر، اضطراب الفعّة السداسية من الأحماض الدهنية في الجسم (بروستاغلاندين) وظهور مستقبل عامل النمو الظهاري. تقترح هذه النتائج مع الخصائص الاسمية لعقار تي. بوليوم كمركب واعد مضاد للقرحة.

Objectives: To determine the healing effect of *Teucrium polium* (*T. polium*) in indomethacin-induced gastric ulcer in rats.

Methods: In the fall of 2007, 250 Sprague-Dawley rats provided by the Shiraz University Laboratory Animal Center were divided into 4 equal groups including control (70 rats), and 3 experimental groups (60 rats

each), and each group received different doses of *T. polium*. Ten rats were used to study the induction of gastric ulcer by indomethacin (25 mg/kg/stat). After 24 hours, their stomachs were evaluated for any mucosal ulcer. The *T. polium* extract was administered orally, 24 hours after indomethacin administration. In the experimental group, 10 animals were sacrificed after 24, 48, and 72 hours, after administration of *T. polium*, and at one, 2, and 4 weeks, and in the control group identically after the administration of distilled water.

Results: In rats treated with indomethacin, multiple ulcers were evident. After 4 weeks of treatment with *T. polium*, more re-epithelialization, proliferation, mucosal hyperplasia, migration of the gastric epithelial cells, and decrease in inflammatory cells were observed. The *T. polium* reduced the ulcer indices by >50% after one week, >80% after 2 weeks, and >90% after 4 weeks.

Conclusion: The healing effect of *T. polium* may be due to antioxidant activity along with the ability to modulate the mucin secretion, prostaglandin synthesis, and epidermal growth factor receptor expression. These results along with the non-toxicity properties of *T. polium* suggests it as a promising anti-ulcer compound.

Saudi Med J 2009; Vol. 30 (4): 494-499

From the Department of Pathology (Mehrabani, Fattahi, Saberi-Firouzi), Gastroenterohepatology Research Center, Nemazee Hospital, and the Departments of Internal Medicine (Rezaee), Pathology (Azarpira), Surgery (Amini), and Pharmacology (Tanideh, Panjehshahin), Comparative Medicine Research Center, Shiraz University of Medical Sciences, Shiraz, Iran.

Received 28th October 2008. Accepted 31st March 2009.

Address correspondence and reprint request to: Assistant Professor Davood Mehrabani, Department of Pathology, Gastroenterohepatology Research Center, Nemazee Hospital, PO Box 71345-1744, Shiraz University of Medical Sciences, Shiraz, Iran. Tel. +98 (711) 6474263. Fax. +98 (711) 6474263. E-mail: mehrabad@sums.ac.ir

Peptic ulcer diseases (PUDs) are the disruption of the mucosal integrity of the stomach, and/or duodenum leading to a local defect or excavation due to active inflammation, and are chronic in nature. The PUDs are very common, and in the United States, approximately 4 million individuals are affected each year.¹ Life time prevalence of PUD in the United States is approximately 12% in men, and 10% in women. Moreover, 15000 deaths per year were reported due to complications of PUD. The non-steroidal anti-inflammatory drugs (NSAIDs) are increasingly used for the prevention of malignancies, stroke, pre-eclampsia, Alzheimer, and many other illnesses.^{2,3} However, the NSAIDs produce gastroduodenal ulcers in 25% of individuals, often presented with bleeding and/or perforation. Amongst the various factors known to cause gastric ulcer, NSAIDs are more prevalent.⁴ Several different therapies were used including antacids and antihistaminics, most of them produce many adverse reactions form of mild-to-severe ones, such as arrhythmias, impotence, gynecomastia, and hematopoietic changes.⁵ Thus, there is a need for a more effective, inexpensive, and less toxic anti-ulcer agents. Folk medicine, since many years ago was used for the treatment of PUD in many countries and Iran. Some of these herbal drugs consist deglycyrrhizinated form of licorice (DGL), dried banana powder (*Musa paradisiaca*), chamomile, calendula, marshmallow, garlic, corydalis, and comfrey. Plant extracts are some of the most attractive sources of new drugs and were shown to produce promising results in PUDs.⁶ The *Teucrium polium* (*T. polium* [Lamiaceae]) is a wild-growing flowering plant, found abundantly in South-Western Asia, Europe, and North Africa and has approximately 220 genera, and almost 4000 species worldwide.^{7,8} The *T. polium* species were used as medical herb for more than 2000 years. Different properties were reported by various *T. polium* species.⁹ The *T. polium* is well-known for its diuretic, antipyretic, diaphoretic, antispasmodic, tonic, anti-inflammatory, antihypertensive, anorexic, analgesic,^{10,11} antibacterial¹² and antidiabetic properties.¹³ It also showed an effective protection against ethanol-induced gastric mucosal damage (92.8%),¹⁴ and was reported to reduce nicotinamide adenine dinucleotide phosphate (NADPH)-initiated lipid peroxidation in rat liver microsomes.¹⁵ There are no data available in the literature on anti-ulcer properties of *T. polium* in PUDs. This study was performed to investigate the healing effect of *T. polium* in indomethacin-induced gastric ulcers in rats as an animal model.

Methods. In the fall of 2007, 250 male, 200-250 g Sprague-Dawley rats provided by the Laboratory Animal Center affiliated to Shiraz University of Medical Sciences were divided into 4 equal groups including

control (70 rats), and 3 experimental groups (each 60 rats). Ten rats were used for the induction of gastric ulcer by indomethacin (25 mg/kg/stat orally in distilled water), and after 24 hours, they were euthanized, sacrificed, and their stomachs were evaluated grossly and microscopically for the presence of any mucosal ulcer. Two 5 μ tissue sections were provided from each animals' stomach, and stained with hematoxylin and eosin. There were no deaths prior to completion of the experiments. In the experimental group, animals were sacrificed after 24 (10 rats), 48 (10 rats), and 72 hours (10 rats), and at one (10 rats), 2 (10 rats), and 4 weeks (10 rats) after the administration of *T. polium* (Barieej Essence Company, Tehran, Iran), and in the control groups after the equivolume administration of distilled water similar to the experimental group. In the preparation of *T. polium*, 100 g of dehydrated *T. polium* was ground to a fine texture, and was repeatedly extracted with 80% ethanol. This extract was completely dried under vacuum and dissolved in distilled water before use. The *T. polium* extract was administered in doses of 200, 300, and 400 mg/kg body weight/day orally via a stainless steel intubation tube, 24 hours after indomethacin administration.¹⁵ Under the light microscope, one centimeter length of each section was divided into 3 fields, and each field was scored on a 0-4 scale as described by Esplugues et al,¹⁶ such as: 0 (normal), 1 (epithelial cell damage), 2 (glandular disruption, Vasocongestion or edema in the upper mucosa), 3 (mucosal disruption, vasoconstriction or edema in the mild lower mucosa), and 4 (extensive mucosal disruption involving the full thickness of the mucosa).¹⁶ The overall mean value of the scores for each of the fields was considered as the histopathological ulcer index for that section. To eliminate the observer bias, the pathologists were blinded. Lesions in the glandular part of the stomach were measured under an illuminated magnifying microscope (10x). Lesions were counted and measured along their greater length. Petechial lesions were counted with the aid of a grid (1 mm²). Each 5 petechial lesions were regarded as 1 mm of ulcer. The sum of the total length of ulcers and petechial lesions in each group of rats was divided by its number to calculate the ulcer index (mm). In the animal selection, in all experiments, subsequent care and the sacrifice procedure were all adhered to the guidelines, and were under the supervision of the Animal Care Committee of Iran Veterinary

Disclosure. This study was financially supported by the Office of the Vice Chancellor for Research, Shiraz University of Medical Sciences, Shiraz, Iran.

Organization. All experiments were carried out under aseptic conditions in the Laboratory Animal Center of Shiraz University of Medical Sciences. The protocol of anesthesia, surgical procedures, postoperative care, and sacrifice were identical for all animals. The animals were sacrificed under deep ether general anesthesia. The study was approved by the Ethics Committee of Shiraz University of Medical Sciences. The rats were provided by the Laboratory Animal Center of Shiraz University of Medical Sciences. The animals were housed in an ambient temperature of $21 \pm 2^\circ\text{C}$, and a 65-70% relative humidity. They received a balanced diet and had free access to water. Before ulcer induction, all animals were deprived of food for 24 hours, but had free access to water to prevent excessive dehydration during starvation.

The Statistical Program for Social Sciences version 15.0 (SPSS Inc., Chicago, Illinois, USA) was used for

the statistical analysis. The histological ulcer index in the stomach was evaluated by independent sample test. The results are presented as mean \pm SD, and differences were considered significant for $p < 0.05$.

Results. After the administration of indomethacin, multiple hemorrhagic lesions, and ulcers with disruption and edema in all glandular area of the stomach were visible (damage scores of 2 and partly 3). When the ulceration was at the highest level, the maximum damage was present in the gastric mucosa due to the exfoliation of gastric epithelial cells, and the disruption of mucosal layer (damages score of 3 and mostly 4), (Figures 1a & 1b). Loss of faveolar, as well as cryptic architecture was also observed. The administration of indomethacin could induce injury in submucosa, serosa, and muscle layers. The healing effect of *T. polium* was evident even

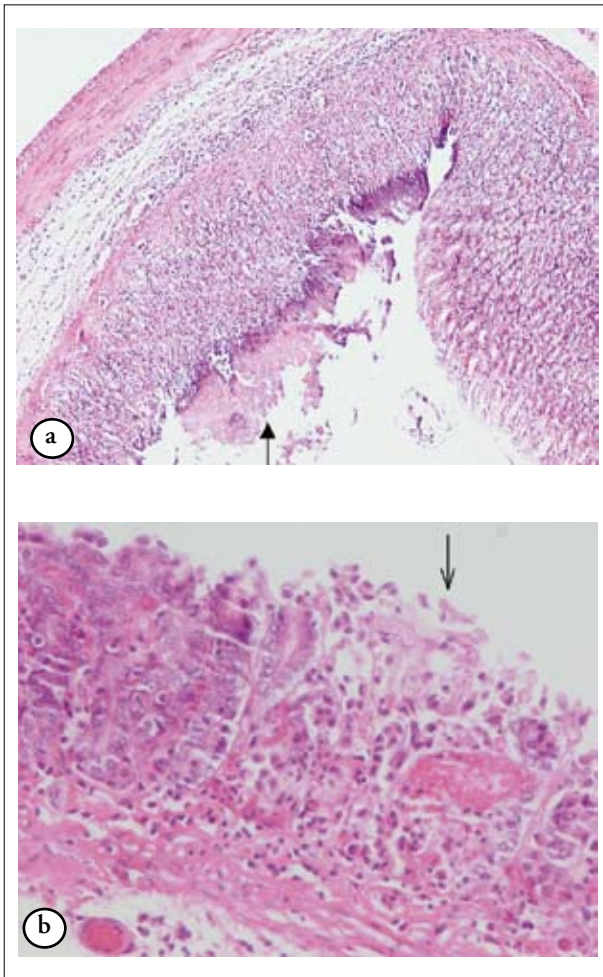


Figure 1 - Mucosal disruption involving the full thickness of the mucosa, score 3 a) the exfoliation of gastric epithelial cells (Hematoxylin and eosin x100) b) the exfoliation of gastric epithelial cells (Hematoxylin and eosin x400).

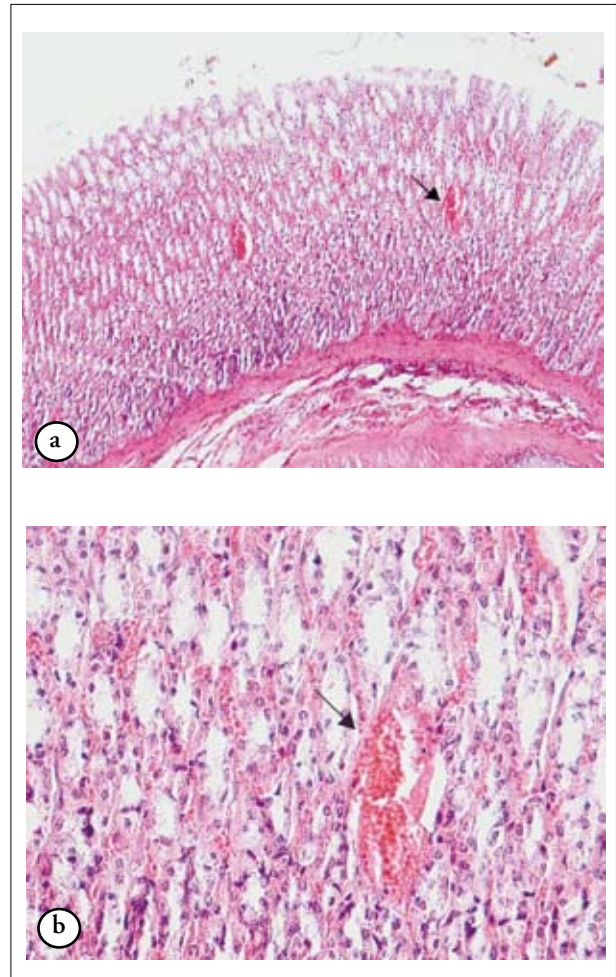


Figure 2 - Histology showing a) vasocongestion (Hematoxylin and eosin x100) b) edema in the upper mucosa (arrow), score 2 (Hematoxylin and eosin x400).

from the first day of ulcer induction, and the glandular damage was confined to localized areas (damage scores of 1 and 2) (Figures 2a & 2b). The maximum ulceration was seen on the second day after the administration of indomethacin, which was effectively healed by *T. polium*. Four weeks after the administration of *T. polium*, more re-epithelialization, cryptic proliferation, mucosal hyperplasia, and migration of the gastric epithelial cells to the ulcerated zone were observed leading to a progressive regeneration of the mucosal architecture (damage scores of 0 and 1), ($p=0.001$), (Table 1). In the ulcerated areas, the pattern of healing resembled a squamous metaplasia (Figure 3). Treatment with *T. polium* can restore the gastric architecture and increase the number of healthy cells, but reduced the number of inflammatory cells and decreased the inflammatory burden. It can also reverse the damage of the epithelial cells in the gastric surface, as well as the mucosal layer of gastric lumen produced by indomethacin, which led to a faster ulcer healing (damage scores of 0 and 1). In comparison to the control group, in the experimental

group, *T. polium* can reduce the ulcer indices by >50% after one week, >80% after 2 weeks, and >90% after 4 weeks. Seventy-two hours and one week after the administration of indomethacin, *T. polium* in doses of 300 and 400 mg/kg body weight/day had a significant more healing effect than the dose of 200 mg/kg body weight/day ($p=0.001$), but after 4 weeks, all doses demonstrated similar effects.

Discussion. Ulcer healing is a complex process and various factors may affect the healing. The gastrototoxicity of the NSAIDs such as indomethacin in animals can be attributed to their ability to induce the reactive oxygen metabolites.¹⁷ It can also delay ulcer healing by reducing the prostaglandin (PG) level,¹⁸ and prevent the PG-mediated angiogenesis. In addition, the NSAIDs produce hemorrhagic ulcers by decreasing the gastric mucus production.¹⁹ It was shown that chronic exposure to indomethacin would suppress the gastric PG synthesis.²⁰ In our study, indomethacin induced gastric damage in >90% of animals when compared to other methods, which produced extremely variable rates of gastric ulcerations as reported by Tari et al.²¹ After the acute injury the release of mucus, which was previously formed in the area can accelerate the recovery of the epithelium due to the formation of a mucoid cap and a re-epithelialization beneath it. The growth factors and their receptors, such as epidermal growth factor (EGF) receptor facilitate the ulcer healing due to the strengthening of angiogenesis, and an increase in the release of gastric mucin. Therefore, medications with antioxidant activity that arrest ulcer progression, and also promote PGE2 secretion, gastric mucus, and EGF receptor can potentiate the healing in gastric ulcers.³

The *T. polium* has been long recognized in folk medicine for the treatment of many pathophysiological conditions, such as gastrointestinal disorders, inflammations, diabetes, and rheumatism. Its extract was shown to induced hypotensive,¹¹ anti-

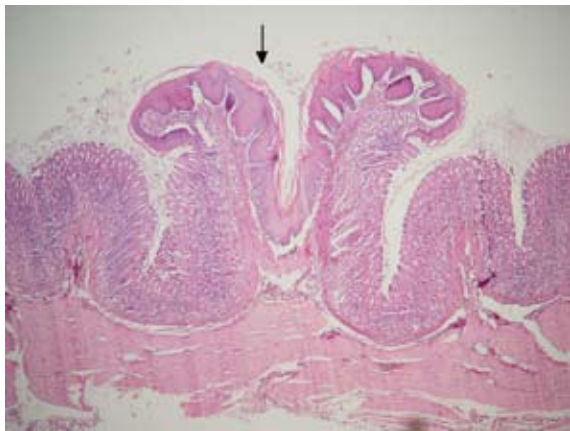


Figure 3 - Squamous metaplasia (Hematoxylin and Eosin x100).

Table 1 - Histological comparison of gastric histological ulcer index between groups receiving only indomethacin and indomethacin and *Teucrium polium* (*T. polium*) (N=20).

| Treatment | 24 hours (index ± SD) | 48 hours (index ± SD) | 72 hours (index ± SD) | 1 week (index ± SD) | 2 weeks (index ± SD) | 4 weeks (index ± SD) |
|-------------------------------|--------------------------|--------------------------|--------------------------|------------------------|-------------------------|-------------------------|
| Indomethacin 25 mg/kg | 8 ± 0.91 | 8.05 ± 0.88 | 8.10 ± 0.78 | 7.85 ± 0.98 | 7.50 ± 1 | 7.40 ± 0.99 |
| <i>T. polium</i> 200 mg/kg | 6.15 ± 0.98 | 5.65 ± 0.67 | 4.95 ± 0.75 | 5.15 ± 0.81 | 1.90 ± 0.91 | 0.60 ± 0.68 |
| <i>T. polium</i> 300 mg/kg | 5.80 ± 0.76 | 5.65 ± 0.67 | 4.25 ± 0.78 | 3.15 ± 0.98 | 1.25 ± 0.96 | 0.55 ± 0.60 |
| <i>T. polium</i> 400 mg/kg | 5.75 ± 0.91 | 5.60 ± 0.68 | 4.20 ± 0.83 | 3.05 ± 0.10 | 1.20 ± 0.89 | 0.55 ± 0.60 |

*10 rats, each rat 2 samples, total samples 20, $p=0.001$

inflammatory,¹⁰ hypoglycemic,²² antispasmodic,²³ antibacterial and antipyretic effects.²⁴ Most of these effects were related to the antioxidant and free radical scavenging properties of *T. polium*.²⁵ As *T. polium* was shown to have strong in vitro antioxidant properties, this study investigated the possible protective effects of *T. polium* against indomethacin-induced gastric lesions in rats as an animal model. The mechanism of indomethacin-induced stomach ulcer include inhibition of prostaglandin biosynthesis, and a reduction in local repair.²⁶ Our histopathological examinations revealed that administration of indomethacin resulted into a marked damage in the gastric mucosa within 24 hours, and with elongated hemorrhagic lesions confined to the glandular portion. The acute nature of ulceration was evident due to the natural recovery (auto healing) of the gastric tissues even without any treatment. The process of auto healing was slow and visible only after 5 days when the ulcer craters receded partially.

The rats treated with *T. polium* showed a significant faster and better healing. Extension of the treatment to 4 weeks led to a marginally better healing. The effects of *T. polium* in a dose of 300 mg/kg body weight/day did not show any significant difference with a dose of 400 mg/kg body weight/day, but was significantly better than a dose of 200 mg/kg body weight/day after one week. After 2 and 4 weeks, no significant difference was visible. The *T. polium* in a dose of 300 mg/kg body weight/day showed the maximum efficacy of therapeutic dose. This finding was also correlated with the folk medicinal use of *T. polium* observed by Sfikas,²⁷ who reported that *T. polium* was effective for the treatment of stomach inflammation and peptic ulcers. Moreover, *T. polium* aqueous extract in a dose of 150 mg/kg had a significant anti-ulcer effect on reserpine- and stress-induced gastric ulcer. The present finding showed that ethanolic extract of *T. polium* also produced a significant protective effect on ethanol-induced acute gastric ulceration. The present finding also supported the findings of Tyler.²⁸ The qualitative histopathological assessments were also well correlated with these data. Gastric ulcer is now believed to be due to an imbalance between acid and pepsin and weakness of the mucosal barrier.²⁹

Several mechanisms were suggested for the effect of anti-ulcer principles, including increasing the gastric hexosamine level and enhancing the strength of the gastric barrier either physically or by blocking the hydrogen⁺, potassium⁺-ATPase pump,⁶ stimulation of membrane stabilization by interference with calcium²⁺ influx, scavenging oxygen generated free radicals, and inhibiting peroxidation of biological membranes.³⁰ Each extract of the tested plants may present its activity by one or more of the reported mechanisms.

In conclusion, the present study showed that *T. polium* in dose of 300 mg/kg body weight/day could significantly lead to healing properties on indomethacin-induced stomach ulceration in rat. The healing could be attributed to their antioxidant activity along with the ability to modulate the mucin secretion, PG synthesis and EGF receptor expression. These results along with the non-toxicity properties of *T. polium* suggests it as a promising anti-ulcerogenic compound. However, the anti-ulcer effects can be due to all effective plant extracts such as tannins and/or flavonoids. Further studies seemed to be necessary for the isolation of the active ingredients, and to clarify the exact mechanism of anti-ulcer activity of these plants.¹⁴

Acknowledgment. *The authors would like to thank the Barieej Essence Company, Tehran, Iran for the free delivery of T. polium extract, the personnel of Laboratory Animal Center of Shiraz University of Medical Sciences for their laboratory assistance, Dr. Heydari for the statistical advice, and Dr. Khademolhosseini for the editorial assistance.*

References

1. Kasper DL, Braunwald E, Fauci AS, Hauser SL, Longo DL, Jameson JL. Peptic ulcer disease and related disorders. In: Harrison's Principles of Internal Medicine. 17th ed. New York (New York): McGraw-Hill Co.; 2008. p. 1862.
2. Tarnawski AS, Jones MK. Inhibition of angiogenesis by NSAIDs: molecular mechanisms and clinical implications. *J Mol Med* 2003; 81: 627-636.
3. Banerjee D, Bauri AK, Guha RK, Bandyopadhyay SK, Chattopadhyay S. Healing properties of malabaricone B and malabaricone C, against indomethacin-induced gastric ulceration and mechanism of action. *Eur J Pharmacol* 2008; 578: 300-312.
4. Dhikav V, Singh S, Pande S, Chawla A, Anand KS. Non-steroidal drug-induced gastrointestinal toxicity: mechanisms and management. *Journal Indian Academy of Clinical Medicine* 2003; 4: 315-322.
5. Coruzzi G, Adami M, Morini G, Pozzoli C, Cena C, Bertinaria M, et al. Antisecretory and gastroprotective activities of compounds endowed with H2 antagonistic and nitric oxide (NO) donor properties. *J Physiol Paris* 2000; 94: 5-10.
6. Ariypshi I, Toshiharu A, Sugimura F, Abe M, Matsuo Y, Honda T. Recurrence during maintenance therapy with histamine H2 receptors antagonist in cases of gastric ulcers. *Nikon University Journal of Medicine* 1986; 28: 69-74.
7. Naghibi F, Mosaddegh M, Mohammadi-Motamed S, Ghorbani A. Labiatae Family in folk Medicine in Iran: from Ethnobotany to Pharmacology. *Iranian Journal of Pharmaceutical Research* 2005; 2: 63-79.
8. Jamzad Z, Ingrouille M, Simmonds MSJ. Three new species of *Nepeta* (Lamiaceae) from Iran. *Taxon* 2003; 52: 93-98.
9. Agel MB, Garaibeh MN, Salhab AS. The calcium antagonistic effect of the volatile oil of *Teucrium polium*. *International Journal of Crude Drug Research* 1990; 28: 201-210.
10. Tariq M, Ageel AM, al-Yahya MA, Mossa JS, al-Said MS. Anti-inflammatory activity of *Teucrium polium*. *Int J Tissue React* 1989; 11: 185-188.
11. Suleiman MS, Abdul-Ghani AS, Al-Khalil S, Amin R. Effect of *Teucrium polium* boiled leaf extract on intestinal motility and blood pressure. *J Ethnopharmacol* 1988; 22: 111-116.

12. Mansouri S. Inhibition of staphylococcus aureus mediated by extracts of Iranian plants. *Pharma Biol* 1999; 37: 375-377.
13. Esmaeili MA, Yazdanparast R. Hypoglycaemic effect of Teucrium polium: studies with rat pancreatic islets. *J Ethnopharmacol* 2004; 95: 27-30.
14. Alkofahi A, Atta AH. Pharmacological screening of the anti-ulcerogenic effects of some Jordanian medicinal plants in rats. *J Ethnopharmacol* 1999; 67: 341-345.
15. Hasani P, Yasa N, Vosough-Ghanbari S, Mohammadirad A, Dehghan G. In vivo antioxidant potential of Teucrium polium, as compared to α -tocopherol. *Acta Pharma* 2007; 57: 123-129.
16. Esplugues JV, Whittle BJ. Gastric damage following local intra-arterial administration of reactive oxygen metabolites in the rat. *Br J Pharmacol* 1989; 97: 1085-1092.
17. Valcheva-Kuzmanova S, Marazova K, Krasnaliev I, Galunska B, Borisova P, Belcheva A. Effect of Aronia melanocarpa fruit juice on indomethacin-induced gastric mucosal damage and oxidative stress in rats. *Exp Toxicol Pathol* 2005; 56: 385-392.
18. Dormond O, Bezzi M, Mariotti A, Ruegg C. Prostaglandin E2 promotes integrin α V β 3-dependent endothelial cell adhesion, α 5 β 1-activation, and spreading through cAMP/PKA-dependent signaling. *J Biol Chem* 2002; 277: 45838-45846.
19. Karateev AE, Nasonova VA. [Development and relapse of gastroduodenal ulcer in patients taking nonsteroid anti-inflammatory drugs: effects of standard risk factors]. *Ter Arkh* 2008; 80: 62-66. Russian.
20. Said QHM, Kassim NM, Top GM, Ismail NM. Tocotrienol-rich fraction and its effects on parameters affecting gastric mucosal integrity after a single exposure to indomethacin. *Pakistan Journal of Nutrition* 2002; 1: 89-92.
21. Tari A, Kuruhara Y, Yonei Y, Yamauchi R, Okahara S, Sumii K, et al. Effects of omeprazole and pirenzepine on enterochromaffin-like cells and parietal cells in rat stomach. *J Gastroenterol* 2001; 36: 375-385.
22. Gharaibeh MN, Elayan HH, Salhab AS. Hypoglycemic effects of Teucrium polium. *J Ethnopharmacol* 1988; 24: 93-99.
23. Yaniv Z, Dafni A, Friedman J, Palevitch D. Plants used for the treatment of diabetes in Israel. *J Ethnopharmacol* 1987; 19: 145-151.
24. Autore G, Capasso F, De Fusco R, Fasulo MP, Lembo M, Mascolo N, et al. Antipyretic and antibacterial actions of Teucrium polium (L.). *Pharmacol Res Commun* 1984; 16: 21-29.
25. Ilhami G, Metin U, Munir O, Suktru B, Irfan K. Antioxidant and antimicrobial activities of Teucrium polium L. *J Food Technol* 2003; 1: 9-16.
26. Kashiwagi H. Ulcers and gastritis. *Endoscopy* 2003; 35: 9-14.
27. Sfikas G. Medicinal Plants of Greece. Athens (Greece): Efstathiadis and Sons; 1979. p. 64
28. Tyler VE. The New Honest Herbal. Philadelphia (PA): George F. Stickley Company; 1987. p. 143.
29. Choung RS, Talley NJ. Epidemiology and clinical presentation of stress-related peptic damage and chronic peptic ulcer. *Curr Mol Med* 2008; 8: 253-257.
30. Cholbi MR, Paya M, Alcaraz MJ. Inhibitory effects of phenolic compounds on CCl₄-induced microsomal lipid peroxidation. *Experientia* 1991; 7: 195-199.

Related topics

Mansour-Ghanaei F, Abbasi R, Joukar F, Besharati S, Askari-Jirhandeh N. Anti CagA antibody among patients with non-cardia gastric cancer in comparison with non-ulcer dyspepsia in an area with high incidence of gastric cancer. *Saudi Med J* 2008; 29: 1606-1610.

Bin-Taleb AK, Razaq RA, Al-Kathiri ZO. Management of perforated peptic ulcer in patients at a teaching hospital. *Saudi Med J* 2008; 29: 245-250.

Kurt D, Saruhan BG, Kanay Z, Yokus B, Kanay BE, Unver O, Hatipoglu S. Effect of ovariectomy and female sex hormones administration upon gastric ulceration induced by cold and immobility restraint stress. *Saudi Med J* 2007 Jul;28(7):1021-7.

Murat N, Gidener S, Koyuncuoglu M, Yilmaz O. The effect of nonsteroidal anti-inflammatory drugs on rat gastric mucosa. The role of endothelin. *Saudi Med J* 2007; 28: 612-616.