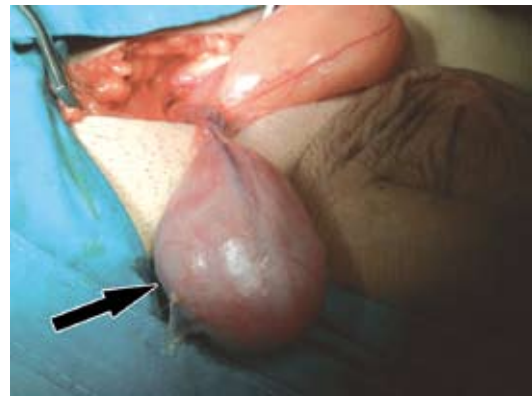


## Solitary fibrous tumor of the spermatic cord

*Miguel A. Arrabal-Polo, MD,  
Manuel Pareja-Vilchez, MD, Miguel Arrabal-Martin, MD,  
Armando Zuluaga-Gomez, MD.*

The aim of this clinical note is to present a rare localization of solitary fibrous tumor, which may be confused with a malignant tumor. As a rule, tumoral pathology of the spermatic cord is located at the inguinal-scrotal region, and it does not depend on testes, tunic, or epididymis. Most tumors located at this region are benign, although some aggressive tumors may become malign ones. Within the group of benign tumors we can see that some of them have a dysembryoplastic, epithelial, and mesenchymal origin (where the lipoma is the most frequent one among them); as for malign tumors, most of them are sarcomas showing different cell lineages. We report a 44-year-old male who shows a nodular lesion on the left scrotal region that has been histologically catalogued as a solitary fibrous tumor. These types of tumors are more frequently located at the pleura, but cases concerning liver, breast, meninges, thyroids, genitourinary system, respiratory tract, and orbit have also been reported. The medical literature reports 4 cases referring to spermatic-cord dependent conditions that are very similar to the case we present here.

A 44-year-old patient with no significant case history reported an asymptomatic mass located on the left scrotal region discovered by chance. Initial palpation shows an irregular and mobile mass with a hard and solid consistency that is not painful to tactual exploration and, which do not seem to be testicle or epididymis dependent, but seems to be adhered to the spermatic cord by a thin pedicle. The ultrasound scanning reported an isoechogenic mass, non-dependent on testicle, or epididymis but on spermatic cord; also, nuclear magnetic resonance (NMR) was suggested to better determine the lesion. The NMR showed a hypo-intense nodular lesion, with a maximum diameter of 5 cm, diagnosing a possible mesenchymal tumor associated to an inguinal ipsilateral hernia (Figure 1). Tumor markers (chorionic gonadotropin [CGH] 0.1 mUI/ml, and alpha-fetoprotein [AF] 3.9 ng/ml) showed normal values. Other tumor markers, including carcinoembryonic antigen (4.9 ng/ml), CA 19.9 (3.9 U/ml), CA 125 (7.22 U/ml) and CA 15.3 (17.1 U/ml), showed normal values. It was decided to conduct surgical treatment to remove the lesion through the inguinal region, and repair the left inguinal hernia. The histological analysis of the sample revealed a nacre-like hard mass under macroscopic examination, while the microscope showed fusiform cells, collagen



**Figure 1** - Surgical incision that shows a mass accompanied by a thin pedicle and rest of epiploon protuberating through the inguinal orifice.

fibers, and vascular axes that determined a positive immunohistochemical test for vimentin, CD34, and CD 99, all of which confirmed the solitary fibrous tumor diagnosis. No other treatment was conducted due to the benign nature of the condition, and he is currently undergoing periodical check-ups at the physician's office.

The pleura is the site that solitary fibrous tumors affect more frequently; this condition was described for the first time in full histological detail by Klemperer and Rabin in 1931.<sup>1</sup> Apart from this localization, other body regions have also been described as targets, and they make reference to the urogenital tract in the testicular and paratesticular area,<sup>2</sup> prostate, urinary bladder, kidney,<sup>2</sup> and retroperitoneal cavity. This is a mesenchymal-lineage tumor that has received many names and, depending on its localization, has been described by the medical literature as paratesticular benign fibrous tumor, fibrous mesothelioma, proliferative funiculitis, fibromatous periorchitis, fibrous pseudotumor, benign mesothelioma, and others.<sup>3</sup> It usually manifests in adults who are generally over 40 years of age, regardless of their gender and race; as for frequency, it is the second paratesticular benign condition next to adenomatoid tumors. With regard to clinical localization, these tumors extend asymptotically and rapidly, and hardly exhibit a compressive symptomatology as in the case of retroperitoneal or pleural conditions. As a rule, the analytic repercussions and clinical manifestations of this condition are not significant; it is only a casual discovery that prompts patients to visit a specialist. Diagnosis of suspicion is carried out through imaging test (ultrasound, scanning, and nuclear magnetic resonance) and subsequently confirmed by the histological study of the lesion, which usually shows positive immunohistochemistry for CD34, CD99, bcl-2 and insulin growth factor, type II,<sup>4</sup> while it is negative for

keratin, S100 protein, or muscle markers.<sup>5</sup> It is advisable to conduct a differential diagnosis of the lesion on the following conditions: hemangiopericytoma, malignant fibrous-histiocytoma, leiomyoma, leiomyosarcoma, schwannoma, carcinosarcoma, gastrointestinal stromal tumors, neurofibromas, and dermatofibromas.<sup>4</sup> Surgical removal is the treatment of choice for solitary fibrous tumors. Around 80-90% of cases exhibit a benign behavior, therefore adjuvant therapy is not necessary, only a simple follow-up of patients is advisable. Relapse and malignization are rare, and distant metastases are also infrequent. Cases published so far referring to this paratesticular localization are benign and do not exhibit relapse or distant metastasis during follow-up.<sup>1</sup>

It is necessary to conduct more long-term follow-ups, as well as studies that may include a higher number of patients, to corroborate the benign and innocuous behavior of this lesion; although it is not an easy task on account of the low frequency of this lesion. We therefore regard the publication of this new case on a solitary fibrous tumor in paratesticular region, spermatic-cord-dependent, and associated to left inguinal hernia as an issue of general interest.

**Acknowledgment.** *The authors gratefully acknowledge Dr. Francisco Valle-Diaz de la Guardia and Dr. Felix Abad-Menor for their valuable contribution in this article.*

*Received 10th January 2009. Accepted 15th March 2009.*

*From the Urology Department, San Cecilio University Hospital, Granada, Spain. Address correspondence and reprint request to: Dr. Miguel Angel P. Arrabal, Camino de Ronda Street, 143. Granada, Post Code 18003, Spain. Tel. +34 (95) 8970041. Fax. +34 (95) 8023084. E-mail:arrabalp@ono.com*

## References

1. Klemperer P, Rabin CB. Primary neoplasm of the pleura: report of five cases. *Arch Pathol* 1931; 11: 385-412.
2. Honeck P, Ströbel P, Michel MS, Bolenz C, Wendt-Nordahl G, Alken P, et al. [Solitary fibrous tumour of the testes (SFT)] *Aktuelle Urol* 2008; 39: 305-308. German.
3. García Torrelles M, Beltrán Armada JR, Santolaya García I, Carrascosa Lloret V, Tarín Planes M, San Juan De Laorden C. [Solitary fibrous tumor of the tunica vaginalis testis] *Arch Esp Urol* 2006; 59: 186-189. Spanish.
4. Leite KR, Srougi M, Miotto A, Camara-Lopes LH. Solitary fibrous tumor in bladder wall. *Int Braz J Urol* 2004; 30: 406-409.
5. Wang J, Arber DA, Frankel K, Weiss LM. Large solitary fibrous tumor of the kidney: report of two cases and review of the literature. *Am J Surg Pathol* 2001; 25: 1194-1199.

## Case Reports

Case reports will only be considered for unusual topics that add something new to the literature. All Case Reports should include at least one figure. Written informed consent for publication must accompany any photograph in which the subject can be identified. Figures should be submitted with a 300 dpi resolution when submitting electronically or printed on high-contrast glossy paper when submitting print copies. The abstract should be unstructured, and the introductory section should always include the objective and reason why the author is presenting this particular case. References should be up to date, preferably not exceeding 15.