

Leptin expression by heterotopic ossification-isolated tissue in rats with Achilles' tenotomy

Jun-Chang Xu, MD, PhD, Tao Wu, MD, PhD, Gui-Hua Wu, BSc, MSc, Zhao-Ming Zhong, MD, PhD, Yong-Zhi Tang, MD, PhD, Jian-Ting Chen, MD, PhD.

ABSTRACT

الأهداف: لبناء نماذج تعظم في غير موضعها (HO) بناء على (McClure)، ومن أجل تحديد ما إذا كان اللبتين LEP mRNA والبروتين قد ظهوروا في الأنسجة المعزولة لنماذج التعظم في غير موضعها (HO).

الطريقة: أجريت هذه الدراسة بالجامعة الطبية الجنوبية - بمدينة جونقزهو - الصين، خلال الفترة ما بين نوفمبر 2007م وحتى يونيو 2008م. تم تقسيم 36 ذكر جرذ بشكل عشوائي إلى مجموعات (شام) ومبضع جزئي للوتر الأخرس (PAT) ومبضع الوتر الأخرس (AT)، بعدد 12 جرذ لكل مجموعة. أجري الفحص بالأشعة السينية والفحص النسيجي على التوالي للتأكد من تشكل (HO) عند الأسبوع الخامس والأسبوع العاشر بعد العملية الجراحية. تم أخذ عينات من أنسجة الوتر الأخرس والأنسجة المحيطة. أثناء ذلك، تم فحص ظهور اللبتين (5, 10 w) mRNA (LEP) والبروتين 10w في الوتر الأخرس والأنسجة المحيطة على التوالي باستعمال طرق RT-PCR وتفاعل سلسلة الحمائر الناقلة النسيجية الكيميائية المناعية.

النتائج: لم يكن هنالك (mRNA) LEP وظهور للبروتين في شام وظهور ضعيف في (PAT) للوتر الأخرس والنسيج المحيط، بينما كان هنالك ظهور قوي في (AT) الوتر الأخرس.

خاتمة: على الأرجح إن اللبتين (LEP) يتدخل في تشكيل (HO) وترتبط آلية عمله في تحفيز تشكيل العظم والنضوج عن طريق سلسلة من الأحداث الخلوية بما فيها: التكاثر/التمييز للعديد من أنواع الخلايا وتركيب الكوليجين وتمعدن وتكوين الأوعية للقلب خارج الخلايا.

Objectives: To set up heterotopic ossification (HO) models according to McClure and determine whether leptin messenger ribonucleic acid (mRNA) and protein are expressed in HO-isolated tissue.

Methods: This study was performed in the Department of Spine and Orthopedics, Southern Medical University,

Guangzhou, China from November 2007 to June 2008. Thirty-six male rats were randomly divided into sham, partial achilles' tenotomy (PAT), and achilles' tenotomy (AT) groups, with 12 rats in each group. X-ray and histological examination were carried out to ensure the formation of HO at 5 and 10 weeks after operation. Specimens from achilles tendons and surrounding tissue were taken and processed. Meanwhile, the expression of leptin mRNA (5 and 10 weeks) and protein (10 weeks) in achilles tendons and the surrounding tissue were examined respectively using reverse transcription-polymerase chain reaction assay and immunohistochemical methods.

Results: There were no leptin mRNA and protein expression in the sham and a weak expression in the PAT of Achilles tendons and surrounding tissue, whereas there was strong expression in the AT group.

Conclusion: Leptin is involved in the formation of HO, its mechanisms is related to induction of bone formation and maturation through a series of cellular events, including: proliferation/differentiation of many kinds of cells, collagen synthesis, mineralization, and vascularization of the extracellular matrix.

Saudi Med J 2009; Vol. 30 (5): 605-610

From the Department of Spine & Orthopedics (Xu, Zhong, Tang, Chen), Department of Orthopedics & Traumatology (Wu T), Nanfang Hospital of Southern Medical University, Guangdong Province, Department of Orthopedics (Xu), Xiangfan Central Hospital, Hubei Province, and the Department of General Surgery (Wu G), Affiliated Hospital of Xiangfan Vocational and Technical College, Hubei Province, China.

Received 5th November 2008. Accepted 15th April 2009.

Address correspondence and reprint request to: Dr. Jian-Ting Chen, Department of Spine & Orthopedics, Nanfang Hospital of Southern Medical University, Guangzhou 510515, Guangdong Province, China. Tel. +86 (20) 87640940. Fax. +86 (20) 87640940. E-mail: doctorchenjt@163.com

Heterotopic ossification (HO) is a condition characterized by the formation of bone in soft tissues other than skeletal system, which is usually seen in the cases of musculoskeletal trauma, spinal cord or central nervous system damage, joint dislocations and surgical procedures such as hip, knee, shoulder, or elbow arthroplasty, and internal fixation after fractures.²⁻⁵ Heterotopic ossification may cause pain, decrease motion; in severe cases, complete joint ankylosis could happen whereby surgical intervention follows.⁶ The process of HO may include appropriate differentiation of pluripotent mesenchymal cells that generally exist in soft tissues into bone-forming cells under the influence of various growth factors, including bone morphogenetic proteins (BMPs), transforming growth factor-beta (TGF- β), basic fibroblast growth factor (bFGF), insulin-like growth factor (IGF) and so on.⁷⁻¹⁰ However, the exact etiology of HO remains unclear, recently, leptin and its receptor have been revealed a bone-conditioning factor, spread widely in a variety of body tissues, suggesting that leptin may be involved in many aspects of metabolic regulation.¹¹ The role of leptin is worth more attention. Current research has focused on leptin in the pathogenesis of osteoporosis and osteoarthritis, and whether leptin is involved in the formation of HO is yet to confirmed. In the present study, we set up HO models according to McClure, and determined the expression of leptin mRNA (5 and 10 weeks) and protein (10 weeks) in HO-isolated tissue respectively using reverse transcription-polymerase chain reaction (RT-PCR) assay and immunohistochemical methods to explore the potential role of leptin in the formation of HO.

Methods. Goat serum was provided by Sigma-aldrich Corporation (St Louis, USA), rabbit anti-rat leptin antibody and biotinylated goat anti-rabbit were purchased from Santa Cruz Biotechnology (Santa Cruz, USA), streptavidin peroxidase conjugation (SP) and diaminobenzidine (DAB) were provided by Dakocytomation (Carpenteria, USA), Healthy Sprague-Dawley (SD) rats (adult male, 250 \pm 30 g) were supplied by the Department of Laboratory Animal Center of Southern Medical University, Guangzhou, China.

Groups and experimental protocols. The experiment was performed in the Southern Medical University, Guangzhou, China from November 2007 to June

2008. All animal experimental protocols were approved by the Animal Care and Use Committee of Southern Medical University and conformed to the National Institutes of Health Guidelines. Thirty-six Sprague-Dawley rats (male, 250 \pm 30 g), purchased and bred in the Department of Laboratory Animal Center of Southern Medical University, Guangzhou, China were initially left to adjust to the laboratory environment for 7 days, then randomly divided into 3 groups: sham, partial achilles' tenotomy (PAT) and Achilles' tenotomy (AT) (n=12 rats each). All surgical procedures were performed under general anesthesia induced by an intraperitoneal injection of sodium pentobarbital (30 mg/kg) and with aseptic techniques. Once anesthetized, for rats in the sham group, incision and saturation were merely performed on the left leg; PAT were performed on the left achilles tendon. The AT group underwent left midpoint AT to build up HO models through a posterior approach according to the description of McClure.¹ Incisions were routinely sutured with an interrupted 4-0 silk suture.

Radiographic and histological analysis. High-resolution radiographs (projective conditions: 42KV, 100MA, exposure time 0.12s) of both hindlimbs were taken at 5 and 10 weeks after surgery to investigate the formation of HO. Meanwhile, 6 rats from each group were randomly selected and sacrificed; the achilles tendons were dissected and inspected. Subsequently half of the samples were immediately fixed in 10% formalin and decalcified in 10% ethylenediaminetetraacetic acid (EDTA) (pH 7.0) for one week. After dehydration and embedding in paraffin, the sagittal central sections of the Achilles tendons were cut at 3 μ m thickness. The slides were then stained with both hematoxylin-eosin (HE) and Masson and examined under a light microscope.

Messenger ribonucleic acid (mRNA) extraction and reverse transcriptase polymerase chain reaction (RT-PCR). Rats were sacrificed at 5 and 10 weeks after operation, the Achilles tendons and surrounding soft tissue were obtained. The other half of the tissue (0.5-1 g) were homogenized in 5-10 ml 0.9% saline solution. The homogenate was then centrifuged at 3,000 rpm for 10 minutes at 4°C. The supernatants were collected for assaying. The total cellular RNA was isolated from the tissue of each rat using Trizol reagent following the protocol recommended by the manufacturer. Leptin expression was analyzed by RT-PCR.^{6,8} Glyceraldehyde 3-phosphate dehydrogenase was used as an internal control. Primers used for leptin (316 bp) were 5'-CCA GGA TGA CAC CAA AAC CCT C-3' (upstream) and 5'-ATC CAG GCT CTC TGG CTT CTG C-3' (downstream). Primers used for GAPDH (580bp) were 5'-AAT CCC ATC ACC ATC TTC CA -3' (upstream) and 5'-CCT GCT TCA CCA CCT TCT TG-3' (downstream). The PCR ran 35 cycles as 95°C \rightarrow 56°C \rightarrow 72°C, 30 seconds for each step. After the RT-

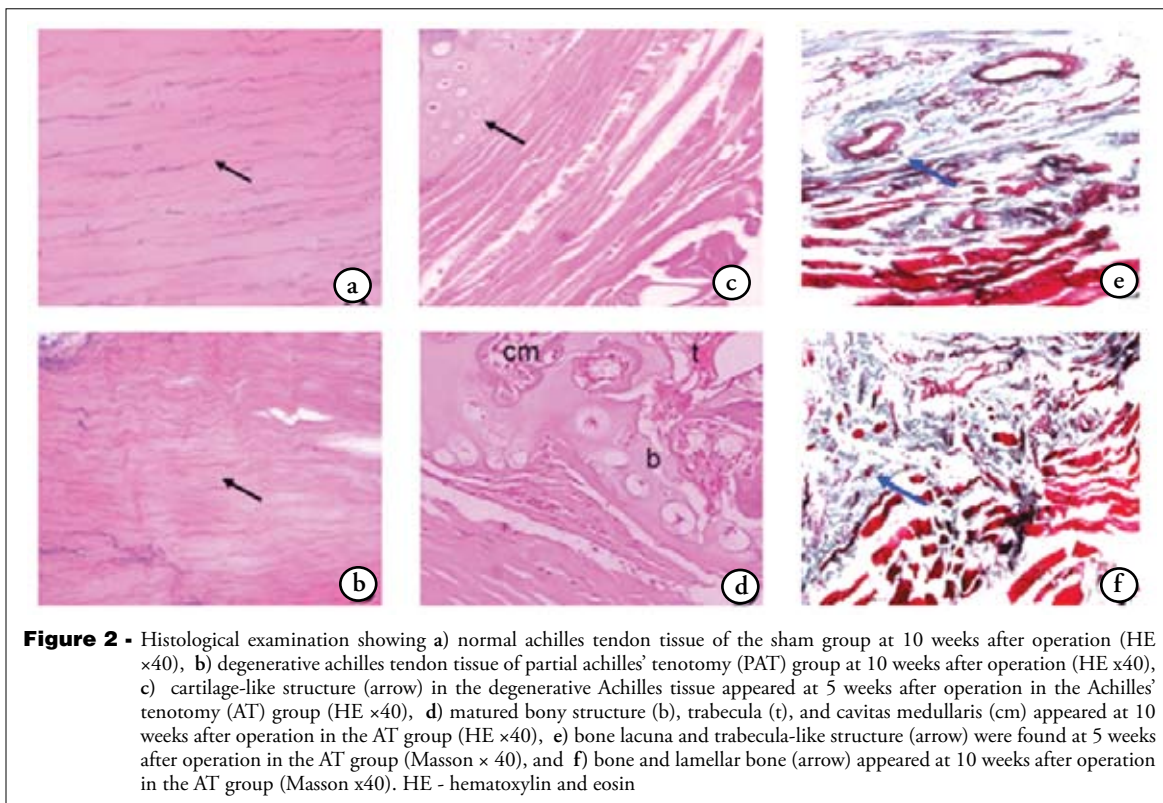
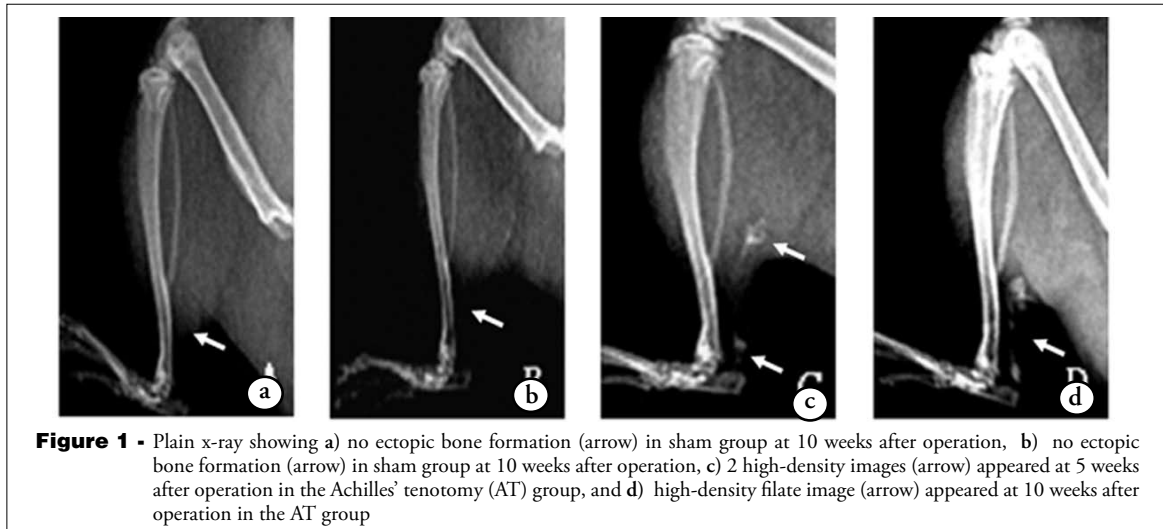
Disclosure. This study was supported by the Natural Science Foundation of Guangdong Province, China (No. 06024394).

PCR reaction, the PCR products of leptin and GAPDH were analyzed by 1.5% agarose gel electrophoresis.

Leptin immunodetection. Slides were deparaffinized in xylene and hydrated through graded alcohols to distilled water (dH₂O). Endogenous peroxidase was blocked using 3% H₂O₂, and slides were incubated with 10% normal goat serum for 10 minutes. The reagent was blown off the slides and not rinsed. Slides were incubated for 2 hours with the rabbit anti-rat leptin antibody at a 1:25 dilution. Negative controls were processed in the

absence of the primary antibody. Secondary antibody was biotinylated goat anti-rabbit diluted 1:100 for one hour followed by SP for 10 minutes and DAB for 5 minutes. Slides were removed from the stainer, rinsed in water, counterstained with light green, dehydrated, cleared, and mounted with resinous mounting media.

Results. Radiographic examination. At 5 and 10 weeks after operation, x-ray films showed no ectopic bone formation in the sham and PAT groups, in the



AT group, 2 high-density images occurred on the plain x-ray at 5 weeks after tenotomy, and high-density filate image presented at 10 weeks (Figure 1).

Histological examination. Specimens of the AT group showed cartilage and bone formation at 5 weeks after tenotomy, showed matured bony structure, bone trabecula, and bone medullary cavity at 10 weeks after tenotomy; by contrast, in the sham and PAT groups

chondrification did not occur at 5 and 10 weeks (Figure 2).

Expression of leptin mRNA. Results of leptin mRNA expression are presented in Figure 3. There were no leptin mRNA expression detectable in the sham group and moderate expression in PAT of Achilles tendons and surrounding soft tissue, whereas there was a strong expression of leptin mRNA in HO-isolated tissue of AT rats at 5 and 10 weeks after surgery (Figure 3).

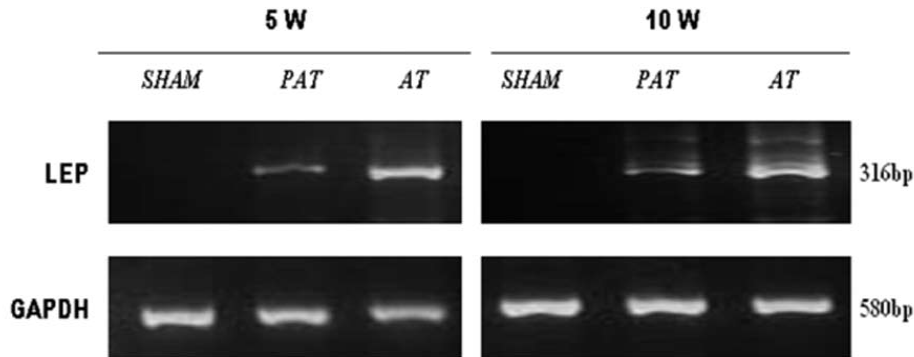


Figure 3 - The expression of leptin mRNA. There was no leptin (LEP) mRNA expression in the sham group and moderate band in the partial achilles' tenotomy (PAT) group of achilles tendons and surrounding soft tissue, whereas there was a strong band of heterotopic ossification (HO) - isolated tissue in the achilles' tenotomy (AT) rats at 5 and 10 weeks after surgery. GAPDH - Glyceraldehyde 3- phosphate dehydrogenase

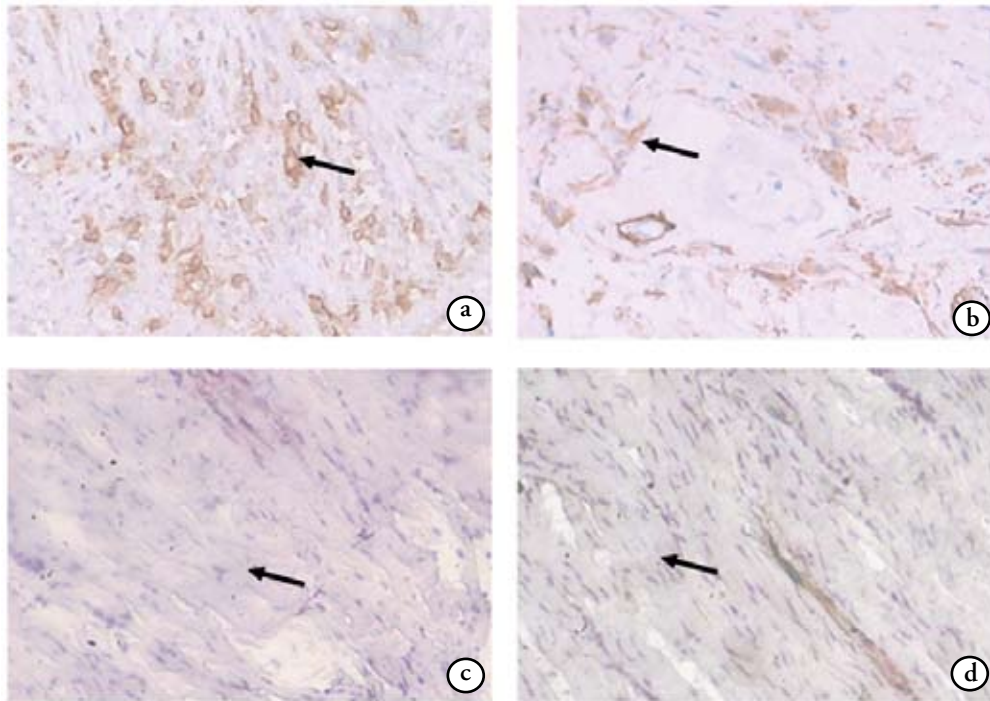


Figure 4 - Immunohistochemical staining showing a) strong positive staining (arrow) for leptin of the Achilles tendons in the achilles' tenotomy group at 10 weeks after operation ($\times 400$); b) weak immunostaining (arrow) for leptin is seen in the partial achilles' tenotomy group ($\times 400$); c) no immunoreactivity (arrow) for leptin is detected in the sham group ($\times 400$), and d) no staining (arrow) in achilles tendons tissue processed as a negative control ($\times 400$).

Immunohistochemical staining. Results of Immunohistochemical staining, for leptin are illustrated in Figure 4. There were a strong positive staining for leptin in AT and weak immunostaining in PAT of Achilles tendons at 10 weeks after operation. In contrast, no immunoreactivity for leptin in sham were detected and no staining in Achilles tendons tissue processed as a negative control (Figure 4).

Discussion. Heterotopic ossification continues to pose a substantial challenge to the orthopedic surgeon, particularly in the fields of trauma and arthroplasty. Similar to the formation of callus, HO initially manifests as highly metabolically active woven bone in the soft tissue, then matures into lamellar bone, containing osteoblasts and osteoclasts, often with true marrow.¹² Creation of an animal model that mimics human clinical scenarios is necessary for investigators to understand the biochemical mechanism(s) underlying these phenomena. In this paper, we have successfully established an HO model through AT, specimens of the AT group presented cartilage and bone formation with trabecular bone, this HO occurred through a process of endochondral ossification. The results from this study were identical to a similar experiment by McClure.¹ This model was selected because it consistently leads to the formation of ectopic new bone, which is morphologically and radiologically similar to traumatic HO in humans, and it appears to be more realistic in approximating the clinical setting of HO than other models. The pathogenesis of HO is complicate with multiple etiologies. It requires osteoinductive factors, inducible osteoprogenitors, and a favorable micro-environment.^{7,13} Numerous previous studies concerning inductive factors have been performed to understand the HO etiology, which focused on BMPs, TGF- β , bFGF and so forth. There are still some signaling factors involved. Leptin is a polypeptide hormone comprised of 167 amino acids and secreted primarily by white adipose tissue. The widespread expression of leptin and its receptor within various cells and tissues,¹⁴⁻¹⁶ suggests that leptin may be involved in a variety of metabolic regulations.¹⁷ It is known that leptin acts not only as a major regulator of appetite and energy expenditure,¹⁸ but also as an endocrine hormone regulating bone metabolism.¹⁹⁻²¹ Our genetic and immunohistochemistry studies found no leptin mRNA and protein expression in sham and a weak expression in PAT of Achilles tendons and surrounding tissue, whereas there was a strong expression of HO-isolated tissue in AT. In previous studies, leptin has been shown to induce bone formation and maturation through a series of cellular events, including mesenchymal cell proliferation and differentiation,²² osteoblasts

proliferation,²³ fibroblast proliferation and collagen synthesis,²⁴ increased mineralization of the extracellular matrix,^{11,24,25} cartilage formation, and vascularization.^{26,27} Furthermore, vascularization is an essential procedure for bone and cartilage formation.^{26,28} All these procedures have physiological and pathological effects and play an important role in bone formation and remodeling.²⁸ Local higher levels of leptin and other inductive factors stimulate primordial mesenchymal cells in Achilles tendons and surrounding tissue to differentiate into osseous progenitor cells. Subsequent differentiation into osteoblasts occurs. With further stimulation, these osteoblasts produce considerable alkaline phosphatase and collagen. This osteoid matrix subsequently calcifies, forming mature appearing bone.

In conclusion, the present results revealed differences at the tissue level in animals with PAT or AT when compared to their controls. There was differential expression of the leptin gene and protein by HO-isolated tissue, which may be effective evidence that leptin is at least partly responsible for the ectopic bone formation. However, due to a deficiency in the immuno-detection of leptin receptors in the present study, further work would be performed in these fields to increase understanding of the pathways and mechanisms, the results of such studies will aid in the understanding of the functional roles of leptin for HO.

Acknowledgment. We gratefully acknowledge the advice and assistance of Professor Jian-Ting Chen in the experiments.

References

1. McClure J. The effect of diphosphonates on heterotopic ossification in regenerating Achilles tendon of the mouse. *J Pathol* 1983; 139: 419-430.
2. Young NP, O'Driscoll SW, Crum BA. Heterotopic ossification of muscle and nerve: an unusual cause of painful mononeuropathy. *J Clin Neuromuscul Dis* 2009; 10: 135-137.
3. Pakos EE, Ioannidis JP. Radiotherapy vs. nonsteroidal anti-inflammatory drugs for the prevention of heterotopic ossification after major hip procedures: a meta-analysis of randomized trials. *Int J Radiat Oncol Biol Phys* 2004; 60: 888-895.
4. Tsailas PG, Babis GC, Nikolopoulos K, Soucacos PN, Korres DS. The effectiveness of two COX-2 inhibitors in the prophylaxis against heterotopic new bone formation: an experimental study in rabbits. *J Surg Res* 2009; 151: 108-114.
5. da Paz AC, Carod Artal FJ, Kalil RK. The function of proprioceptors in bone organization: A possible explanation for neurogenic heterotopic ossification in patients with neurological damage. *Med Hypotheses* 2007; 68: 67-73.
6. Chauveau C, Devedjian JC, Blary MC, Delecourt C, Hardouin P, Jeanfils J, et al. Gene expression in human osteoblastic cells from normal and heterotopic ossification. *Exp Mol Pathol* 2004; 76: 37-43.
7. Liu K, Tripp S, Layfield LJ. Heterotopic ossification: Review of histologic findings and tissue distribution in a 10-year experience. *Pathol Res Pract* 2007; 203: 633-640.

8. Scherbel U, Riess P, Khurana J, Born C, Delong W. Expression of bone morphogenic proteins in rats with and without brain injury and a tibial fracture. *The University of Pennsylvania Orthopaedic Journal* 2001; 14: 85-89.
9. Teplyuk NM, Haupt LM, Ling L, Dombrowski C, Mun FK, Nathan SS, et al. The osteogenic transcription factor Runx2 regulates components of the fibroblast growth factor/proteoglycan signaling axis in osteoblasts. *J Cell Biochem* 2009; 107: 144-154.
10. Morley J, Marsh S, Drakoulakis E, Pape HC, Giannoudis PV. Does traumatic brain injury result in accelerated fracture healing? *Injury* 2005; 36: 363-368.
11. Hla MM, Davis JW, Ross PD, Wasnich RD, Yates AJ, Ravn P, et al. A multicenter study of the influence of fat and lean mass on bone mineral content: evidence for differences in their relative influence at major fracture sites. *Am J Clin Nutr* 1996; 64: 354-360.
12. Sawyer JR, Myers MA, Rosier RN, Puzas JE. Heterotopic ossification: clinical and cellular aspects. *Calcif Tissue Int* 1991; 49: 208-215.
13. Lounev VY, Ramachandran R, Wosczyzna MN, Yamamoto M, Maidment AD, Shore EM, et al. Identification of progenitor cells that contribute to heterotopic skeletogenesis. *J Bone Joint Surg Am* 2009; 91: 652-663.
14. Cornish J, Callon KE, Bava U, Lin C, Naot D, Hill BL, et al. Leptin directly regulates bone cell function in vitro and reduces bone fragility in vivo. *J Endocrinol* 2002; 175: 405-415.
15. Gruber HE, Ingram JA, Hoelscher GL, Hanley En Jr. Leptin expression by annulus cells in the human intervertebral disc. *Spine J* 2007; 7: 437-443.
16. Lin J, Barb CR, Matteri RL, Kraeling RR, Chen X, Meinersmann RJ, et al. Long form leptin receptor mRNA expression in the brain, pituitary, and other tissues in the pig. *Domest Anim Endocrinol* 2000; 19: 53-61.
17. Hamrick MW, Della Fera MA, Choi YH, Hartzell D, Pennington C, Baile CA. Injections of leptin into rat ventromedial hypothalamus increase adipocyte apoptosis in peripheral fat and in bone marrow. *Cell Tissue Res* 2007; 327: 133-141.
18. Magni P, Motta M, Martini L. Leptin: a possible link between food intake, energy expenditure, and reproductive function. *Regul Pept* 2000; 92: 51-56.
19. Thomas T, Martin A. Bone metabolism and energy balance: role for leptin. *Joint Bone Spine* 2005; 72: 471-473.
20. Włodarski K, Włodarski P. Leptin as a modulator of osteogenesis. *Ortop Traumatol Rehabil* 2009; 11: 1-6.
21. Gad HI. The potential osteogenic effects of systemic leptin and insulin administration in streptozotocin-induced diabetic female rats. *Saudi Med J* 2007; 28: 1185-1190.
22. Astudillo P, Rios S, Pastenes L, Pino AM, Rodriguez JP. Increased adipogenesis of osteoporotic human-mesenchymal stem cells (MSCs) characterizes by impaired leptin action. *J Cell Biochem* 2008; 103: 1054-1065.
23. Thomas T, Gori F, Khosla S, Jensen MD, Burguera B, Riggs BL. Leptin acts on human marrow stromal cells to enhance differentiation to osteoblasts and to inhibit differentiation to adipocytes. *Endocrinology* 1999; 140: 1630-1638.
24. Li P, Jin H, Liu D, Wang XY, Xu Z, Nan W, et al. Study on the effect of Leptin on fibroblastic proliferation and collagen synthesis in vitro in rats. *Zhongguo Xiufu Chongjian Waikie Zazhi* 2005; 19: 20-22.
25. Gordeladze JO, Drevon CA, Syversen U, Reseland JE. Leptin stimulates human osteoblastic cell proliferation, de novo collagen synthesis, and mineralization: Impact on differentiation markers, apoptosis, and osteoclastic signaling. *J Cell Biochem* 2002; 85: 825-836.
26. Talavera-Adame D, Xiong Y, Zhao T, Arias AE, Sierra-Honigmann MR, Farkas DL. Quantitative and morphometric evaluation of the angiogenic effects of leptin. *J Biomed Opt*. 2008; 13: 064017.
27. Murad A, Nath AK, Cha ST, Demir E, Flores-Riveros J, Sierra-Honigmann MR. Leptin is an autocrine/ paracrine regulator of wound healing. *FASEB J* 2003; 17: 1895-1897.
28. Kakudo N, Kusumoto K, Wang YB, Iguchi Y, Ogawa Y. Immunolocalization of vascular endothelial growth factor on intramuscular ectopic osteoinduction by bone morphogenetic protein-2. *Life Sci* 2006; 79: 1847-1855.

Related topics

Sanlier N. The effect of body composition on blood lipids, leptin, bone mineral density, and nutrition in females. *Saudi Med J* 2008; 29: 1636-1642.

Shafi R, Afzal MN. Status of serum leptin levels in females with infertility. *Saudi Med J* 2008; 29: 1419-1422.

Gad HI. The potential osteogenic effects of systemic leptin and insulin administration in streptozotocin-induced diabetic female rats. *Saudi Med J* 2007; 28: 1185-1190.

Kayardi M, Icagasioglu S, Yilmaz A, Candan F. Serum leptin levels and malnutrition in patients with chronic renal failure. *Saudi Med J* 2006; 27: 477-481.