

# Successful thrombolytic therapy for stuck mitral mechanical valve

Hamoud Y. Obied, MD, JBCS, Mohammed F. Ibrahim, FRCS (C/Th), Bendehiba S. Latroche, MD, FESC, Maya M. Mroue, PharmD.

## ABSTRACT

بعد تخثر الصمامات المعدنية البديلة من المضاعفات الخطيرة ولحسن الحظ أنها غير شائعة لدى عمليات استبدال صمامات القلب. نعرض هنا حالة تجلط صمام معدني تم وضعه بدل الصمام التاجي من النوع (On-X 31/33 mm)، وقد بلغ حجم الخثرة (thrombus size 8×14 mm)، تمت معالجته بنجاح باستخدام مادة الإستربتوكينيز عن طريق الوريد مرتين لمدة 10 ساعات ودون حدوث مضاعفات.

Thrombosis of a mechanical prosthetic valve is a serious and fortunately it is a rare complication of cardiac valve replacement. We present a case of prosthetic mechanical valve (On-X 31/33 mm) thrombosis (thrombus size 8×14 mm) on a mitral position, which was treated with a successful intravenous thrombolytic therapy of streptokinase infusion over 10 hours repeated twice with no complications.

*Saudi Med J 2009; Vol. 30 (7): 964-966*

*From the Prince Salman Heart Center, King Fahad Medical City, Riyadh, Kingdom of Saudi Arabia.*

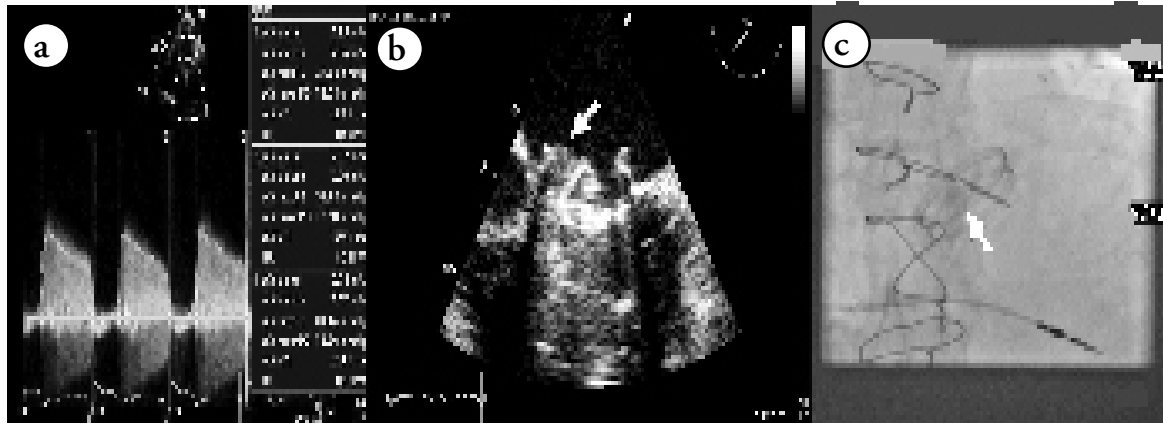
*Received 8th April 2009. Accepted 8th June 2009.*

*Address correspondence and reprint request to: Dr. Hamoud Y. Obied, Prince Salman Heart Center, King Fahad Medical City, PO Box 59046, Riyadh 11525, Kingdom of Saudi Arabia. Tel. +966 (1) 2889999. Ext. 1110. Fax. +966 (1) 2889999. Ext. 1112. E-mail: obeidha@yahoo.com*

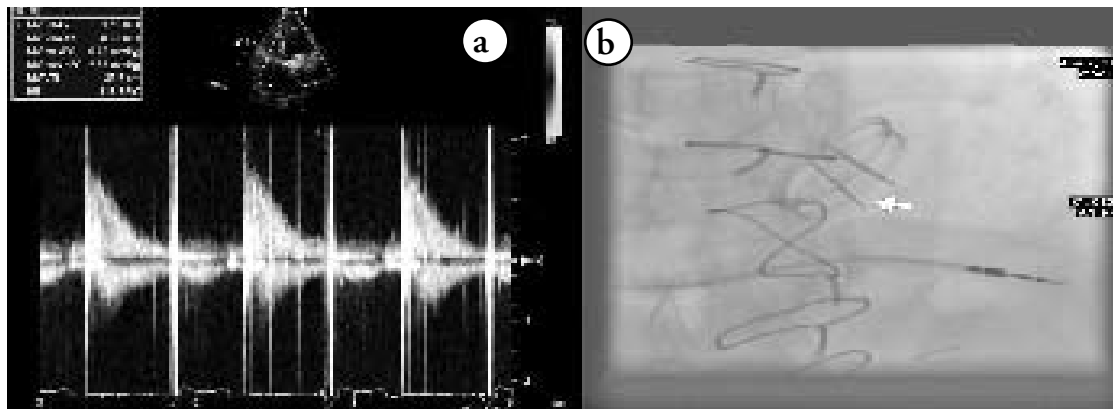
Prosthetic valve thrombosis (PVT) continues to be a rare, but a life threatening complication.<sup>1,2</sup> Surgery has been the traditional management of choice, but thrombolysis has recently been proposed as a first-line therapy.<sup>3</sup> We report a case of a thrombosed mechanical mitral valve, which was successfully treated with intravenous thrombolytic therapy with Streptokinase infusion for 10 hours twice followed by heparin infusion, a total of 20 hours. We present this case in order to show that thrombolytic therapy is a safe

and successful method of treatment in a thrombosed mechanical valve.

**Case Report.** A 65-year-old male patient, known hypertensive and with ischemic heart disease, had coronary artery bypass grafting and mechanical mitral valve replacement (On-X size 31/33 mm Medical Carbon Research Institute, LCC, Austin, Texas 78754, USA) 2 years ago. He had also permanent pacemaker inserted 7 years ago for complete heart block. He presented to the emergency room in our hospital on January, 2009 complaining of exertional shortness of breath for the past 2 weeks, which became worse in the last 2 days without chest pain or cough. Upon examination, the patient was conscious and oriented, his blood pressure was 95/56 mm Hg and his heart rate was 63 per minute in atrial fibrillation, and an oxygen saturation of 98% on room air. Chest examination revealed bilateral basal crepitation, his heart examination showed weak clicky sound of the mitral prosthesis and had mild lower limb edema. The electrocardiography showed rate controlled atrial fibrillation and ventricular pacing. Laboratory investigations were within normal limit except for an international normalized ratio (INR), which was 1.8 on warfarin 2.5 mg daily. He was admitted as a case of congestive heart failure to rule out mitral valve dysfunction. Transthoracic echocardiography (TTE) showed a poor left ventricular function with ejection fraction of 30% and abnormal transvalvular gradient, 35/18 mm Hg at heart rate of 60/mn (Figure 1a). Transesophageal echocardiography (TEE) showed a stucked anterior leaflet with the presence of a large thrombus (8×14 mm) on the left atrial side of the prosthesis (Figure 1b). Fluoroscopy (Figure 1c) showed anterior leaflet blocked in semi open position, posterior leaflet partially blocked. The patient received streptokinase 500,000 IU bolus and an infusion of 1,500,000 IU over 10 hours followed by heparin infusion to keep activated partial thromboplastin time ranging between 60 and 70.<sup>4</sup> A follow up TTE showed decrease in mean gradient from 18-8 mm Hg at same heart rate. We decided to give the patient another cycle



**Figure 1** - Pre-thrombolytic **a**) CW Doppler apical 4 chamber, abnormal gradient across MV prosthesis 35/18 mm Hg at HR 60/mn. **b**) TEE mid esophageal 40 degrees, large clot (8X14mm) seated on the top of the anterior leaflet (Arrow). **c**) Fluoroscopy, AP-cranial pre thrombolytic, anterior leaflet blocked in semi open position (Arrow), posterior leaflet partially blocked. CW - continuous wave, MV - mitral valve, HR - heart rate, TEE - transesophageal echocardiography, AP - anteroposterior



**Figure 2** - Post-thrombolytic **a**) CW Doppler apical 4 chamber, 24 hours post thrombolytic, normalization of gradient across MV prosthesis 9/3 mm Hg at HR 60/mn. **b**) Fluoroscopy, AP-cranial, 24 hours post thrombolytic, both leaflets fully opened (Arrow). CW - continuous wave, MV - mitral valve, HR - Heart rate, AP - anteroposterior.

of Streptokinase 1,000,000 IU over 10 hours followed by heparin infusion. The third TTE (24 hours post thrombolytic therapy) showed complete disappearance of the thrombus and full mobilization of valvular leaflets with a mean gradient of 3 mm Hg. At the same heart rate, (Figure 2a) which was confirmed by fluoroscopy (Figure 2b), the patient remained hemodynamically stable with uneventful recovery and was discharged home after 6 days from admission in a good condition on Aspirin 81 mg, lisinopril 10 mg twice daily, Lipitor 40 mg, and warfarin 5 mg daily to keep his INR between 3 and 4 and to be followed up with TTE in the outpatient clinic.

**Discussion.** Thrombosis of a prosthetic valve is one of the most feared complications of cardiac valve replacement. The presenting clinical picture

ranges from the absence of symptoms to cardiogenic shock.<sup>5</sup> The TEE is the gold standard in diagnosis and treatment guidance.<sup>6</sup> The management of obstructive PVT remains widely debated due to lack of randomized controlled trials. The 2006 American College of Cardiology/American Heart Association guidelines state that fibrinolytic therapy for a left-sided PVT is commonly ineffective and risky (cerebral emboli occurs in 12-15% of cases).<sup>7,8</sup> Fibrinolytic therapy is recommended for patients with New York heart association (NYHA) classes III or IV and a small burden clot in whom surgical intervention carries a high risk and is contraindicated.<sup>9</sup> Surgical thrombectomy and valve replacement have been considered as the traditional management of choice with a hospital mortality ranging from 11-16%.<sup>7</sup> Thrombolytic therapy was recommended only for individuals who were poorly

surgical candidates or critically ill that is, in NYHA clinical classes III or IV. These authors were concerned by the high rate of systemic embolism associated with thrombolytic therapy.<sup>7</sup> Thrombolytic therapy has recently been proposed as a first-line therapy<sup>3</sup> in attempt to avoid the high rate of morbidity and mortality of surgery. Streptokinase and Alteplase are both available in our center; however, the patient received streptokinase based on case reports<sup>2,8</sup> and the result of case series (127 cases) where streptokinase, urokinase and recombinant tissue plasminogen activator were used and showed success rates of 57%, 36.6% and 43%. Partial success was obtained after the first 10 hours of thrombolytic infusion; after discussing the case with the treating physician, the decision was to challenge the patient with the same thrombolytic agent for another 10 hours without a bolus and at a lower infusion rate. Upon completion, TEE showed complete dissolution of the thrombus with full mobilization of valve's leaflets.

Despite thrombolytic therapy of PVT has an unpredictable risk of embolization and complications, it represents an alternative to surgery with 84% success and low complication rates (stroke 9%, mortality 5%).<sup>9,10</sup>

## References

1. Lengyel M, Horstkotte D, Voller H, Mistiaen WP. Working Group Infection, Thrombosis, Embolism and Bleeding of the Society for Heart Valve Disease. *J Heart Valve Dis* 2005; 14: 567-575.
2. Kumar S, Garg N, Tewari S, Kapoor A, Goel PK, Sinha N. Role of thrombolytic therapy for stuck prosthetic valves: a serial echocardiographic study. *Indian Heart J* 2001; 53: 451-457.
3. Das M, Twomey D, Al Khaddour A, Dunning J. Is thrombolysis or surgery the best option for acute prosthetic valve thrombosis? *Interact CardioVasc Thorac Surg* 2007; 6: 806-811.
4. Roudaut R, Lafitte S, Roudaut MF, Courtault C, Perron JM, Jaïs C, et al. Fibrinolysis of mechanical prosthetic valve thrombosis: a single-center study of 127 cases. *J Am Coll Cardiol* 2003; 41: 653-658.
5. Cáceres-Lóriga FM, Pérez-López H, Santos-Gracia J, Morlans-Hernandez K. Prosthetic heart valve thrombosis: pathogenesis, diagnosis and management. *Int J Cardiol* 2006; 110: 1-6.
6. Lengyel M. Management of prosthetic valve thrombosis. *J Heart Valve Dis* 2004; 13: 329-334.
7. Bonow RO, Carabello BA, Chatterjee K, de Leon AC, Faxon DP, Freed MD, et al. ACC/AHA 2006 Guidelines for the Management of Patients With Valvular Heart Disease: Executive Summary: A Report of the American College of Cardiology/American Heart Association Task Force on Practice Guidelines. *Circulation* 2006; 114: 450-527.
8. Lengyel M, Fuster V, Keltai M, Roudaut R, Schulte HD, Seward JB, et al. Guidelines for management of left-sided prosthetic valve thrombosis: a role for thrombolytic therapy. Consensus Conference on Prosthetic Valve Thrombosis. *J Am Coll Cardiol* 1997; 30: 1521-1526.
9. Tong AT, Roudaut R, Ozkan M, Sagie A, Shahid MS, Pontes Júnior SC, et al. Transesophageal echocardiography improves risk assessment of thrombolysis of prosthetic valve thrombosis: results of the international PRO-TEE registry. *J Am Coll Cardiol* 2004; 43: 77-84.
10. Ozkan M, Kaymaz C, Kirma C, Sönmez K, Ozdemir N, Balkanay M, et al. Intravenous thrombolytic treatment of mechanical prosthetic valve thrombosis: a study using serial transesophageal echocardiography. *J Am Coll Cardiol* 2000; 35: 1881-1889.

## Case Reports

Case reports will only be considered for unusual topics that add something new to the literature. All Case Reports should include at least one figure. Written informed consent for publication must accompany any photograph in which the subject can be identified. Figures should be submitted with a 300 dpi resolution when submitting electronically or printed on high-contrast glossy paper when submitting print copies. The abstract should be unstructured, and the introductory section should always include the objective and reason why the author is presenting this particular case. References should be up to date, preferably not exceeding 15.