

Airway management for cervical spine injury

Ahsan K. Siddiqui, MBBS, MD.

ABSTRACT

يهدف هذا البحث إلى مناقشة العوامل المهمة التي لها علاقة بالمعالجة الأولية، و التشخيص، ومعالجة الطرق الهوائية، وإجراءات التخدير للمرضى المصابين بأذية في النخاع الشوكي الرقبى (CSI). أن التشخيص المبكر و التقييم السريري له أهمية في نفي أذية النخاع الشوكي. يقلل تثبيت النخاع حركة النخاع الرقبى. يقدم التثبيت الرغامي بواسطة المنظار اللبني الراحة والسلامة للمريض، ولكن في حالة التدهور الشديد في العلامات الحيوية، يجب أن يتم التثبيت بدون أي تأخير في مكان الحادث أو في غرفة الطوارئ. تدبير الطريق الهوائي و المحافظة على ثبات النخاع الرقبى هي عوامل مهمة في تخفيف خطورة الأذية العصبية الثانوية أكثر من أي تقنية أخرى. الرأي الحالي هو أن التثبيت الفموي بعد المباشرة الوريدية و استخدام المرخيات العضلية مع تثبيت النخاع الرقبى هو أكثر سلامة و أسرع لانجاز التثبيت للمريض متوقع لديه أذية في النخاع الشوكي الرقبى (CSI). معالجة الطرق الهوائية و المحافظة على ثبات النخاع الرقبى هي عوامل مهمة في تخفيف خطورة الأذى العصبي الثانوي أكثر من أي تقنية أخرى. يرى الرأي العام أن التثبيت الفموي بعد المباشرة الوريدية و استخدام المرخيات العضلية مع تثبيت النخاع الرقبى هي من أكثر الطرق سلامة و سرعة لانجاز التثبيت لمريض يتوقع لديه أذى في النخاع الشوكي الرقبى (CSI).

In this review, important factors related to initial management, diagnosis, airway, and anesthetic management of patients with cervical spine injury (CSI) are discussed. Early diagnostic and clinical evaluation is important in excluding CSI. In-line stabilization reduces movement of the cervical spine. Tracheal intubation under fiberoptic control, offers safety, and comfort to the patient. However, in cases of severe deterioration of vital functions, intubation must be performed without any delay at the site of the accident or in the emergency room. Early airway management and maintenance of spinal immobilization are more important factors in limiting the risk of secondary neurological injury than any particular technique. The current opinion is that oral intubation after intravenous induction of anesthesia and muscle relaxation along with in-line stabilization is the safest and quickest way to achieve intubation in a patient with suspected CSI.

Saudi Med J 2009; Vol. 30 (9): 1133-1137

From the Department of Anesthesiology, King Fahd Hospital of the University, King Faisal University, Al-Khobar, Kingdom of Saudi Arabia.

Address correspondence and reprint request to: Dr. Ahsan K. Siddiqui, Department of Anesthesiology, PO Box 40081, King Fahd Hospital of the University, King Faisal University, Al-Khobar, Kingdom of Saudi Arabia. E-mail: ahsansiddiqui@hotmail.com

Cervical spine injuries (CSIs) occur in 2-5% of blunt trauma patients and of these, 7-14% are unstable. Anesthesiologists are often involved in the initial resuscitation and management of trauma victims with possible CSIs. The purpose of this review is to increase awareness of the advantages and disadvantages of the possible techniques so that the safest method can be chosen for the airway management of patients with potential or confirmed CSI. The goals of resuscitation should be stabilization of the cervical spine, prevention of secondary injuries, and reduction of fracture as soon as possible to protect the spinal cord. The blood circulation of the spinal cord is more vulnerable to injury than of brain. We will review the recent guidelines for clearing the cervical spine in alert patients and those with altered mental status and update techniques for airway management in detail.

Epidemiology. Cervical spine injuries involve people of all age, but most commonly between the ages of 15-45 years; approximately 70% occur in men. However, there is an increased prevalence of CSI among the elderly, probably due to osteoporosis. The type of accidents include motor vehicle accidents (50-70%), falls (6-10%), diving accidents, blunt head and neck traumas, penetrating neck injuries, and contact sports injuries. The National Emergency X-Radiography Utilization Study (NEXUS) database provides important data on different types of CSI sustained after blunt trauma.¹ Of the 34,069 patients enrolled in the NEXUS project, 818 patients sustained 1195 fractures and 231 subluxations or dislocations. The most common level fractured was C2, which accounted for 24% of fractures (Figure 1). Dislocation occurred most commonly at the C5/6 and C6/7 levels (Figure 2). Fractures of the vertebral body and the odontoid peg are also common and are most likely to be associated with instability.¹

Missed diagnosis. Missed CSIs can have disastrous consequences if not detected early. The incidence of missed or delayed diagnosis is 1-5%, up to 30% of patients developing secondary neurological damage. The most common causes of missed injuries are a failure to obtain adequate plain x-rays and incorrect interpretation of the films. Injuries to the C2 level and to the lamina and posterior elements are particularly likely to be missed.

Criteria for cervical spine clearance. A cervical spine injury should be suspected in all injury mechanisms involving blunt trauma. Patients with injury above the clavicles are at increased risk, and this risk increase 4-fold with clinically significant head injury (Glasgow coma scale <9). Cervical spine injury is often occult, and secondary injury to the cervical cord must be avoided. There is a consensus on the approach to the alert patient, but the best strategy for clearing the cervical spine in a patient with altered mental status is controversial. The Eastern Association for the Surgery of Trauma (EAST) has published guidelines for identifying CSIs after trauma.² Clinical criteria for the exclusion of CSIs have been proposed in order to reduce unnecessary x-ray exposure and cost. The NEXUS database has been used to test the validity of a set of 5 clinical criteria for clearing the cervical spine without the need for radiographs: no posterior midline cervical spine tenderness, no intoxication, alert, no focal neurological deficit, and no painful distracting injuries.³ The performance of this decision instrument was examined prospectively in 34,069 patients who underwent radiography of the cervical spine after blunt trauma. The decision tool identified all except 8 out of 818 patients who had CSIs. Only 2 of these patients had a clinically significant

injury. The trauma patients who do not satisfy clinical criteria for the exclusion of CSIs should have 3-view cervical radiography: a lateral cross-table view revealing the base of the occiput to the first thoracic vertebrae, an anterior-posterior view, and an open-mouth odontoid view revealing the lateral masses of the first cervical vertebra and entire odontoid process.⁴ All 7 vertebrae must be examined because 20-30% of all cervical spine injuries are at C7. Putting the arms and shoulders caudal may be necessary to see C7. Axial CT scans: with sagittal reconstruction are required for any areas that cannot be visualized or suspicious. We can assess the stability of the cervical spine by flexion/extension fluoroscopy. This approach is recommended in the updated EAST guidelines for trauma patients with altered mental status not expected to regain full consciousness for more than 2 days.⁵ Magnetic resonance scan of the cervical spine may reveal the ligament injury without the need to stress the spine, but it is expensive and technically difficult in patients undergoing invasive monitoring, or who are too severely ill to be in the scanner for a long time. Although MRI is highly sensitive for detecting soft tissue injuries, fractures in the posterior elements can easily be missed.

Spinal cord injury without radiological abnormality (SCIWORA). It is a well-recognized condition in children, but rare in adults. A relatively large head, mobile cervical spine, and lax ligament make the cord vulnerable during blunt trauma. The most likely pattern of injury associated with SCIWORA is the central cord syndrome, which presents with weakness in the limbs, worse in the arms, with a variable amount of sensory loss below the level of the lesion. An MRI is the investigation of choice for SCIWORA.

Assessment. The fully conscious, talking patient can maintain his airway and needs no further airway manipulation. However, the patient's status may deteriorate at any time. The airway, breathing, and circulation (ABC) must constantly be reassessed. The following categories of patients require a definitively secured airway: 1) Apnea, 2) Glasgow coma scale <9 or sustained seizure activity, 3) Unstable midface trauma, 4) Airway injuries, 5) Large frail segment or respiratory failure, 6) High aspiration risk, and 7) Inability to otherwise maintain an airway or oxygenation.

The urgency of airway intubation is the most important factor in planning which technique of securing the airway is the safest and most appropriate. One must evaluate and assess the risk of further cord injury given head and neck movement, the degree of cooperation from the patient, anatomy, and trauma to the airway, and one's own expertise in each technique.

Airway management. The primary objective while managing the patient airway with potential CSI is to

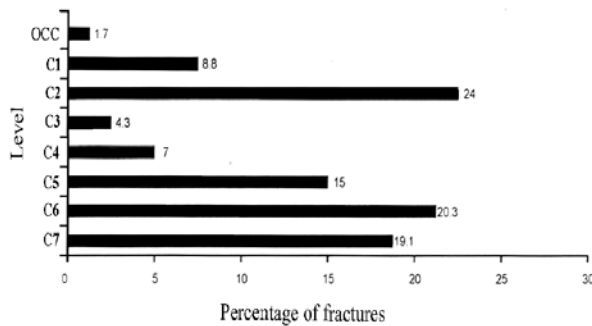


Figure 1 - Distribution of 1195 fractures by cervical spine level.

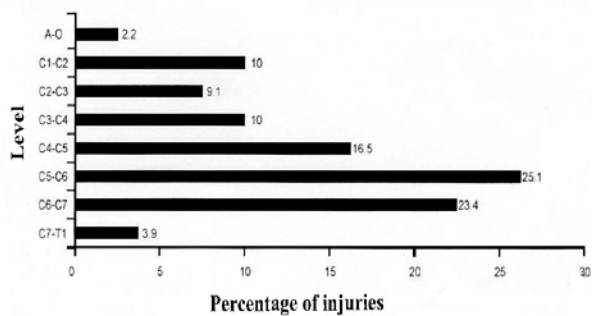


Figure 2 - Distribution of dislocations and subluxations (n=231) by cervical spine level.

minimize the movement of the neck, and secure the airway rapidly and efficiently. The urgency of airway intervention is the most important factor in planning airway management for patients with potential CSI. Initially, the airway should be cleared of debris, blood, and secretions. If necessary, the airway should be opened using the "chin lift" or "jaw thrust" maneuvers. The "sniffing the morning air" position for standard tracheal intubation flexes the lower cervical spine and extends the occiput on the atlas. However, studies have shown that "jaw thrust" and "chin lift" both cause distraction of at least 5 millimeter in a cadaver with C5/6 instability. This movement was unaffected by the use of a rigid collar. Manual stabilization did however reduce movement. An oral (Guedel) or nasopharyngeal airway may be necessary to maintain patency until definitive airway management. Insertion of an airway produces minimal disturbance to the cervical spine. A bag and mask ventilation also produce a significant degree of movement at zones of instability.

Pre-hospital. Adequate oxygenation of a trauma patient is a priority, and is often required before admission to the hospital. Pre-hospital airway interventions provide a high success rate and low complication rate when undertaken by the emergency medical services. However, when emergency physicians were compared with anesthesiologists using a rapid sequence induction in an out-of-hospital environment, the non-anesthesiologists were twice as likely to fail to intubate and to need to undertake a surgical airway.

Direct laryngoscopy and manual in-line neck stabilization. The safest method of securing a tracheal tube remains debatable. Generally, the technique used should be the one the operator is most familiar with. One should know that during normal direct laryngoscopy and oral intubation significant extension occurs between the occiput and C1, and between C1 and C2. The ATLS recommends, a nasotracheal tube in the spontaneously breathing patient and orotracheal intubation in the apneic patient. Manual in line axial stabilization must be maintained throughout the procedure. In the resuscitation room, the most common approach to intubation of the multiply-injured patient with potential CSI is a rapid sequence induction and oral intubation while maintaining the cricoid pressure and manual in line neck stabilization (MILNS). The MILNS is provided by an assistant who holds the patients mastoid process firmly down, opposing the upward forces generated during laryngoscopy. In anesthetized patients, this maneuver reduced head extension by 50% and increases the safety of direct laryngoscopy. However, in a cadaver study of injuries at C4 it did not reduce movement.⁶ At shock trauma center in Baltimore, Maryland, in Baltimore, Maryland,

more than 3000 patients were intubated orally with a method modified rapid sequence induction technique with pre oxygenation and cricoid pressure. Ten percent of these patients were found to have CSI and none deteriorated neurologically following intubation. Atlanto-occipital extension is necessary to bring the vocal cords within the line-of-sight of the mouth. Thus, patients with unstable C1 and C2 injuries might be at more risk from this technique. Axial traction must be avoided as excessive destruction may injure the spinal cord. The view at laryngoscopy is better with MILNS, when we compare it with rigid-collar immobilization. If a cervical collar is left on during laryngoscopy the view obtained will often be grade 3 or 4.⁷ Once MILNS has been applied, the rigid collar should be removed and then reapplied when successful placement of the tracheal tube has been confirmed. The gum elastic bougie is an important adjunct during laryngoscopy in patients with suspected CSI. By accepting a view of only the arytenoids and using a gum elastic bougie for intubation, the laryngoscopist uses less force and minimizes cervical spine movement. Although direct laryngoscopy and oral intubation are the most common method for securing the airway in the trauma patients with a potential CSI, its safety is debated. There are cases reported in the literature of quadriplegia following laryngoscopy without manual stabilization.

Laryngoscopes. Various studies have examined the potential advantages of various laryngoscopes for intubation of the patients with a potential CSI. In a comparison of the Macintosh with the straight bladed Miller laryngoscope,⁸ there was no difference in cervical spine movement and glottic views. Another study showed less axial distraction with the Miller blade compared with the Macintosh and the McCoy laryngoscope.⁹ The views obtained with the McCoy levering laryngoscope have been compared with those achieved with the Macintosh in patients with simulated CSI.¹⁰ The view of vocal cords with the McCoy was improved by at least one grade in 49% of cases, and by 2 grades in 10% of cases. The Bullard laryngoscope is a rigid fiberoptic laryngoscope, which allows visualization of the larynx without having to align the oral, pharyngeal, and tracheal axes. It therefore has a potential role in the management of patients with CSIs. In comparison with the Miller and Macintosh blades, the Bullard laryngoscope produces less head extension and neck movement and produces better glottic views. Problems with the Bullard laryngoscope include prolonged times to intubation, fogging and occasionally, an inability to pass the tracheal tube through the glottis.

Angulated video-intubation laryngoscope. This laryngoscope has a blade with an angulated tip similar to the McCoy laryngoscope but includes a fiberoptic

bundle so that the view from the tip of the blade can be seen on the monitor. By applying this laryngoscope with manual in-line neck immobilization in a group of children, significantly better view was achieved than those achieved with direct laryngoscopy.

Cricoid pressure. Assuming a full stomach in all the trauma patients, application of cricoid pressure is mandatory during rapid sequence induction to reduce the risk of pulmonary aspiration from passive gastric regurgitation. It can be applied by one or 2 hands. The 2 handed technique may produce a better view at laryngoscopy, and may result in less movement at the side of a CSI. When measured with external markers on anesthetized patients, cricoid pressure caused 5 mm of neck movement. However, in a more recent cadaver study using lateral cervical spine x-rays, the application of cricoid pressure causes negligible cervical spine movement. However, incorrectly applied cricoid pressure can make laryngoscopy and mask ventilation more difficult or impossible.¹¹

Awake intubation. Many anesthesiologists advocate awake intubation as the safest method of securing the airway in a patient with CSI. It is thought that preservation of muscle tone provides protection, and spinal integrity can be monitored during airway manipulation. Awake intubation is particularly favored when the need for intubation is not urgent. However, in this technique, intubation is slower than rapid sequence induction, and in acute trauma patients it may increase the risk of aspiration and can increase intracranial pressure. Awake techniques are blind nasal, blind oral, and fiberoptic intubation, requiring considerable training, and a cooperative patient. Blind nasal intubation is complicated by epistaxis in up to 60% of attempts, and by laryngospasm and esophageal intubation. The reported success rates are highly variable, from a 7% success among advanced trauma life support providers in the United Kingdom¹² to 92% in American resident physicians.¹³ Fiberoptic intubation is most valuable in patients with CSI. In cadavers with C3 injury, fiberoptic nasal intubation produced no movement of the unstable segment when assessed by videofluoroscopy.¹⁴ But again, in the acute situation, blood and secretions may make fiberoptic intubation impossible.

Laryngeal mask airway. The laryngeal mask airway (LMA) is now widely accepted as a useful device in case of failed intubation or difficult airways,¹⁵ and has been used when attempts to intubate trauma patients have failed.¹⁶ The LMA can be inserted easily in the neutral position, and has therefore been considered for use in patients with cervical spine instability. Although conventional LMA does not protect the airway against aspiration, the risk of aspiration has been overstated.

The intubating LMA is a modified LMA, we can insert a tracheal tube through it either blindly or using a fiberoptic bronchoscope. Standard insertion requires a neutral position, and no manipulation of the head and neck. The intubating LMA has been used successfully for blind intubation in patients undergoing cervical spine operations.¹⁷ The standard LMA and intubating LMA have been shown to cause a temporary pressure greater than 250 cm of water against the posterior pharyngeal wall during insertion in cadavers. This pressure is enough to cause displacement of C3 up to 2 mm.¹⁸ During insertion and intubation, the intubating LMA causes some movement in the upper cervical spine, but it was less than that produced during direct laryngoscopy. The cricoid pressure makes insertion of an LMA or intubating LMA more difficult because, if properly applied, it inevitably prevents the correct positioning of the device over the larynx. Cricoid pressure applied after the insertion of an intubating LMA makes it difficult to pass a tube into the trachea. The ProSeal LMA incorporates a gastric drainage tube through which a tube can be passed to drain the stomach. The gastric drainage tube will channel any regurgitated fluid away from the respiratory tract. The ProSeal LMA has a deeper bowl for the mask than the standard LMA, with an additional cuff on the dorsal side. As a result of these modifications, the airway-sealing pressure achievable with the ProSeal LMA are at least 10 cm H₂O higher than those with the standard LMA. Like the standard LMA, the ProSeal LMA can be inserted in the neutral position making it an attractive option in the patient with a potential CSI, either as a rescue device when intubation has failed or when personnel are not trained in intubation.

Surgical airway. When oral or nasal tracheal intubation is impossible or contraindicated, cricothyroidotomy will establish a secure airway. However, this procedure is infrequent and in inexperienced, hands the success rate is as poor as 60-70%. In patients with CSI, excessive neck movement should not be allowed. In a cadaver model with a complete C5/6 transaction, cricothyroidotomy resulted in 1-2 mm anteroposterior displacement and one mm axial compression.

In conclusion, there is a consensus on how to clear the cervical spine in patients who are alert, but in patients with altered mental status the choice of strategy for spinal clearance is still controversial. As long as MILNS is applied, rapid sequence induction of anesthesia, followed by direct laryngoscopy, and intubation, appears to be safe in CSI patients. Prolonged hypotension or malpositioning after intubation have as much potential for causing neurological injury as the intubation itself. For patients requiring urgent airway control, we recommend rapid sequence induction

followed by orotracheal intubation with cricoid pressure and manual inline stabilization of head and neck. If intubation is not urgent, an awake fiberoptic technique is a useful option. The LMA, ProSeal LMA, and intubating LMA, are useful alternative airways if tracheal intubation is not possible.

References

- Goldberg W, Mueller C, Panacek E, Tigges S, Hoffman JR, Mower WR, et al. Distribution and patterns of blunt traumatic cervical spine injury. *Ann Emerg Med* 2001; 38: 17-21.
- Marion D, Domeier R, Dunham CM. Determination of cervical spine stability in trauma patients. EAST cervical spine clearance document (update 2000, accessed 2001 November). Available from URL: www.east.org
- Hoffmann JR, Mower WR, Wolfson AB. Validity of a set of clinical criteria to rule out injury to cervical spine in patient to blunt trauma. National emergency x-radiography utilization study group. *N Engl J Med* 2000; 343: 94-99.
- Pasquale M. Practice management guideline for trauma: EAST ad hoc committee on guideline development: identifying cervical instability after trauma: identifying cervical instability after trauma. *J Trauma* 1998; 44: 945-946.
- Marion D, Domeier R, Dunham CM. Determination of cervical spine stability in trauma patients. (updated 2000; accessed 2001 November). Available from URL: www.east.org
- Lennarson PJ, Smith D, Todd MM. Segmental Cervical spine motion during orotracheal intubation of the intact and injured spine with and without external stabilization. *J Neurosurgery* 2000; 92 (2 Suppl): 201-206.
- Mac Quarrie K, Hung OR, Law JA. Tracheal intubation using Bullard laryngoscope for patients with a stimulated difficult airway. *Can J Anesth* 1999; 46: 760-765.
- Hastings RH, Vigil AC, Hanna R. Cervical spine movement during laryngoscopy with the Bullard Macintosh, and Miller laryngoscopies. *Anesthesiology* 1995; 82: 859-869.
- Gerling MC, Davis DP, Hamilton RS. Effect of cervical spine immobilization technique and laryngoscope blade selection on an unstable cervical spine in a cadaver model of intubation. *Ann Emerg Med* 2000; 36: 293-300.
- Laurent SC, de Melo AE, Alexander-Williams JM. The use of the McCoy laryngoscope in patients with simulated cervical spine injuries. *Anaesthesia* 1996; 51: 74-75.
- Ho AM, Wong W, Ling E, Chung DC, Tay BA. Airway difficulties caused by improperly applied cricoid pressure. *J Emerg Med* 2001; 20: 29-31.
- de Courcy JG. A survey of nasotracheal intubating skills among Advanced Trauma Life Support Course graduates. *Br J Anaesth* 1994; 72: 731.
- Iseron KV. Blind nasotracheal intubation. *Ann Emerg Med* 1981; 10: 468-471.
- Brimacombe J, Keller C, Künzel KH, Gaber O, Boehler M, Pühringer F. Cervical spine motion during airway management: a cinefluoroscopic study of the posteriorly destabilized third cervical vertebrae in human cadavers. *Anesth Analg* 2000; 91: 1274-1278.
- Parment JL, Colonna-Romano P, Horrow JC, Miller F, Gonzales J, Rosenberg H. The laryngeal mask airway reliably provides rescue ventilation in cases of unanticipated difficult tracheal intubation along with difficult mask ventilation. *Anesth Analg* 1998; 87: 661-665.
- Martin SE, Ochsner MG, Jarman RH, Agudelo WE, Davis FE. Use of the laryngeal mask airway in air transport when intubation fails. *J Trauma* 1999; 47: 352-3527.
- Nakazawa K, Tanaka N, Ishikawa S, Ohmi S, Ueki M, Saitoh Y. Using the intubating laryngeal mask airway (LMA-Fastrach) for blind endotracheal intubation in patients undergoing cervical spine operation. *Anesth Analg* 1999; 89: 1319-1321.
- Keller C, Brimacombe J, Keller K. Pressure exerted against the cervical vertebrae by the standard and intubating laryngeal mask airways: a randomized, controlled, cross-over study in fresh cadavers. *Anesth Analg* 1999; 89: 1296-1300.

Related topics

Al B, Yildirim C, Zengin S, Cavdar M, Togun I. The effect of chronic carbon-monoxide exposure on the peak expiratory flow values of grill-kebab chefs. *Saudi Med J* 2009; 30: 788-792.

Almogren A. Airway allergy and skin reactivity to aeroallergens in Riyadh. *Saudi Med J* 2009; 30: 392-396.

Sivaci R, Balci C, Maralcan G, Kuru I. Management of difficult airway in a child with arthrogryposis multiplex congenita during general anesthesia. *Saudi Med J* 2005; 26: 1657-1659.