

# Infliximab treatment for resistant Achilles tendonitis

Said M. Al-Asfar, MD, Mohammad Attar, MD, Hasan Shacfeh, MD.

## ABSTRACT

قد لا يستجيب داء الفقار الالتهابي غير المتميز (USPA) احياناً لمضادات الالتهاب الاعتيادية. أظهرت مضادات الالتهاب الروماتيزم البيولوجية فعالية في علاج داء الفقار الالتهابي. وصفت مقالات قليلة فعالية مضادات الالتهاب البيولوجية في علاج داء الفقار الالتهابي غير المتميز USPA. لقد عانا مريضنا من التهاب وتر اشيل غير المستجيب كمظهر أولي لداء الفقار الالتهابي غير المتميز و الذي استجاب بشكل ممتاز لعقار الانفليكسيماب.

Undifferentiated spondyloarthropathies (USPA) can sometimes be refractory to usual disease modifying agents. Anti-tumor necrosis factor (TNF)-alpha agents have been shown to be effective in spondyloarthropathies. Few articles described the efficacy of TNF-alpha antagonists in USPA. Our patient had refractory Achilles tendonitis as an early manifestation of USPA which responded dramatically to infliximab treatment.

*Saudi Med J 2009; Vol. 30 (9): 1228-1230*

*From the Department of Medicine, Division of Rheumatology (Al-Asfar), North West Armed Forces Hospital, Tabuk, and the Department of Internal Medicine (Attar), and the Department of Medicine and Rehabilitation (Shacfeh), Al-Hada Armed Forces Hospital, Taif, Kingdom of Saudi Arabia.*

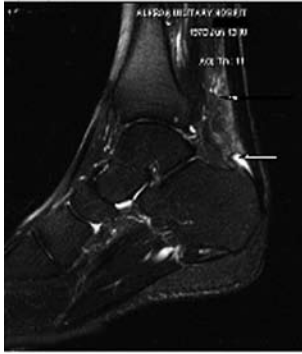
*Received 5th April 2009. Accepted 15th July 2009.*

*Address correspondence and reprint request to: Dr. Said M. Al-Asfar, North West Armed Forces Hospital, Department of Internal Medicine, Division of Rheumatology, PO Box 100, Tabuk, Kingdom of Saudi Arabia. Tel. +966 506721398. Fax. +966 (4) 4411056. E-mail: salasfar@hotmail.com*

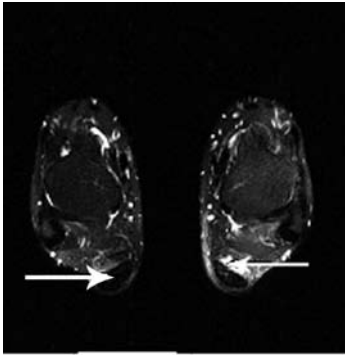
We describe herein a case of a 36-year-old male patient with chronic bilateral Achilles tendonitis, resistant to non-steroidal anti-inflammatory drugs (NSAIDs), sulfasalazine, methotrexate, short courses of steroids, and rehabilitation program. The diagnosis of undifferentiated spondyloarthropathy (USPA) was suggested. Human leukocyte antigen (HLA)-B27 gene was present. The patient was started on infliximab, and he responded to treatment within 48 hours, with resolving tendonitis and normalizing inflammatory markers. We

are presenting this case to support the theory that anti-tumor necrosis factor (TNF)-alpha therapy can be used in cases of refractory Achilles tendonitis when it is part of USPA.

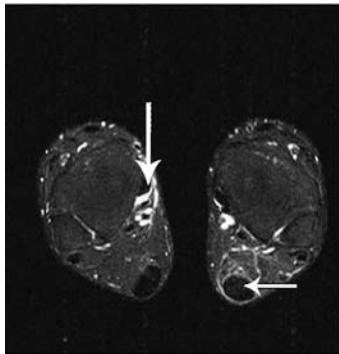
**Case Report.** The patient is a 36-year-old Filipino male who has been working as a housekeeper for the past several years. He presented with pain and swelling of the Achilles tendon, bilaterally for the last year. There was no history of trauma, or signs of systemic disease such as fever, weight loss, rashes, and so forth. There were also no preceding genitourinary manifestations. There was neither a personal history of psoriasis, inflammatory bowel disease, or spondyloarthropathy, nor was there any family history of such diseases. Physical examination revealed normal vital signs, and it was noted that the patient was mildly overweight. Musculoskeletal examination revealed bilateral swelling and severe tenderness of the Achilles tendon, as well as, mild heel tenderness. His initial laboratory results revealed normal blood counts, liver function tests, and chemistry. The results also showed elevated erythrocyte sedimentation rate (ESR) - 65 (normal; 20), and C-reactive protein (CRP) - 25 (normal; 5), negative hepatitis profile B and C, negative human immunodeficiency virus, negative antinuclear antibody and rheumatoid factor, and negative tuberculosis skin test. Testing for chlamydia, mycoplasma, and ureaplasma was not carried out. The x-ray of the chest and sacroiliac joints was normal. The magnetic resonance imaging (MRI) of Achilles tendons is shown in **Figures 1 & 2**. **Figure 1** shows heterogeneous swelling of the Achilles tendon with peritendinitis and retrocalcaneal bursitis. **Figure 2** shows bilateral heterogeneous swelling of the Achilles tendon, peritendinitis, and left side retrocalcaneal bursitis. A working diagnosis of either overuse Achilles tendonitis, or seronegative USPA was made. Initially, his treatment consisted of multiple courses of NSAIDs and local analgesic cream with no clear response. Four months later, sulfasalazine (at a dose of 1 g orally, twice daily), and methotrexate (at a dose of 15 mg per week orally) were added to his treatment regimen for approximately 6 months without much improvement. An extensive rehabilitation program (including air casting and local



**Figure 1** - Heterogeneous swelling of Achilles tendon with peritendinosis (big arrow) and retrocalcaneal bursitis (small arrow).



**Figure 2** - Axial T2, turbo spin echo, fat suppression shows bilateral heterogeneous of Achilles tendon and peritendinosis (big arrow) and left sided retrocalcaneal bursitis (small arrow).



**Figure 3** - Axial T2, turbo spin echo, fat suppression 6 months later shows tenosynovitis of right posterior tibialis (big arrow) persisting of bilateral, currently asymmetric Achilles tendonitis (small arrow).

steroid injection around the Achilles tendon) was administered to the patient with minimal improvement. At times, the patient was limited in his daily activities due to severe pain on weight bearing duties. Six months later, he developed right posterior tibialis tenosynovitis along with his persistent bilateral Achilles tendonitis. The MRI was repeated (**Figure 3**) showing tenosynovitis of right posterior tibialis and persistence

of bilateral, currently asymmetric, Achilles tendonitis. His ESR level rose to 83 mm/hr, his CRP level also rose to 59.4 mg/liter, and he was severely incapacitated by the pain. Testing for HLA-B27 gene was ordered, and it was noted to be present. At this time the patient was admitted to the hospital electively, and colonoscopy was performed due to his past history of one attack of (self-limited) bloody diarrhea, one month prior to admission. Multiple colon biopsies taken to exclude the possibility of inflammatory bowel disease were all normal. The patient was then started on infliximab infusion at a dose of 3 mg/kg of body weight. Within 48 hours, the patient became asymptomatic, performing daily activities without restriction. All his previous symptoms of Achilles tendonitis, and the recent tenosynovitis of the right ankle resolved almost completely. His ESR dropped to 36 mm/hr, and CRP also dropped to 2.6 (normal). Six months after initiating infliximab therapy, the patient is doing very well. There are no signs of disease activity on 7.5 mg oral methotrexate weekly plus infliximab therapy every 2 months.

**Discussion.** Peripheral enthesopathies especially Achilles tendonitis and plantar fasciitis are very frequent in seronegative spondyloarthritides.<sup>1</sup> Achilles tendonitis may, for a long time, be the only clinical feature of the HLA-B27 associated disease process.<sup>1</sup> In USPA, most patients have 2 or more manifestations of spondyloarthropathy, and meet the Amor criteria, or the European Spondyloarthropathy Study Group criteria.<sup>2</sup> The modified Amor criteria can be helpful in suggesting the diagnosis of USPA.<sup>3-5</sup> The therapeutic options in USPA are limited.<sup>6</sup> The NSAIDs and disease-modifying anti-rheumatic drugs are the main therapeutic agents in USPA.<sup>7</sup> In cases where severe symptoms persist despite its treatments, or when there is severe axial involvement, anti-TNF agents represent an effective choice.<sup>7</sup> It was suggested that anti-TNF-alpha short term therapy has significant efficacy in patients with severe USPA.<sup>6</sup> Olivieri et al<sup>8</sup> treated severe refractory heel enthesitis associated with HLA-B27 with adalimumab. We believe that our patient had severe bilateral Achilles tendonitis, which was refractory to the usual treatments. The presence of the HLA-B27 gene, and the later development of tenosynovitis of the right posterior tibialis supported the diagnosis of USPA. This dramatic improvement upon initiating infliximab therapy within 48 hours is adding more evidence for the role of TNF-alpha inhibitors in treating refractory cases of Achilles tendonitis when it is part of USPA.

In conclusion, TNF-alpha inhibitors continue to prove its efficacy in USPA. Long term studies and randomized trials are needed to further clarify the effect of this class of treatment on the natural course of USPA.

**Acknowledgment.** We thank Ms. Blanche Michael and Mrs. Lynnette Canales for their technical and secretarial assistance. We thank Dr. Kamal Ezzeldin, Consultant Radiologist at Al-Hada Armed Forces Hospital, Taif, Kingdom of Saudi Arabia for reading the radiological data. We also thank Dr. Jamal Al-Bishri, Consultant Rheumatologist at Al-Hada Armed Forces Hospital for his scientific advice.

## References

1. Olivieri I, Gemignani G, Gherardi S, Grassi L, Ciompi ML. Isolated HLA-B27 associated Achilles tendinitis. *Ann Rheum Dis* 1987; 46: 626-627.
2. Olivieri I, Salvarani C, Cantini F, Ciancio G, Padula A. Ankylosing spondylitis and undifferentiated spondyloarthropathies: a clinical review and description of a disease subset with older age at onset. *Curr Opin Rheumatol* 2001; 13: 280-284.
3. Amor B, Dougados M, Listrat V, Menkes CJ, Dubost JJ, Roux H, et al. [Evaluation of the Amor criteria for spondylarthropathies and European Spondylarthropathy Study Group (ESSG). A cross-sectional analysis of 2,228 patients]. *Ann Med Interne (Paris)* 1991; 142: 85-89. French.
4. Collantes E, Veroz R, Escudero A, Muñoz E, Muñoz MC, Ciscal A, et al. Can some cases of "possible" spondyloarthropathy be classified as "definite" or "undifferentiated" spondyloarthropathy? Value of criteria for spondyloarthropathies. Spanish Spondyloarthropathy Study Group. *Joint Bone Spine* 2000; 67: 516-520.
5. Gomariz EM, del M, Guijo VP, Contreras AE, Villanueva M, Estévez EC. The potential of ESSG spondyloarthropathy classification criteria as a diagnostic aid in rheumatological practice. *J Rheumatol* 2002; 29: 326-330.
6. Brandt J, Haibel H, Reddig J, Sieper J, Braun J. Successful short term treatment of severe undifferentiated spondyloarthropathy with the anti-tumor necrosis factor-alpha monoclonal antibody infliximab. *J Rheumatol* 2002; 29: 118-122.
7. Palazzi C, Padula A, Montaruli M, Pennese E, Olivieri I. Pharmacological management of undifferentiated spondyloarthropathies. *Expert Opin Investig Drugs* 2006; 15: 39-46.
8. Olivieri I, Scarano E, Gigliotti P, Giasi V, Padula A. Successful treatment of juvenile-onset HLA-B27 associated severe and refractory heel enthesitis with Adalimumab documented by magnetic resonance imaging. *Rheumatology (Oxford)* 2006; 45: 1315-1316.

## Case Reports

Case reports will only be considered for unusual topics that add something new to the literature. All Case Reports should include at least one figure. Written informed consent for publication must accompany any photograph in which the subject can be identified. Figures should be submitted with a 300 dpi resolution when submitting electronically or printed on high-contrast glossy paper when submitting print copies. The abstract should be unstructured, and the introductory section should always include the objective and reason why the author is presenting this particular case. References should be up to date, preferably not exceeding 15.