

Phacoemulsification in high myopia

Serpil Akar, MD, Kemran Gok, MD, Sukru Bayraktar, MD, Vedat Kaya, MD,
Yaşar Kuçuksumer, MD, Cigdem Altan, MD, Omer F. Yilmaz, MD.

ABSTRACT

الأهداف: تحليل التغيرات التي تطرأ على النظر بعد إجراء عملية استحلاب العدسة (phacoemulsification) للأعين التي تعاني من حسر النظر الشديد (high myopia)، بالإضافة إلى تحديد العوامل التي تؤثر سلباً على حدة البصر بعد العملية وتقييم المضاعفات المترتبة على هذه العملية.

الطريقة: أُجريت هذه الدراسة الاسترجاعية في مستشفى بيوغلو للعيون والأبحاث، أسطنبول، تركيا وذلك خلال الفترة من يناير 1998م إلى يوليو 2008م. تم الرجوع إلى سجلات 150 مريضاً (209 عينا)، وقد خضع هؤلاء المرضى لعملية استحلاب العدسة وزرع العدسة داخل المقلة (IOL).

النتائج: لقد وصلت أعلى نتيجة لتصحيح النظر بعد العملية إلى 0.5 أو أعلى من هذه النتيجة وذلك في 63.2% من أعين المرضى، في حين كانت نتيجة الانكسار ± 1.0 ديوبتري في 147 عينا (70.3%). أظهر التحليل الانحداري المتعدد عن وجود علاقة بين وجود التنكس البقعي في المشيمية والشبكية قبل إجراء العملية وتدني حدة البصر بعد العملية ($p=0.000$). ولم يكن هناك علاقة بين عمر المرضى وطول المحور البصري من جهة ونتائج حدة البصر بعد العملية. لقد حدث انفصال للشبكية في عين واحدة (0.5%) وذلك خلال متابعة المريض بعد العملية (18.7 ± 8.9 شهراً).

خاتمة: أظهرت الدراسة بأن أكثر الحالات المصابة بحسر النظر قد حققت نتائج جيدة فيما يخص حدة البصر وقد صاحب ذلك القليل من المضاعفات. وقد أدى تنكس الشبكية إلى ضعف البصر وعدم تحسنه بعد العملية، فيما ساهمت قلة حدوث انفصال الشبكية بعد العملية في تقليل استئصال المحفظة باستخدام Nd:YAG وكذلك تقليل العمليات الجراحية التي تتضمن إجراء خزع للمحفظة الخلفية وذلك في كل المرضى الذين تقل أعمارهم عن 40 عاماً.

Objectives: To analyze the visual results of phacoemulsification in highly myopic eyes, to investigate the risk factors for poor postoperative visual acuity and to assess postoperative complications.

Methods: This retrospective study reviewed the records of 209 eyes of 150 patients with high myopia who

underwent phacoemulsification and foldable intraocular lens (IOL) implantation between January 1998 and July 2008 at Beyoglu Education and Research Eye Hospital, Istanbul, Turkey.

Results: Postoperative best-corrected visual acuity (BCVA) was 0.5 or better in 63.2% of eyes. One hundred forty-seven (70.3%) eyes were within ± 1.0 diopter (D) of the intended target refraction. In multiple regressions, only pre-existing myopic chorioretinal macular degeneration was found to be associated with poor BCVA ($p=0.000$). Nor patient age nor axial length (AL) had any correlation with postoperative BCVA. Retinal detachment (RD) occurred in one eye (0.5%) during mean follow-up (18.7 ± 8.9 months).

Conclusion: Most of the eyes with high myopia achieved satisfactory improvement in BCVA with few complications. Myopic retinal degenerative changes were the single independent factor limiting visual potential. Our lower incidence of postoperative RD could be attributed partially to our lower neodymium:yttrium-aluminum-garnet (Nd:YAG) laser capsulotomy rates and our surgical modification involving the implementation of primary posterior capsulorhexis in all patients younger than 40.

Saudi Med J 2010; Vol. 31 (10): 1141-1145

From the Anterior Segment Department, Beyoglu Education and Research Eye Hospital, Istanbul, Turkey.

Received 30th June 2010. Accepted 23rd August 2010.

Address correspondence and reprint request to: Dr. Serpil Akar, Anterior Segment Department, Beyoglu Education and Research Eye Hospital, Istanbul, Turkey. Tel. +90 (216) 3274787. Fax. +90 (216) 2450947. E-mail: akarserpil@yahoo.com

The term “high myopia” has usually been referred to those eyes whose axial length (AL) are longer than 26 mm.^{1,2} It is also widely accepted to be a degenerative disease occurs as a result of the distension of the globe, mainly at the posterior part.^{3,4} Degenerative myopic chorioretinal changes can be present in the majority of

eyes with high myopia.^{1,4,5} Retinal detachment (RD) and glaucoma are also more frequently encountered in these eyes compared with low myopic and/or emmetropic eyes.^{1,4} Cataract surgery is expected to address both visual and refractive problems in patients with cataract and high myopia.² Extremely high axial myopic eyes were reported to benefit from cataract surgery and implantation of low power, zero power, or minus power posterior chamber intraocular lens (PCIOL).^{6,7} Intraocular lens (IOL) power calculation might be somehow difficult in those elongated eyes as there can be posterior staphylomas.⁸ Preexisting macular chorioretinal degeneration or postoperative RD could have negative influences on best-corrected visual acuity (BCVA) gain after phacoemulsification.² Several studies have assessed the factors, which could influence the outcome of cataract surgery in highly myopic eyes. A significant relationship was found between visual acuity and factors such as chorioretinal degeneration, age, and AL.^{9,10} Preexisting maculopathy was found to be an independent risk factor for failure to achieve good postoperative vision.² Cataract surgery has been shown to increase the risk for RD in highly myopic patients to 1.3-8.0%.^{2,11-16} Possible risk factors for postoperative RD were age, male gender, longer AL, peripheral retinal degeneration with breaks and/or holes, rupture of the posterior capsule and/or vitreous loss during surgery and postoperative neodymium:yttrium-aluminum-garnet (Nd:YAG) laser posterior capsulotomy.^{12,15} The objective of this study were to analyze the refractive and visual results of phacoemulsification in high myopic eyes, investigate the risk factors for poor postoperative visual acuity, and assess our postoperative complications.

Methods. This retrospective study reviewed the records of 209 eyes of 150 patients with high myopia who had cataract extraction by using phacoemulsification between January 1998 and July 2008 at Beyoglu Education and Research Eye Hospital, Istanbul, Turkey. The study and data collection conformed to all local laws and were compliant with the principles of the Declaration of Helsinki. All of the consecutive patients whose AL were ≥ 26 mm measured by ultrason biometry and had a follow-up of at least 12 months were included in the study. No eyes were excluded because of coexisting glaucoma, diabetic retinopathy, age-related macular degeneration, and myopic chorioretinal degeneration. Complete ophthalmologic examinations were performed preoperatively and postoperatively, including a thorough retinal examination. Measurements of uncorrected visual acuity (UCVA) or BCVA were made using a Snellen chart.¹⁷

A-scan ultrasound biometry (contact/applanation method) was used to measure axial length. The IOL

power was determined using the Sanders Retzlaff Krapp (SRK)-T formula. The postoperative refractive target was selected as 0.0-0.50 diopter. The calculated power of the IOL ranged from -8.0 to +16.0 diopter. A 3 piece acrylic IOL was used in 182 (87%) eyes, while a mono block acrylic IOL in 27 (13%) eyes. Different IOL brands were used: optic sizes were between 6.0 and 6.5 mm and the overall length between 12.0 and 12.5 mm.

Cataract extraction was performed using phacoemulsification in all eyes. Subtenon's anesthesia was used for all of the surgeries. Operations were performed using the Legacy (Alcon Fort Worth, TX) or Sovereign (Allergan Irvine, CA) devices. A self-sealing, clear corneal tunnel incision was made with a 2.8-3.0 mm knife. Sodium hyaluronate 1% was used to fill the anterior chamber and protect corneal endothelium. Continuous curvilinear capsulorhexis was made with a forceps and the nucleus was removed by the stop and chop technique.¹⁸ A foldable IOL was implanted in the bag or in the sulcus depending on the capsular integrity after cortex removal. In most cases, no corneal sutures were needed. A capsular tension ring was implanted in 9 eyes (4.3%) due to zonular weakness. Posterior capsular rupture occurred in 11 eyes (5.3%) and anterior vitrectomy was performed; and a foldable IOL was implanted in the sulcus in those eyes. Posterior continuous curvilinear capsulorhexis (PCCC) was performed in 19 eyes (9.1%) during cataract surgery. The decision for PCCC was made according to the age of the patient. If the status of the capsular bag and zonulas were appropriate, we performed this in patients >40 years. Postoperative examinations were conducted at first week, first month, third, sixth, and twelfth months and then annually. Follow-up examinations include manifest refraction, UCVA, and BCVA. Intraocular pressure was measured by applanation tonometry and complications or subjective symptoms were evaluated. Preoperative and the postoperative first and twelfth months data were used for statistically analysis. Snellen acuities were converted to logMAR acuity for statistical analysis and comparisons. Good postoperative visual acuity was defined as "BCVA better than 0.5 Snellen" at the last follow-up visit and poor BCVA as "BCVA worse than 0.1". Postoperative SE of refraction and logMAR visual acuities were compared with preoperative data using "repeated measures of analysis of variance. Multiple regression analysis was performed in order to investigate factors such as age, AL, and preexisting macular chorioretinal degeneration on postoperative BCVA. P values less than 0.05 were accepted as statistically significant. The statistical analysis was performed using SPSS for windows version 15.0 (SPSS Inc., Chicago, IL).

Results. The 150 patients comprised 60 (40%) males and 90 (60%) females. The average age was 61.0 ± 11.2 (range: 35-92) years. Age distribution was as follows: 37 (24.7%) cases <50 years, 44 (29.3%) cases were between 50 and 65 years, and 69 (46%) cases were ≥ 65 years. Average AL, determined by A-scan biometry, was 28.65 ± 2.43 (range: 26.01-37.15) mm (Figure 1). The average follow-up was 18.7 ± 8.9 (between 12-30) months. The mean spherical equivalent (SE) in the postoperative first month was -0.04 ± 1.35 diopter (between -2.25 and +1.75) and was stable during the entire follow-up period ($p=0.216$). One hundred forty-seven (70.3%) eyes were ± 1.0 diopter of the postoperative refractive target. Best corrected visual acuity improved in 173 eyes (83.1%). Preoperative BCVA was ≤ 0.1 in 54.1% of eyes while it was ≥ 0.5 in 132 (63.2%) of eyes postoperatively (Table 1). The average preoperative logMAR BCVA was 1.03 ± 0.57 . It increased to 0.44 ± 0.40 at the first postoperative month and to 0.45 ± 0.39 at postoperative twelfth months. The increase in BCVA was statistically significant and stable during follow-up ($p=0.000$). Uncorrected visual acuity increased in all eyes. Preoperative UCVA was ≤ 0.1 in 96.2% of eyes while postoperative UCVA was ≥ 0.5 in 67 (32%) eyes (Table 1). Postoperative UCVA was < 0.1 in 43 (20.6%) eyes and BCVA was ≤ 0.1 in 27 (13.1%) eyes (Table 1).

There was preexisting myopic chorioretinal degeneration in 29 (13.9%) eyes and was the most important factor associated with poor BCVA postoperatively. Other causes of decreased postoperative visual acuity were shown in Table 2.

In multiple regression analysis, macular chorioretinal degeneration was found to be the single predictor of poor BCVA postoperatively ($p=0.000$). The patient's age and AL did not found to have any statistically

significant impact on BCVA ($p=0.173$ and $p=0.111$, respectively). Retinal detachment occurred in one eye (0.5%). Clinically significant cystoid macular edema was observed in only 2 eyes (0.9%). We performed Nd:YAG laser capsulotomy in 7.7% of eyes. Glaucoma was present in 6 eyes (2.9%) and controlled with medical treatment.

Discussion. Intraocular lens power calculation could be challenging in eyes with extreme myopia due to inaccuracies in AL measurement in the presence of posterior staphyloma and poor fixation from macular disease.¹⁰ Olsen⁸ reported IOL power calculation errors were probably the result of difficulties in measuring the appropriate AL of longer eyes. Biometry formulas also tended to underestimate the power of the required IOL in eyes with an AL greater than 27.0 mm and in eyes receiving a negative power IOL.^{8,19} Intraocular lens Master biometry was found to be more accurate in the measurement of the ocular AL than applanation ultrasonography.²⁰ In our series, IOL power calculations was based on the applanation ultrasound biometry measurements and postoperative SE was within 1.0 diopters of the refractive target in 70% of eyes. Other studies reported that the postoperative SE was within 1.0 diopters of the refractive target in 53.2-69% of highly

Table 1 - Preoperative and postoperative visual acuities.

Visual acuity	Preoperative		Postoperative*	
	UCVA n (%)	BCVA n (%)	UCVA n (%)	BCVA n (%)
≥ 0.5	0	13 (6.2)	67 (32.0)	132 (63.2)
0.2-0.4	8 (3.8)	83 (39.7)	99 (47.4)	50 (23.9)
≤ 0.1	201 (96.2)	113 (54.1)	43 (20.6)	27 (12.9)
Total	209 (100.0)	209 (100.0)	209 (100.0)	209 (100.0)

UCVA - Uncorrected visual acuity, BCVA - Best corrected visual acuity.

*It was used UCVA and BCVA at the postoperative twelfth months.

Table 2 - Causes of decreased postoperative visual acuity

Condition	n (%)
Myopic degeneration	29 (13.9)
Corneal scar/opacity	5 (2.4)
Age related macular degeneration	3 (1.4)
Diabetic retinopathy	2 (1.0)
Glaucoma	6 (2.9)
Optic atrophy	1 (0.5)
Unknown/Possible amblyopia	6 (2.9)
Postoperative complications	
Posterior capsule opacity	16 (7.7)
Cystoid macular oedema	8 (3.8)
Retinal detachment	1 (0.5)

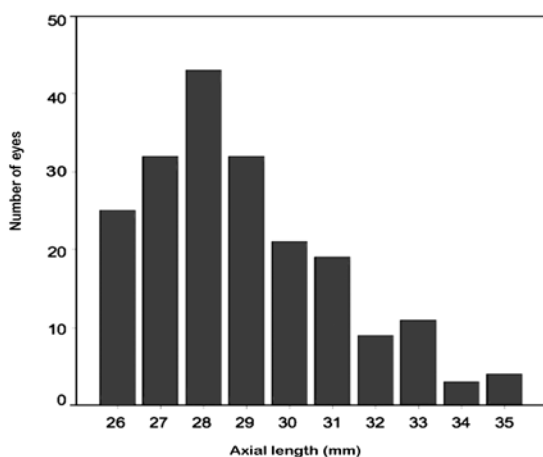


Figure 1 - Axial lengths as recorded with A-scan ultrasound.

myopic eyes undergoing cataract surgery.^{7,10,21} Despite our good refractive results, we believe that IOL Master biometry might further improve the predictability of postoperative refraction. We considered that our visual results were also satisfactory; 63.2% of our eyes achieved postoperative BCVA of 0.5 or better and only 12.9% of eyes had BCVA worse than 0.1. Those results were similar to the studies in the literature, which reported that 52.7-71.2% of eyes with an AL greater than 26 mm could reach BCVA of 0.5 or better after cataract surgery.^{2,6,7,10} However, Ku et al²² determined that patients with high axial myopia might have less favorable visual outcome after cataract surgery.²² Our multiple regression analysis results showed that there was only a single independent risk factor for poor BCVA postoperatively; namely, preexisting myopic degeneration. Patient's age and axial length at first seemed to have a negative impact, but after independent risk analysis they did not have any statistically significant influence on BCVA. We suggested that older age was associated with more severe chorioretinal degeneration and led to poor BCVA postoperatively. Wu et al²³ found an increased incidence of chorioretinal degeneration in pathologic myopia that was separately related to both age and AL. Some authors did not find a significant correlation between poor surgical outcome and an AL greater than 29.0 mm.^{2,6} Tsai et al² recommended to perform preoperative retinal evaluation for prediction of postoperative BCVA. Potential acuity testing may also be beneficial in predicting postoperative visual acuity as it has been shown to be an accurate predictor of postoperative acuity in the presence of macular degeneration.²⁴ In our study, some other ocular problems such as corneal scar or opacity, glaucoma, amblyopia, age related macular degeneration, diabetic retinopathy, optic atrophy, PCO, CMO, and RD also adversely influenced postoperative BCVA. The decision to perform cataract extraction in patients with high myopia should not be straight forward; the risks and benefits of surgery must be thoroughly assessed in each individual patient.^{2,11-15,25} Some intraoperative problems might be more common in those eyes as compared with normal cases. One of them, zonular weakness could be challenging during surgery and worsened by excessive deepening of the anterior chamber.^{26,27} In our series, a capsular tension ring was implanted due to zonular weakness in 4.3% of cases. Posterior capsular rupture occurred in 5.3% of our cases and an anterior vitrectomy was performed and IOL was implanted in the sulcus in these eyes. In other studies, posterior capsule perforation has been reported between 2.8-5.5% of eyes with an AL greater than 26.0 mm.^{6,10} Cataract surgery has been

definitely increased the risk for RD in highly myopic patients.²⁸ The incidence of pseudophakic RD within 3 years of phacoemulsification has been shown to be 0.4-1.2% in the general population^{10,29} compared with 5.2% in patients younger than 50 years³⁰ and 8% in eyes with high myopia (≥ 15.0 diopter).¹⁶ The incidence of RD in the present study was relatively lower (0.5%) as compared with other studies, which report pseudophakic RD rates between 0.26-3.8% in eyes with AL >26.0 mm,^{2,6,10-15,22,31} 1.3-8.0% in eyes with an AL >29.0 mm,^{15,16} and 11% in eyes with an AL between 33.6 mm and 33.5 mm.¹⁶ Factors known to increase the risk for pseudophakic RD included posterior capsule rupture during surgery, zonular dehiscence, RD in the fellow eye, retinal lattice degeneration and postoperative Nd:YAG laser capsulotomy. The incidence of RD was reported to be lower in cases with an intact posterior capsule.³² We believed that a through anterior vitrectomy was essential and might be protective against RD if posterior capsule ruptured intraoperatively. Alio et al¹⁴ found a trend toward an increased incidence and risk of RD in patients younger than 50 years. In our series, only 24.7% of cases were >50 years and none of the patients had RD in fellow eyes. Several authors demonstrate an association between after Nd:YAG laser capsulotomy and an increased risk for RD after cataract surgery, particularly in high myopic eyes,³³ while other studies failed to confirm it.¹⁰ Our 7.7% incidence of Nd:YAG laser capsulotomy is lower than that of Tsai et al² (11.5%), Tosi et al¹⁵ (16.4%), and Guell and Rodriguez-Arenas³⁴ (56.8%). There was a major difference in our surgical protocol; we attempted to perform primary posterior capsulorhexis during surgery in all patients younger than 40 years. Despite of the lack of any solid evidence showing its beneficial influence on RD, we believe that our lower RD incidence might be at least partially explained with this surgical modification. We also thought that the relatively shorter follow-up could be also associated with the lower RD incidence.

In conclusion, we found that high myopic eyes do benefit from cataract surgery using phacoemulsification and foldable IOL implantation in general. Our refractive and visual results were satisfactory in the majority of them. Pre-existing myopic chorioretinal degeneration at the macula was found to be the single factor limiting the visual acuity postoperatively. It should be sought in every high myopic eye prior to cataract surgery and appropriate counseling should be given to the patient. We recommended that the possible beneficial role of primary posterior capsulorhexis on RD prophylaxis should be investigated in a prospective randomized study.

References

1. Zejmo M, Formińska-Kapuścik M, Pieczara E, Filipek E, Mrukwa-Kominek E, Samochowiec-Donocik E, et al. Etiopathogenesis and management of high-degree myopia. Part I. *Med Sci Monit* 2009; 15: RA199-RA202.
2. Tsai CY, Chang TJ, Kuo LL, Chou P, Woung LC. Visual outcomes and associated risk factors of cataract surgeries in highly myopic Taiwanese. *Ophthalmologica* 2008; 222: 130-135.
3. Vongphanit J, Mitchell P, Wang JJ. Prevalence and progression of myopic retinopathy in an older population. *Ophthalmology* 2002; 109: 704-711.
4. Saw SM, Gazzard G, Shih-Yen EC, Chua WH. Myopia and associated pathological complications. *Ophthalmic Physiol Opt* 2005; 25: 381-391.
5. Shih YF, Ho TC, Hsiao CK, Lin L L-K. Visual outcomes for high myopic patients with or without myopic maculopathy: a 10 year follow up study. *Br J Ophthalmol* 2006; 90: 546-550.
6. Li CY, Chen YC, See LC, Lin KK. Visual outcome after cataract surgery in extremely high axial myopia. *Ann Ophthalmol* 2007; 39: 27-35.
7. Ji YH, Lu Y, Lu GS, Luo Y, Wang M. [Phacoemulsification and the negative power of intraocular lenses in extremely myopic eyes] *Zhonghua Yan Ke Za Zhi* 2005; 41: 196-199.
8. Olsen T. Calculation of intraocular lens power: a review. *Acta Ophthalmol Scand* 2007; 85: 472-485.
9. Xu L, Li Y, Wang S, Wang Y, Wang Y, Jonas JB. Characteristics of highly myopic eyes; the Beijing Eye Study. *Ophthalmology* 2007; 114: 121-126.
10. Zuberbuhler B, Seyedian M, Tuft S. Phacoemulsification in eyes with extreme axial myopia. *J Cataract Refract Surg* 2009; 35: 335-340.
11. Williams MA, McGimpsey S, Abugreen S, Chan W, Sharkey JA, Best RM, et al. The incidence and rate of rhegmatogenous retinal detachment seven years after cataract surgery in patients with high myopia. *Ulster Med J* 2009; 78: 99-104.
12. Coppe AM, Lapucci G. Posterior vitreous detachment and retinal detachment following cataract extraction. *Curr Opin Ophthalmol* 2008; 19: 239-242.
13. Neuhann IM, Neuhann TF, Heimann H, Schmickler S, Gerl RH, Foerster MH. Retinal detachment after phacoemulsification in high myopia: analysis of 2356 cases. *J Cataract Refract Surg* 2008; 34: 1644-1657.
14. Alio JL, Ruiz-Moreno JM, Shabayek MH, Lugo FL, Abd El Rahman AM. The risk of retinal detachment in high myopia after small incision coaxial phacoemulsification. *Am J Ophthalmol* 2007; 144: 93-98.
15. Tosi GM, Casprini F, Malandrini A, Balestrazzi A, Quercioli PP, Caporossi A. Phacoemulsification without intraocular lens implantation in patients with high myopia: long term results. *J Cataract Refract Surg* 2003; 29: 1127-1131.
16. Ripandelli G, Scassa C, Parisi V, Gazzaniga D, D'Amico DJ, Stirpe M. Cataract surgery as a risk factor for retinal detachment in very highly myopic eyes. *Ophthalmology* 2003; 110: 2355-2361.
17. Sue S. Test distance vision using a Snellen card. *Community Eye Health* 2007; 20: 52.
18. Alio JL, Mulet ME, Shalaby AM, Attia WH. Phacoemulsification in the anterior chamber. *J Cataract Refract Surg* 2002; 28: 67-75.
19. Seward H, Packard R, Allen D. Management of cataract surgery in a high myope. *Br J Ophthalmol* 2001; 85: 1372-1378.
20. Landers J, Goggin M. Comparison of refractive outcomes using immersion ultrasound biometry and IOLMaster biometry. *Clin Experiment Ophthalmol* 2009; 37: 566-569.
21. Pomberg ML, Miller KM. Preliminary efficacy and safety of zero diopter lens implantation in highly myopic eyes. *Am J Ophthalmol* 2005; 139: 914-915.
22. Ku WC, Chuang LH, Lai CC. Cataract extraction in high myopic eyes. *Chang Gung Med J* 2002; 25: 315-320.
23. Wu PC, Chen YJ, Chen YH, Chen CH, Shin SJ, Tsai CL, et al. Factors associated with foveoschisis and foveal detachment without macular hole in high myopia. *Eye (Lond)* 2009; 23: 356-361.
24. Uy HS, Munoz VM. Comparison of the potential acuity meter and pinhole tests in predicting postoperative visual acuity after cataract surgery. *J Cataract Refract Surg* 2005; 31: 548-552.
25. Gavras MC, Caraus C, Popa D, Caciula D, Gushe E, Clocotan D, et al. [Phacoemulsification and intraocular lens implantation in myopic eye]. *Oftalmologia* 2004; 48: 77-81.
26. Nahra Saad D, Castilla Cespedes M, Martinez Palmer A, Pazos Lopez M. Phacoemulsification and lens-iris diaphragm retropulsion syndrome. *Ophthalmic Surg Lasers Imaging* 2005; 36: 512-513.
27. Cionni RJ, Barros MG, Osher RH. Management of lens-iris diaphragm retropulsion syndrome during phacoemulsification. *J Cataract Refract Surg* 2004; 30: 953-956.
28. Martínez-Castillo V, Boixadera A, Verdugo A, Elíes D, Coret A, García-Arumí J. Rhegmatogenous retinal detachment in phakic eyes after posterior chamber phakic intraocular lens implantation for severe myopia. *Ophthalmology* 2005; 112: 580-585.
29. Boberg Ans G, Villumsen J, Henning V. Retinal detachment after phacoemulsification cataract extraction. *J Cataract Refract Surg* 2003; 29: 1333-1338.
30. Russell M, Gaskin B, Russell D, Polkinghome PJ. Pseudophakic retinal detachment after phacoemulsification cataract surgery; ten-year retrospective review. *J Cataract Refract Surg* 2006; 32: 442-445.
31. Ravalico G, Michieli C, Vattovani O, Tognetto D. Retinal detachment after cataract extraction and refractive lens exchange in highly myopic patients. *J Cataract Refract Surg* 2003; 29: 39-44.
32. Banker AS, Freeman WR. Retinal detachment. *Ophthalmol Clin North Am* 2001; 14: 695-704.
33. Ranta P, Tommila P, Kivela T. Retinal breaks and detachment after neodymium:YAG laser posterior capsulotomy: five-year incidence in a prospective cohort. *J Cataract Refract Surg* 2004; 30: 58-66.
34. Guell JL, Rodriguez-Arenas AF, Gris O, Maleceze F, Velasco F. Phacoemulsification of the crystalline lens and implantation of an intraocular lens for the correction of moderate and high myopia: four year follow up. *J Cataract Refract Surg* 2003; 29: 34-38.