

Unusual association between adrenal leiomyoma and autoimmune disease

Anwar A. Al-Masri, MD, MIAC, Tariq N. Aladily, MD, Nidal A. Younes, MD, MSc.

ABSTRACT

يعد ورم الغدة الكظرية العضلي الأملس ورم صلب نادر غير معروف السبب. في هذه المقالة نقوم بوصف حالة مريضة تبلغ من العمر 38 عام مصابة بالتهاب الغدة الدرقية هاشيموتو. تبين وجود ورم في الغدة الكظرية اليمنى أثناء إجراء التصوير الطبقي. بينت الفحوصات المخبرية أن الكتلة غير مفرزة، لكن نظراً لنمو حجمها مع الزمن تمت إزالتها جراحياً. أثبت الفحص النسيجي و الصبغات المناعية الكيميائية أن الورم هو عضلي أملس. المثير في الأمر أن الورم كان يحتوي على تخرل كثيف من الخلايا اللمفاوية لدرجة تكون مراكز منتجة. على الرغم من أن معظم الحالات المسجلة لورم الكظرية العضلي الأملس لها علاقة بنقص المناعة، بينما لم تسجل أي منها علاقة مع أمراض المناعة الذاتية. يعد هذا المقال تقرير حالة ورم الكظرية العضلي الأملس مع تخرل لمفاوي كثيف.

Adrenal leiomyoma is a rare solid tumor of unknown etiology. Here, we present a case of a 38-year-old woman, a known case of Hashimoto's thyroiditis, presented with right adrenal mass incidentally discovered by computed tomography imaging. The mass was non-functioning according to laboratory results, but because the mass increased in size in a follow up visit, she underwent right adrenalectomy. The histological findings confirmed the diagnosis of adrenal leiomyoma, which was supported by a panel of immunohistochemical stains. Surprisingly, there was a dense lymphocytic infiltrate in the background of the tumor, forming germinal centers. Although most of the reported adrenal leiomyoma cases are associated with immune deficiency, none of the previous cases was associated with an autoimmune disease.¹ We report a case of an unusual adrenal leiomyoma with a dense lymphocytic infiltrate.

Saudi Med J 2010; Vol. 31 (2): 199-201

From the Departments of Pathology (Al-Masri, Aladily), and General Surgery (Younes), Jordan University Hospital, Amman, Jordan.

Received 21st November 2009. Accepted 1st January 2010.

Address correspondence and reprint request to: Dr. Tariq Aladily, Department of Pathology, Faculty of Medicine, PO Box 142725, University of Jordan, Amman, Jordan 11814. Tel. +962 (788) 636337. E-mail: Tariq_nb@yahoo.com

Adrenal leiomyoma is a rare benign deep soft tissue tumor, which arises from the residual embryonal blood vessel tissue, and smooth muscle fibers. Few cases were reported in the literature, most of which were non-functioning, incidentally discovered, and associated with immune deficiency.¹ On literature review, none of the reported cases were associated with a concurrent autoimmune disease. Herein, we report a rare case of adrenal leiomyoma in association with Hashimoto's thyroiditis and review the literature.

Case Report. A 38-year-old Mediterranean woman, a known case of Hashimoto's thyroiditis, presented to Jordan University Hospital, Amman, Jordan, with signs of complicated acute appendicitis. A CT-scan was performed and showed an incidental right adrenal mass measuring 3 x 2 x 2 cm. The adrenal mass was investigated after appendectomy and proved to be non-functioning. The other adrenal gland was normal. She had normal blood pressure. Urine 3-methoxy-4-hydroxymandelic acid (VMA) and metanephrine levels were within normal limits. Serum electrolytes and cortisol levels (dexamethasone suppression test) were within normal limits. Human immunodeficiency virus immunoglobulin-G (HIV IgG) titer was negative.

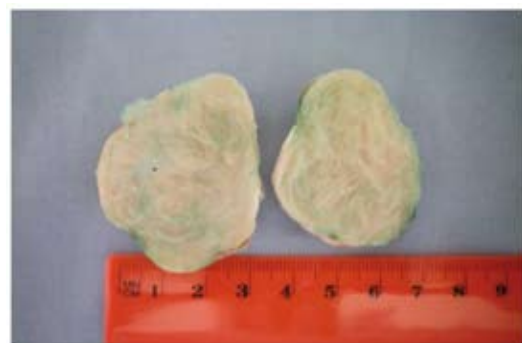

Figure 1 - Grossly, the right adrenal gland measured 4.5 x 4 x 3.5 cm. The external surface was irregular. Step sectioning revealed a firm, white cut surface with a whorly pattern, occupying the whole gland. No suspicious areas are seen.

Thyroid function tests were normal with L-thyroxin treatment. Anti-thyroid peroxidase antibodies (TPO) were elevated (239 IU; <150IU/ml[normal range]), anti-thyroglobulin titer was negative (less than 85 IU, <85 IU [normal range]). The initial diagnosis of Hashimoto's thyroiditis was based on clinical and serologic tests. A repeat CT scan 6 months later showed enlargement of the mass, with a new measurement of 4 x 4 x 3 cm. She underwent successful right adrenalectomy (Figure 1). Histologically, the adrenal gland was totally occupied by a tumor, composed of uniform spindle cells arranged in interlacing fascicles. No nuclear pleomorphism, coagulative necrosis, or increased mitotic activity was seen (Figure 2). Dense lymphocytic infiltrate was noted in the background of the tumor in all levels, both intratumoral and peritumoral (Figure 3). Immunohistochemical studies confirmed the diagnosis of adrenal leiomyoma (Figures 4 & 5). There were no post-operative complications, and the patient was discharged home 4 days after surgery.

Discussion. Leiomyomas are benign tumors consisting of smooth muscle cells. They occur most frequently in the uterus and gastrointestinal tract, but have been found in a wide range of sites including the adrenal glands.¹ A malignant counterpart is seen in the adrenal gland, but is exceedingly rare.² Adrenal leiomyomas are usually small tumors that are not highly worrisome for adrenocortical carcinoma. While the National Institutes of Health (NIH) recommends surgical resection of incidental adrenal tumors larger than 6 cm in greatest dimension,³ most of the reported cases of adrenal leiomyomas were smaller than that size. Fluorodeoxyglucose-positron emission tomography (FDG-PET) scan revealed that the tumor was non-functioning in most reported cases, with unequivocal results in the remaining ones.¹

Interestingly, patients with acquired immunodeficiency syndrome (AIDS) especially children, are at an increased risk for the development of smooth muscle neoplasms, such as leiomyoma and leiomyosarcoma.⁴ There is an association between

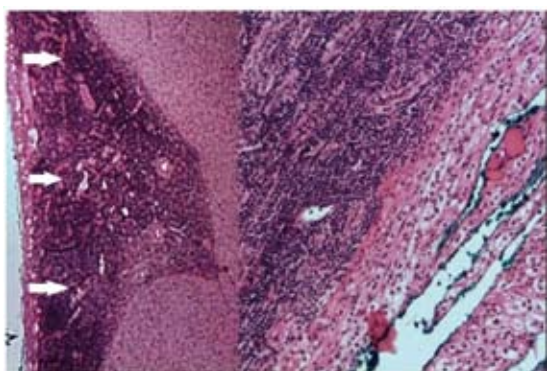


Figure 2 - The leiomyoma is sharply bordered by dense lymphocytic infiltrates (arrows). A thin strip of adrenocortical tissue is still present (Hematoxylin & Eosin stain x100).

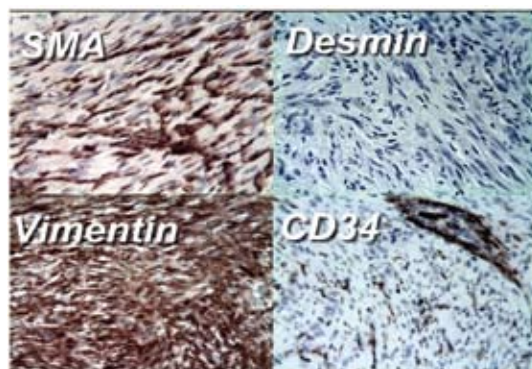


Figure 4 - The tumor is positive for smooth muscle actin (SMA) and vimentin, but negative for desmin and CD34.

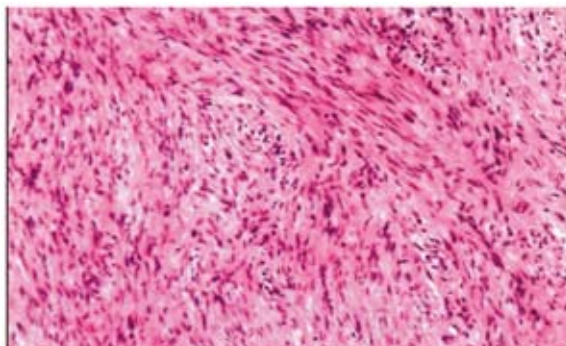


Figure 3 - The tumor is composed of monomorphic spindle cells arranged in fascicles. The main differential diagnosis was leiomyoma, schwannoma, solitary fibrous tumor, and extraintestinal gastrointestinal stromal tumor (GIST) (Hematoxylin & Eosin stain x200).-

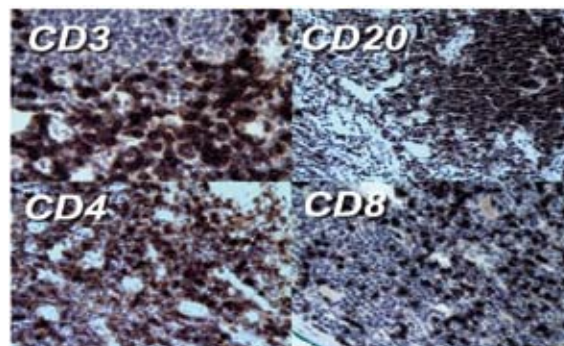


Figure 5 - The lymphocytic aggregates are mixed of B and T cells, highlighted by CD3 and CD20 positivity. The T-cells are mainly CD4 helper lymphocytes, with few CD8 cytotoxic lymphocytes.

adrenal leiomyoma and latent Epstein Barr virus infection (EBV), and/or HIV/AIDS.¹ Five among the reported cases were associated with HIV/AIDS, and one with ataxia-telangiectasia.¹ An EBV infection is associated with smooth muscle tumors in immunocompromised, but not in immunocompetent patients.¹ The patient in this paper was seronegative for HIV. The EBV IgG antibody was positive, but IgM was negative. Immunohistochemical stain for EBV in the histological specimen was negative. On literature review, none of the reported cases showed an association with an autoimmune process, or an additional peculiar histopathological feature, as in our case. Based on the histopathological finding in our case, concurrent Hashimoto's thyroiditis, and being a middle aged female patient, we suppose an association between the adrenal leiomyoma and an autoimmune process. This observation can be noteworthy, especially if it is reported again in the future.

We conclude that adrenal leiomyoma is rare and is associated with good prognosis. The local recurrence

and transformation into sarcoma is rare. Surgeons, pathologists, and endocrinologists should be aware of the possibility of an adrenal leiomyoma as a cause of adrenal incidentalomas, and complete excision is recommended in these cases.

References

1. Lin J, Wasco MJ, Korobkin M, Doherty G, Giordano TJ. Leiomyoma of the adrenal gland presenting as a non-functioning adrenal incidentaloma: case report and review of the literature. *Endocr Pathol* 2007; 18: 239-243.
2. Candanedo-González FA, Vela Chávez T, Cérbulo-Vázquez A. Pleomorphic leiomyosarcoma of the adrenal gland with osteoclast-like giant cells. *Endocr Pathol* 2005; 16: 75-81.
3. NIH state-of-the-science statement on management of the clinically inapparent adrenal mass ("incidentaloma"). *NIH Consens State Sci Statements* 2002; 19: 1-25.
4. Metta H, Corti M, Redini L, Dure R, Campitelli AM, Narbaitz M. Endobronchial leiomyoma: an unusual non-defining neoplasm in a patient with AIDS. *Rev Inst Med Trop Sao Paulo* 2009; 51: 53-55.

Related topics

Sayyah-Melli M, Tehrani-Gadim S, Dastranj-Tabrizi A, Gatrehsamani F, Morteza G, Ouladesahebmadarek E, et al. Comparison of the effect of gonadotropin-releasing hormone agonist and dopamine receptor agonist on uterine myoma growth. Histologic, sonographic, and intra-operative changes. *Saudi Med J* 2009; 30: 1024-1033.

Saquib S, Mathew M, Jain R. Torsion of a non-gravid uterus with leiomyoma mimicking broad ligament leiomyoma. *Saudi Med J* 2009; 30: 851-852.

Baban RS, Al-Zuheiri ST, Farid YY. Prolactin receptors in uterine leiomyomas. *Saudi Med J* 2008; 29: 1593-1596.