

Labial adhesion in a reproductive aged girl

Omer Kutlu, MD, Ismail T. Koksall, MD.

ABSTRACT

يصف هذا التقرير حالة التصاق شفوي لفتاة تبلغ من العمر 22 عام. كما أن الشكاوي الرئيسية للمريضة التي كانت تعاني منها هي الصعوبة في البول منذ 10 عام و احتباس البول المؤقت في فترة الطمث. قمنا بتقييم حالة المريضة وتأمين تحرير العضو من الالتصاق المهبل بالطرق الجراحية تحت التخدير الموضعي.

This report describes a case of a 22-year-old girl who had labial adhesion. Her primary complaints were difficulty voiding and temporary urinary retention during menstruation for 10 years. The patient was evaluated and underwent surgical lysis of labial adhesion under regional anesthesia.

Saudi Med J 2010; Vol. 31 (2): 202-203

From the Department of Urology (Kutlu), Faculty of Medicine, Karadeniz Technical University, Trabzon, and the Department of Urology (Koksall), Faculty of Medicine, Akdeniz University, Antalya, Turkey.

Received 1st December 2009. Accepted 5th January 2010.

Address correspondence and reprint request to: Dr. Omer Kutlu, Department of Urology, Faculty of Medicine, Karadeniz Technical University, PO Box 61070, Trabzon, Turkey. Tel. +90 (462) 3775892 Fax. +90 (462) 3250518. E-mail: omerkutlu@ktu.edu.tr

Labial adhesion is a rare condition that is defined as complete or partial fusion of labia minora in the midline.¹ Labial adhesions commonly occur in pre-pubertal girls with an incidence of 1.4%.² There are a few reports in reproductive women. An extensive search of the literature revealed only 8 cases in the reproductive age. Although, its etiology is associated with hypooestrogenism, it may occur in the environment of normal estrogen levels.³⁻⁵ Such adhesions could also result following dermatitis, vaginitis, lichen sclerosis and trauma related to sexual abuse or fall.^{1,6,7} In this report, we had discussed the etiology and management of labial adhesion with current literature review.

Case Report. A 22-year-old girl was referred to our hospital for nearly complete labial adhesion in February 2008. She was evaluated with a thorough history, physical examination, urine analysis, renal function tests, and genitourinary ultrasonography. She attained menarche at the age of 12 years, and her primary complaints were difficulty voiding and lower abdominal pain due to temporary urinary retention during menstruation for 10 years. She did not declare any history of trauma, vulvar inflammation, sexual intercourse, or abuse. The physical examination was performed under the lithotomic position and detected no phallus or ambiguous genitalia. The labia major, perineum, and anus were identified as normal, but the labia minora, urethral meatus, and hymen were not visualized. A meatus was detected at the lower part of the vulva allowing passing of 8 Fr feeding tube (**Figure 1a**). There was no sign indicating hormonal deficiency; for example, hirsutism and her secondary sexual characteristics were well developed. For this reason, hormonal measurements were not performed. No pathologic finding was detected on urine analysis and for the renal functions. Uterus, cervix, and ovaries were detected as normal by ultrasonography and there was no urinary anomaly detected, for example, renal agenesis, hypoplasia, or ectopy. She was referred for cystoscopy and surgery under regional anesthesia. Firstly, cystoscopy was performed using a pediatric cystoscope. The hymen was identified as an annular ring and the urethral meatus was determined. Afterwards, the bladder was evaluated and no anomaly was detected. The labia minora were observed as conjoined with thick fibrous tissue in the midline. The labial adhesion was separated by sharp dissection and then the separated edges of the labia minora were sutured with absorbable suture material (**Figure 1b**). A Foley catheter was inserted into the bladder to prevent the contact of urine with the wound. The catheter was removed on the third postoperative day, and then she was discharged from hospital without any problems. No medication (for example, topical estrogen) was given additionally. At the sixth postoperative month, she was very satisfied

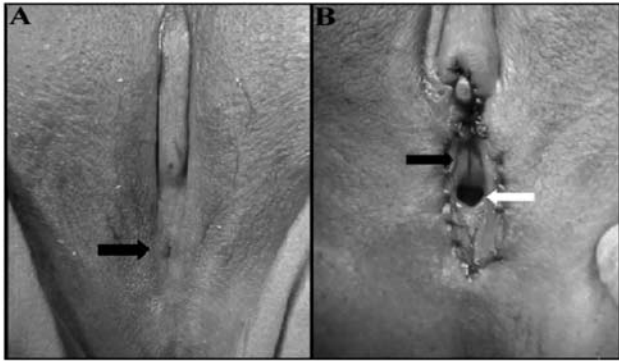


Figure 1 - Patient photographs showing a) Labia minora fused in the midline and black arrow shows a small orifice for menstruation and urination. b) Urethral meatus (black arrow) and hymen (white arrow) are visualized after lysis of labial adhesion.

with the result, and had no voiding difficulty. We had the opportunity to perform imaging of the patient's recent condition.

Discussion. Labial adhesion is defined as the partial or complete fusion of the labia minora. Labial adhesion is also called labial fusion, vulvar fusion, occlusion of the vestibule, and agglutination of the labia minora.⁵ It may be congenital or acquired. In patients with a congenital condition, this may be associated with ambiguous genitalia, hypoplastic kidney and microperforate hymen. Its occurrence is typically limited to pre-pubertal girls, usually below 6 years of age. Labial adhesion also occurs in postmenopausal women, and very rarely, during the reproductive years.⁸ There are a few reports about reproductive women, and the reported causes were associated with poor hygiene, dermatitis, nonspecific or candidal vaginitis, herpes simplex, trauma due to fall, female circumcision and lichen sclerosis.^{6,7} Patients with labial adhesion may be asymptomatic or have urinary symptoms such as urinary retention, urinary tract infection, pain, or altered urinary stream. The diagnosis is established upon visual inspection of the vulva. Initial treatment of pre-pubertal patients with labial adhesions traditionally consists of estrogen creams with gentle traction.^{4,5,7} Additionally, it was recently reported that betamethasone cream appears to be a safe and effective treatment of prepubertal labial adhesions.⁴ Initial comparison of topical estrogen and betamethasone treatment of labial fusion suggests that betamethasone may separate fusion quicker with less recurrence and fewer side effects than topical estrogen therapy.⁹

Surgical lysis of labial adhesions is usually reserved for refractory cases unresponsive to conservative therapy.⁸ In this case, the cause of labial adhesion was likely associated with hypoestrogenism in the intrauterine and neonatal period, because her labial adhesion was nearly complete. Despite her complaints and many visits to the physicians for many years, she was never examined gynecologically. This may have caused the delayed diagnosis. Our treatment choice for this patient was surgical, because her labial adhesion comprised thick fibrous tissue. We did not need to give local estrogen treatment because she was a post-pubertal girl and her secondary sexual characters were well developed.

In conclusion, gynecological examination is necessary for evaluation of voiding symptoms. Otherwise, some disorders (for example, labial adhesion, meatal stenosis) may not be recognized and carry forward to the reproductive age. Also, physical examination, genitourinary ultrasonography, and cystoscopy are sufficient for evaluation if secondary sexual characters are normal. Cystoscopy must be performed under regional or general anesthesia, thus labial adhesion can be separated simultaneously if cystoscopy is normal.

References

1. Kumar RK, Sonika A, Charu C, Sunesh K, Neena M. Labial adhesions in pubertal girls. *Arch Gynecol Obstet* 2006; 273: 243-245.
2. Norbeck JC, Ritchey MR, Bloom DA. Labial fusion causing upper urinary tract obstruction. *Urology* 1993; 42: 209-211.
3. Caglar MK. Serum estradiol levels in infants with and without labial adhesions: the role of estrogen in the etiology and treatment. *Pediatr Dermatol* 2007; 24: 373-375.
4. Myers JB, Sorensen CM, Wisner BP, Furness PD 3rd, Passamaneck M, Koyle MA. Betamethasone cream for the treatment of pre-pubertal labial adhesions. *J Pediatr Adolesc Gynecol* 2006; 19: 407-411.
5. Leung AK, Robson WL, Kao CP, Liu EK, Fong JH. Treatment of labial fusion with topical estrogen therapy. *Clin Pediatr (Phila)* 2005; 44: 245-247.
6. Awang NA, Viegas C, Viegas OA. Incomplete bladder emptying due to labial fusion in a pubertal girl: a delayed consequence of female circumcision. *Aust N Z J Obstet Gynaecol* 2004; 44: 372-373.
7. Seehusen DA, Earwood JS. Postpartum labial adhesions. *J Am Board Fam Med* 2007; 20: 408-410.
8. Acharya N, Mandal AK, Ranjan P, Kamat R, Kumar S, Singh SK. Labial fusion causing pseudo-incontinence in an elderly woman. *Int J Gynaecol Obstet* 2007; 99: 246-247.
9. Mayoglou L, Dulabon L, Martin-Alguacil N, Pfaff D, Schober J. Success of treatment modalities for labial fusion: a retrospective evaluation of topical and surgical treatments. *J Pediatr Adolesc Gynecol* 2009; 22: 247-250.