

# Magnetic toy ingestion leading to jejunocecal fistula in a child

Ali M. Ahmed, MD, MRCS (Ed), Mohamed H. Hassab, MS, FRCS (Ed), Abdulrahman A. Al-Hussaini, MD, Tariq I. Al-Tokhais, SBGS, ABGS.

### ABSTRACT

يعد ابتلاع الأجسام الغريبة مشكلة منتشرة جداً بين الأطفال ولكن بلع الأجسام المغناطيسية نادر الحدوث. إذا بلع الشخص أكثر من مغناطيس فقد يتسبب الالتصاق بينهم إلى حبس أجزاء من جدران الأمعاء مما يؤدي إلى نواسير بين الأمعاء وأحياناً انثقاب وانسداد الأمعاء. نحن هنا بصدد نشر حالة طفلة تبلغ من العمر 5 عام و تعاني من ناسور بين الأمعاء والقولون نتيجة بلع لعبتين مغناطيسيتين، و تسليط الضوء على أهمية التشخيص الدقيق لهذه الحالات و التدخل الجراحي المبكر للأطفال لتفادي المشاكل والمضاعفات خصوصاً عند بلع الأجزاء المغناطيسية.

The accidental ingestion of a foreign body is a common problem in children, but ingestion of magnets is rare. When multiple magnets are ingested, they may attract each other and cause pressure necrosis through the bowel walls and eventually lead to serious complications like obstruction, perforation, and fistula formation. We report a case of a 5-year-old girl with jejunocecal fistula following ingestion of 2 magnet toys; it highlights the diagnostic challenge and the need for early surgical intervention in children especially when multiple magnets are ingested.

*Saudi Med J 2010; Vol. 31 (4): 442-444*

*From the Departments of Pediatric Surgery (Ahmed, Hassab), and Pediatric Gastroenterology (Al-Hussaini), King Fahd Medical City, and the Department of Surgery (Al-Tokhais), King Khalid University, Riyadh, Kingdom of Saudi Arabia.*

*Received 16th December 2009. Accepted 24th February 2010.*

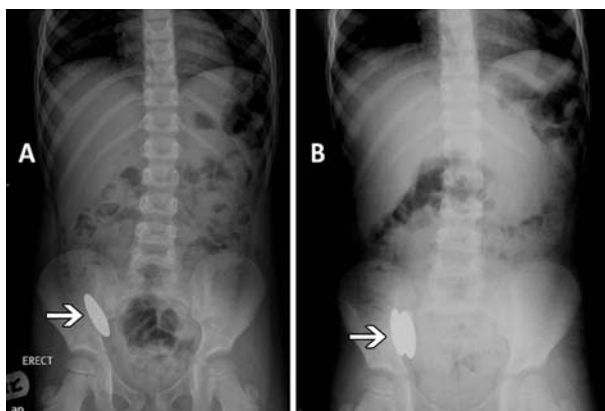
*Address correspondence and reprint request to: Dr. Mohamed H. Hassab, Consultant Pediatric Surgery, Department of Pediatric Surgery, King Fahd Medical City, Riyadh, Kingdom of Saudi Arabia. Tel. +966 506452341. Fax. +966 (1) 2889999 Ext. 2463. E-mail: bhassab@kfmc.med.sa*

Foreign object ingestion is a common clinical problem in young children. Fortunately, most foreign bodies (FBs) usually cause no harm and spontaneously come out of the rectum without treatment. Although specific

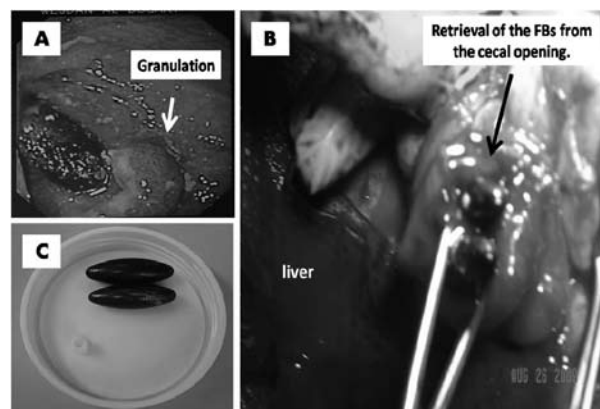
FBs such as sharp objects or batteries are well known to cause certain complications, the complications associated with magnetic FB ingestion are still underestimated. We report a case of jejunocecal fistula by ingested magnet toys to highlight the diagnostic challenges and the need for early surgical intervention in children.

**Case Report.** A 5-year-old, otherwise, healthy girl presented with a history of ingestion of a piece of a magnetic toy. She visited the emergency room and was admitted to the hospital several times, and based on the x-ray findings suggesting the presence of only one piece (Figure 1a), she was discharged home with reassurance that the object would pass spontaneously. Two months later, she presented with abdominal pain and decreased appetite. A repeat x-ray confirmed the presence of 2 FBs (Figure 1b). Colonoscopy showed severe inflammation (Figure 2a), trials of extraction failed and laparotomy was performed. There was a jejunocecal fistula 40 cm from the duodenojejunal junction (Figure 2b). The FBs (Figure 2c), 2 oval, smooth, powerful, magnetic toys, each one measuring 3.8 x 1.3 cm were removed and repair of the bowel wall was carried out. Her postoperative course was uneventful, and she was discharged home on the sixth day postoperatively, and she had no complaints 4 month after the procedure.

**Discussion.** The incidence of FB ingestion is more than 100,000 patients annually in the United States alone. More than 80% of these occur in the pediatric population with 98% of these being accidental. Endoscopic retrieval is required in 10-20%. Most objects that reach the stomach will pass through the gastrointestinal tract spontaneously with no consequence. Less than 1% of objects ingested will require surgical intervention.<sup>1,2</sup> Objects that require endoscopic or surgical removal are those that are large enough to cause obstruction, those that may cause trauma because of sharp edges, and those that may cause mucosal or transmural injury by caustic or mechanical forces.<sup>3</sup> Ingestion of magnets



**Figure 1** - Abdominal x-ray frontal view showing a) the findings suggesting the presence of only one foreign body in the region of the ileocecal valve, and b) 2 foreign bodies attached to each other at the same site.



**Figure 2** - Colonoscopy shows a) severe inflammation and granulation around the foreign body on the colonic side. b) Intra-operative photograph demonstrates a jejunocecal fistula and retrieval of the foreign bodies (FBs) from the cecal opening. c) Shows strong attraction between 2 smooth oval shaped magnetic toys, each piece measures 3.8 x 1.3 cm.

by children has recently come under greater attention due to the death of a 2-year-old boy in Washington State, after swallowing pieces of the magnetized play set Magnetix (Rose Art Industries Inc., Livingston, NJ, USA) and recall of this play set by the US Consumer Product Safety Commission.<sup>4</sup> Recent improvements in manufacturing processes have made small, powerful magnets inexpensive and readily available, increasing the potential for exposure of children to magnets in toys and other products. Ingestion of multiple magnets, or ingestion of one magnet and a metal component attracted to magnets, poses a unique health hazard.<sup>5</sup> The pathogenesis of the complications is the attraction of 2 or more magnets across the walls of multiple loops of bowel. This causes ischemia and necrosis of the pinched bowel wall leading to ulceration and eventually perforation or fistulation. Magnet ingestion has resulted in obstruction, fistula formation, ulceration, perforation, volvulus of the small and large intestine and strangulation of adjacent loops of small bowel between the attracted segments.<sup>6</sup> Liu et al<sup>7</sup> enumerates in his report many cases of gastrointestinal fistulas reported recently in the literature. Both plain radiography and CT lack the sensitivity to determine the multiplicity of magnetic objects. A misdiagnosis can result from the false assumption that a solitary magnet is present.<sup>8</sup> Therefore, at least 2 x-ray views should be performed, unlike in our case, where only one frontal view was carried out, which lead to misleading the diagnosis and delay in proper management. However, if the ingested FB is revealed on a plane radiograph and the position becomes fixed on serial radiographs, there should be suspicion of ingestion of multiple magnets.<sup>9</sup> In multiple magnet ingestion, once symptoms of increasing abdominal pain or signs

of intestinal obstruction or perforation develop then prompt exploratory laparotomy should be performed.<sup>6</sup> In our case, colonoscopy carried out prior to laparotomy revealed the attracting magnets associated with severe inflammation and granulation, which made the surgical option safer than a colonoscopy retrieval. Kim<sup>10</sup> concluded in his report that, if the ingested multiple magnets are found to pass the pylorus on the abdominal radiographs, they should be removed immediately by laparotomy before any symptoms or complications occur to prevent severe complications.<sup>10</sup>

In conclusion, multiple magnet ingestion, compared to a single magnet, is a distinct clinical situation that needs to be managed differently. Two x-ray views should be considered. Multiple magnet ingestion can lead to serious gastrointestinal complications, and awareness among clinicians and the public of the health hazards may improve the outcome.

**Acknowledgments.** We extend our thanks to Dr. Amany R. Abozeid, Assistant Consultant Radiologist, Department of Radiology, King Fahd Medical City, Riyadh, Saudi Arabia, for reviewing the figures.

## References

1. Butterworth J, Feltis B. Toy magnet ingestion in children: revising the algorithm. *J Pediatr Surg* 2007; 42: E3-E5.
2. Alzahem AM, Soundappan SS, Jefferies H, Cass DT. Ingested magnets and gastrointestinal complications. *J Paediatr Child Health* 2007; 43: 497-498.
3. Pryor HI 2nd, Lange PA, Bader A, Gilbert J, Newman K. Multiple magnetic foreign body ingestion: a surgical problem. *J Am Coll Surg* 2007; 205: 182-186.
4. Fenton SJ, Torgenson M, Holsti M, Black RE. Magnetic attraction leading to a small bowel obstruction in a child. *Pediatr Surg Int* 2007; 23: 1245-1247.

5. McCormick S, Brennan P, Yassa J, Shawis R. Children and mini-magnets: an almost fatal attraction. *Emerg Med J* 2002; 19: 71-73.
6. Robinson AJ, Bingham J, Thompson RL. Magnet induced perforated appendicitis and ileo-caecal fistula formation. *Ulster Med J* 2009; 78: 4-6.
7. Liu S, de Blacam C, Lim FY, Mattei P, Mamula P. Magnetic foreign body ingestions leading to duodenocolonic fistula. *J Pediatr Gastroenterol Nutr* 2005; 41: 670-672.
8. Hernández Anselmi E, Gutiérrez San Román C, Barrios Fontoba JE, Ayuso González L, Valdés Dieguez E, Lluna González J, et al. Intestinal perforation caused by magnetic toys. *J Pediatr Surg* 2007; 42: E13-E16. Review.
9. Nui A, Hiramata T, Katsuramaki T, Maeda T, Meguro M, Nagayama M, et al. An intestinal volvulus caused by multiple magnet ingestion: an unexpected risk in children. *J Pediatr Surg* 2005; 40: E9-E11.
10. Kim J. Gastrojejunal Fistula with Jejunal Rotation Caused by Two Ingested Magnets in a Child: A Case Report. *J Korean Radiol Soc* 2006; 55: 153-156.

#### Related topics

Abu-Daff NS, Abu-Daff SN, Rubayaan A, Abu-Shaabani A. Laparoscopy in the treatment of a giant true epiphrenic diverticulum with migration of the gastrointestinal anastomosis staples. *Saudi Med J* 2009; 30: 295-298.

Bhat VS, Al-Saadi KA, Bessiouni IE, Tuffaha AS. Embedded esophageal foreign body. *A diagnostic challenge. Saudi Med J* 2009; 30: 433-435.

Al-Mazrou KA, Makki FM, Allam OS, Al-Fayez AI. Surgical emergencies in pediatric otolaryngology. *Saudi Med J* 2009; 30: 932-936.

El-Khushman HM, Sharara AM, Sa'ada MA, Hijazi MA. Tracheobronchial straight metallic pin aspiration in young Jordanian females. *Saudi Med J* 2007; 28: 913-916.