

The effect of leptin on the osteoinductive activity of recombinant human bone morphogenetic protein-2 in nude mice

Jun-Chang Xu, MD, PHD, Gui-Hua Wu, BSc, MSc, Han-Lin Liu, BSc, MSc, Jiang-Tao Liu, MD, PHD, Xue-Jun Yan, BSc, MSc, Jian-Ting Chen, MD, PHD.

ABSTRACT

الأهداف: التحقق من أثر اللبتين في تكون نموذج العظم المنتبذ الذي يستخدم في زرع بروتين التخليق العظمي البشري المنشوب المعامل جينياً (rhBMP-2) تحت الجلد والذي يحتوي على قرص الكولاجين من النوع الأول.

الطريقة: أجريت الدراسة في جامعة ساوثرن الطبية - قوانغتشو - الصين خلال الفترة من نوفمبر 2008م إلى يونيو 2009م. تم مزج جرعة واحدة 20 وحدة ليتر من المحلول الملحي (المجموعة الأولى A)، ومقدار جرعة 20 وحدة جرام من اللبتين (المجموعة الثانية B)، ومقدار 2 وحدة جرام من بروتين التخليق العظمي البشري المنشوب المعامل جينياً (rhBMP-2) (المجموعة الثالثة C)، واحتوت (المجموعة الرابعة D) على جرعة مقدارها 2 وحدة جرام من بروتين التخليق العظمي البشري المنشوب المعامل جينياً (rhBMP-2) و 20 وحدة جرام من اللبتين، وخلطت أقراص الكولاجين من النوع الأول كحامل وزرعت تحت جلد ظهر الفئران العدد=12 فأر. تم تقييم أثر تكون العظم المنتبذ بالتصوير الإشعاعي، ومقياس امتصاص الطاقة المزدوج، والفحص الكيميائي لنشاط أنزيم الفوسفات (ALP)، وتقييم الأنسجة، والتقييم الكمي المائل في الأسبوع الثامن، والرابع بعد الجراحة.

النتائج: في الأسبوع الثامن والرابع بعد العملية، أظهرت قيم الأنسجة، ونشاط أنزيم الفوسفات، و(BMD)، والتصوير الإشعاعي اختلافات مهمة إحصائية بين المجموعات وداخل المجموعات، كانت تلك القيم في الفئران في الأسبوع الثامن أعلى من الأسبوع الرابع.

خاتمة: أظهرت نتائجنا أن المادة الناقلة المتحررة مع عقار الكولاجين كحامل، تتكون من العلاج باللبتين، وبروتين التخليق العظمي البشري المنشوب المعامل جينياً لديهم نشاط عظمي مستقل، ويساعد اللبتين في تقوية نشاط البروتين المنشوب الذي يحتوي على أقراص الكولاجين بشكل واضح في إنتاج تشكل العظم. كما أن آليته تساعد في تكون الأوعية الجديدة، واختلاف التكاثر للخلايا المختلفة الأنواع.

Objectives: To investigate the effect of leptin in the model of ectopic bone formation that utilizes subcutaneously implanted recombinant human bone morphogenetic protein-2 (rhBMP-2)-containing type I collagen discs.

Methods: This study was performed in the Clinical Research Center, Southern Medical University, Guangzhou, China from November 2008 to June 2009. A single dose of 20 ul saline (group A), 20 ug leptin (group B), 2 ug rhBMP-2 (group C), 2 ug rhBMP-2 + 20 ug leptin (group D), and type I collagen disks as a carrier were mixed, and subcutaneously implanted into the back of nude mice (n=12). The effect of ectopic bone formation was evaluated by radiography, dual-energy X absorptiometry, biochemical examination of alkaline phosphatase (ALP) activity, histological observation, and semi-quantitative evaluation 4 and 8 weeks after surgery.

Results: At 4 and 8 weeks after operation the radiographs, bone mass density, ALP, and histology values showed significant intragroup and intergroup differences, with those at 8 weeks being higher than those at 4 weeks.

Conclusion: Our results indicated that the sustainedly released material with collagen as a carrier combined treatment with leptin and rhBMP-2 has a very good osteoinductive activity. Leptin is a positive modulator for the osteoinductive efficacy of BMPs, they have synergistic effect. Its mechanisms are probably related to promote the formation of new-vessels and proliferation/differentiation of many kinds of cells.

Saudi Med J 2010; Vol. 31 (6): 615-621

From the Department of Orthopedics (Xu, Liu H, Liu J, Yan), Xiangfan No.1 People's Hospital, the Department of General Surgery (Wu), Affiliated Hospital of Xiangfan Vocational and Technical College, Hubei Province, and the Department of Spine and Orthopedics (Xu, Chen), Nanfang Hospital of Southern Medical University, Guangdong Province, China.

Received 18th January 2010. Accepted 3rd May 2010.

Address correspondence and reprint request to: Dr. Jian-Ting Chen, Department of Spine and Orthopedics, Nanfang Hospital of Southern Medical University, Guangzhou 510515, Guangdong Province, China. Tel. +86 (20) 87640940. Fax. +86 (20) 87640940. E-mail: doctorchenjt@163.com

Recombinant human bone morphogenetic protein (rhBMP) 2, 4 and 7, which form a subgroup of the transforming growth factor (TGF)- β superfamily were first isolated as factors that induce ectopic bone formation in vivo. Bone morphogenetic proteins (BMPs) have been showed strong osteoinductive.¹⁻⁴ However, there are 2 major challenges that need to be overcome before successful clinical application, one is that bone formation by BMPs needs a carrier as a delivery system and a calcifying framework. Type I collagen, which is immuno-eliminated and biodegradable, is currently the most suitable carrier for osteoinduction by BMPs.^{5,6} Another problem is that because the osteoinductive activity of BMPs in primates is unstable or negative, a large quantity of BMPs must be used in humans for bone formation.^{5,7} Therefore, it might be preferable to combine anabolic agents that have synergistic effects as an attractive solution to solve this problem.⁸ Numerous previous experimental studies concerning the co-active effect between BMPs and other inductive factors have been performed to induce ectopic bone formation, which focused on TGF- β , basic fibroblast growth factor (bFGF), insulin-like growth factor (IGF), vascular endothelial growth factor (VEGF), and so forth.^{9,10} There are still some potential signaling factors that may be involved, but it is yet to be confirmed. One candidate is leptin, and it has been shown to promote bone formation in previous experimental systems both in vivo and in vitro.¹¹⁻¹⁴ It is known that leptin alone has various effects on cellular proliferation in various conditions, and that the effects might influence other cytokines. Therefore, the aim of the present study was to investigate the effect of leptin on osteoinductive activity in the model of ectopic bone formation that utilizes subcutaneously implanted rhBMP-2 containing collagen discs.

Methods. *Preparation of rhBMP-2 and leptin retaining collagen discs.* Leptin and rhBMP-2 were purchased from Santa Cruz Biotechnology, Santa Cruz, CA, USA. The rhBMP-2 was provided in a buffer solution (5 mmol/l glutamic acid, 2.5% glycine, 0.5% sucrose, and 0.01% Tween-80) at a concentration of one μ g/ μ l after filter sterilization. Different samples were added into sterile water, and all 20 μ l were blotted into a porous collagen disk (5 mm diameter, 1 mm thickness), fabricated from commercially available bovine collagen sheets (Helistat [Integra Life Sciences Co, Plainsboro, NJ, USA]). The discs were then freeze-dried, and kept at -20°C until implantation into the mice. These procedures were carried out under sterile conditions.

Animal experimental protocols. This study was performed in the Clinical Research Center, Southern Medical University, Guangzhou, China from November

2008 to June 2009. All animal experimental protocols were approved by the Animal Care and Use Committee of Southern Medical University and conformed to the National Institutes of Health Guidelines. Twelve male 4-week-old, specific-pathogen-free-standard (SPF) BALB/c nude mice weighing 25-28 g were used. They were purchased from the Department of Laboratory Animal Center of Southern Medical University, Guangzhou, China, and housed in cages with free access to food and water for 7 days before the operation. All surgical procedures were performed under general anesthesia induced by an intraperitoneal injection of sodium pentobarbital (30 mg/kg), and with aseptic techniques. Once anesthetized, a 0.5 cm-length incision were performed at bilateral armpits and fold inguens on the back of the nude mice, and the porous collagen disks with differing agents were subfascially implanted. Incision was routinely sutured with an interrupted 4-0 silk suture. Eight mice were used for each experimental time point (such as, 4 and 8 weeks following implantation).

Sample preparation. Four and 8 weeks later, specimens were harvested together with the surrounding muscle by cutting a slightly larger diameter circle than the disc from the mice following sacrifice with diethyl ether, by gently incising the skin, and gently pulling out the disc using forceps. The average amount of specimens removed from each mouse was 150 ± 5.0 mg. Subsequently, the discs were removed, and analyzed for the radiopaque area and bone mineral density (BMD) evaluation, then the samples were cut into 2 parts, half was for biochemistry and the other was for histology.

Radiographic and BMD evaluation. High-resolution radiographs (projective conditions: 42 kilovolts, 100 milliamperes, exposure time 0.12 seconds) of the whole mice, and gross specimens were taken at 4 and 8 weeks after surgery. The radiopaque area in the radiograph of each sample was detected using a computer system with a scanner (Porascan 35 Ultra [Polaroid Co. Ltd., Cambridge, MA, USA] and Photoshop software version 4.0 J [Adobe Systems Inc., San Francisco, CA, USA] and NIH-image version 1.61 [National Institutes of Health, Bethesda, MD, USA]).⁸ The BMD of each freshly recovered ossified disc was measured by dual-energy X-ray absorptiometry using a bone mineral analyzer (Model DCS-600R [Aloka Co, Mitaka-shi, Tokyo, Japan]).

Disclosure. This study was supported by the Natural Science Foundation of Guangdong Province, China (Grant No. 08024394).

Biochemical evaluation and histomorphometric analysis. The disks were inspected and dissected, half of the sample was examined biochemically. First, they were homogenized in 2.5 ml of 0.25 M sucrose in a Polytron homogenizer, and centrifuged at 1750 reverse/minute with a force of 1250 g for 10 min at -10°C , then centrifuged at 15000 reverse/min with a force of 12000 g for 15 minutes at -4°C . The alkaline phosphatase (ALP) activity of the resultant supernatant was determined by an ALP kit (Biosino Biotechnology Company Ltd, Beijing, China) in accordance with the manufacturer's specification. Subsequently, the remaining half of the samples were immediately fixed in 10% formalin, and decalcified in 10% ethylenediamine tetraacetic acid for one week. They were then dehydrated through graded ethanol, and embedded in paraffin. Four μm thick cross-sections through the middle of each disc were processed for Hematoxylin and Eosin (H&E) staining. Histological examination and semi-quantitative evaluation of each cross-section was obtained under a light microscope.

Data were expressed as mean \pm standard deviation (SD) for each group. Data processing were performed using the Statistical Package for Social Sciences version

13.0 (SPSS Inc, Chicago, IL, USA). A comparative study of means was performed using the analysis of variance (one-way [ANOVA]). A $p < 0.05$ were considered to be significant.

Results. Surgical survival and health of the mice following disc implantation. No fatality or adverse complications (for example, traumatic infection) was generated in all mice. The health of all operated mice appeared unaffected by the disc implant as routinely estimated by weight gain and activity level.

Radiographic evaluation. At 4-8 weeks after operation, there are semicircular masses in the operative areas only in groups B, C, and D. The masses are tenacious, increasing, and stiffening gradually, the masses in group D are the biggest by macroscopical observation and radiographs. The radiographs show that the size of the radiopacities gradually increased in groups B-D, and those at 8 weeks were significantly higher than those at 4 weeks as shown in Table 1.

BMD analysis. The values of BMD gradually increased in groups A-D. At 4, and 8 weeks after operation, the BMD values showed significant intragroup and intergroup differences as shown in Table 2.

Table 1 - The radiopaque areas in all groups at 4 and 8 weeks after operation in mm^2 (n=6).

Groups	Mean \pm standard deviation			F-value	P-value
	4 weeks	8 weeks	Total		
Group A	1057.500 \pm 98.401	1045.500 \pm 82.694	1051.500 \pm 86.884	0.052	0.824
Group B	1239.833 \pm 166.247	1644.333 \pm 150.367	1442.083 \pm 259.738	19.537	0.001
Group C	1509.000 \pm 190.431	2025.167 \pm 204.001	1767.083 \pm 328.729	20.526	0.001
Group D	1853.167 \pm 197.873	2303.333 \pm 243.303	2078.250 \pm 316.185	12.363	0.006
Total	1414.875 \pm 343.865	1754.583 \pm 510.203	1584.729 \pm 463.371	76.576*	0.000*
F	25.497	54.616	45.591*	5.637 [†]	0.003 [†]
P-value	0.000	0.000	0.000*		

There were 2 main effect (45.591* and 0.000*) [F=76.576* and $p=0.000^*$] and a crossover effect (F=5.637, $p=0.003$) in One-way Analysis of Variance. [F=45.591*, $p=0.000^*$] this main effect was the comparison between 4 groups at different timepoint (4 and 8 weeks). (F5.637, $p=0.003$) This was the crossover effect.

Table 2 - The bone mass density in all groups at 4 and 8 weeks after operation in g/cm^2 (n=6).

Groups	Mean \pm standard deviation			F-value	P-value
	4 weeks	8 weeks	Total		
Group A	0.022 \pm 0.002	0.024 \pm 0.003	0.023 \pm 0.003	1.208	0.297
Group B	0.032 \pm 0.008	0.049 \pm 0.011	0.041 \pm 0.012	9.722	0.011
Group C	0.049 \pm 0.010	0.070 \pm 0.014	0.059 \pm 0.016	8.995	0.013
Group D	0.071 \pm 0.014	0.088 \pm 0.012	0.080 \pm 0.015	5.013	0.049
Total	0.044 \pm 0.021	0.058 \pm 0.026	0.051 \pm 0.025	68.395*	0.000*
F	32.157	34.488	19.475*	1.835 [†]	0.156 [†]
P-value	0.000	0.000	0.000*		

There were 2 main effect (45.591* and 0.000*) [F=76.576* and $p=0.000^*$] and a crossover effect (F=5.637, $p=0.003$) in One-way Analysis of Variance. [F=45.591*, $p=0.000^*$] this main effect was the comparison between 4 groups at different timepoint (4 and 8 weeks). (F5.637, $p=0.003$) This was the crossover effect.

Table 3 - The alkaline phosphatase activity in all groups at 4 and 8 weeks after operation in U/mg (n=6).

Groups	Mean \pm standard deviation			F-value	P-value
	4 weeks	8 weeks	Total		
Group A	0.042 \pm 0.008	0.051 \pm 0.012	0.047 \pm 0.011	2.248	0.165
Group B	0.277 \pm 0.059	0.480 \pm 0.088	0.379 \pm 0.128	22.246	0.001
Group C	0.418 \pm 0.094	0.634 \pm 0.082	0.526 \pm 0.140	17.888	0.002
Group D	0.599 \pm 0.105	0.771 \pm 0.107	0.685 \pm 0.135	7.863	0.019
Total	0.334 \pm 0.220	0.484 \pm 0.286	0.409 \pm 0.263	144.015*	0.000*
F-value	101.384	196.692	43.621*	4.447 [†]	0.009 [†]
P-value	0.000	0.000	0.000*		

There were 2 main effect (45.591* and 0.000*) [F=76.576* and p=0.000*] and a crossover effect (F=5.637, p=0.003) in One-way Analysis of Variance. [F=45.591*, p=0.000*] this main effect was the comparison between 4 groups at different timepoint (4 and 8 weeks). (F5.637, p=0.003) This was the crossover effect.

Biochemical examination of ALP. Similar to BMD we observed that the activity of ALP gradually increased in groups A-D, and there were significant intragroup and intergroup differences as shown in Table 3.

Histological findings and semi-quantitative evaluation. Results of histological findings of each group are presented in Figure 1. Collagen was partly absorbed, and no bone and cartilage formation was observed at 4 and 8 weeks postoperatively in group A. However, collagen was mostly absorbed, and a large quantity of cartilages and bone was formed in groups B, C, and D, and the new bony tissue in group D were the most mature. The semi-quantitative evaluation gradually increased in groups B-D. At 4 and 8 weeks after operation, the semi-quantitative evaluation indicated significant intragroup and intergroup differences as shown in Table 4.

Discussion. Our macroscopical observation and radiographs studies found that there were semi-circular masses in the operated areas in groups B, C, and D, and masses in group D were the biggest and hardest. In contrast, no callus-shadows were detected in group A. The results revealed differences in radiopaque areas, BMD, the activity of ALP, histological evaluation in groups B, C, D animals when compared with their controls. All evidence indicates that the sustainably released material with collagen as a carrier compounded with rhBMP-2 and leptin has very good osteoinductive activity, and leptin can enhance the activity of rhBMP-2 in inducing bone formation. Leptin is a positive modulator for the osteoinductive efficacy of BMPs, they have synergistic effect.

The BMPs were originally isolated as factors based on their ability to induce ectopic cartilage and bone formation. Agents to promote local bone formation with BMPs would be beneficial to promote bone

repair, and to shorten the treatment period.¹⁰ Leptin is a polypeptide hormone comprising 167 amino acids, and secreted primarily by the white adipose tissue. The widespread expression of leptin and its receptor within various cells and tissues,¹⁵⁻¹⁸ suggests that leptin may be involved in a variety of metabolic regulations.¹⁹ It is known that leptin acts not only as a major regulator of appetite and energy expenditure,²⁰ but also as an endocrine hormone regulating bone metabolism.¹¹⁻¹³ Leptin is an osteoinductive factor, which is a positive modulator for the osteoinductive efficacy of BMPs. During the course of bone formation, osteoinductive factors stimulate primordial mesenchymal cells in soft tissue to differentiate into osseous progenitor cells. Subsequent differentiation into osteoblasts occurs. With further stimulation, these osteoblasts produce considerable ALP and collagen. This osteoid matrix subsequently calcifies, forming mature appearing bone. In addition, during the endochondral ossification process, vascular invasion is an essential step, and vascular-like growth factors (such as, VEGF, bFGF) had been considered to be key players.^{8,9} The BMPs were the initiators of bone formation, inducing undifferentiated mesenchymal into chondroblasts and osteoblasts, but it has no further influence on the proliferation of differentiated chondrocytes and osteoblasts, and even has a depressant effect. In previous studies, leptin as a caryocinesis-accelerator has been shown to induce bone formation and maturation through a series of cellular events, including mesenchymal cell proliferation and differentiation,²¹ osteoblast proliferation,²² fibroblast proliferation and collagen synthesis,²³ increased mineralization of the extracellular matrix,^{23,24} cartilage formations and vascularization.^{25,26} Furthermore, it might influence other cytokines, such as BMPs and VEGF. Synergistic osteoinduction is probably related to promoting the formation of new vessels, and

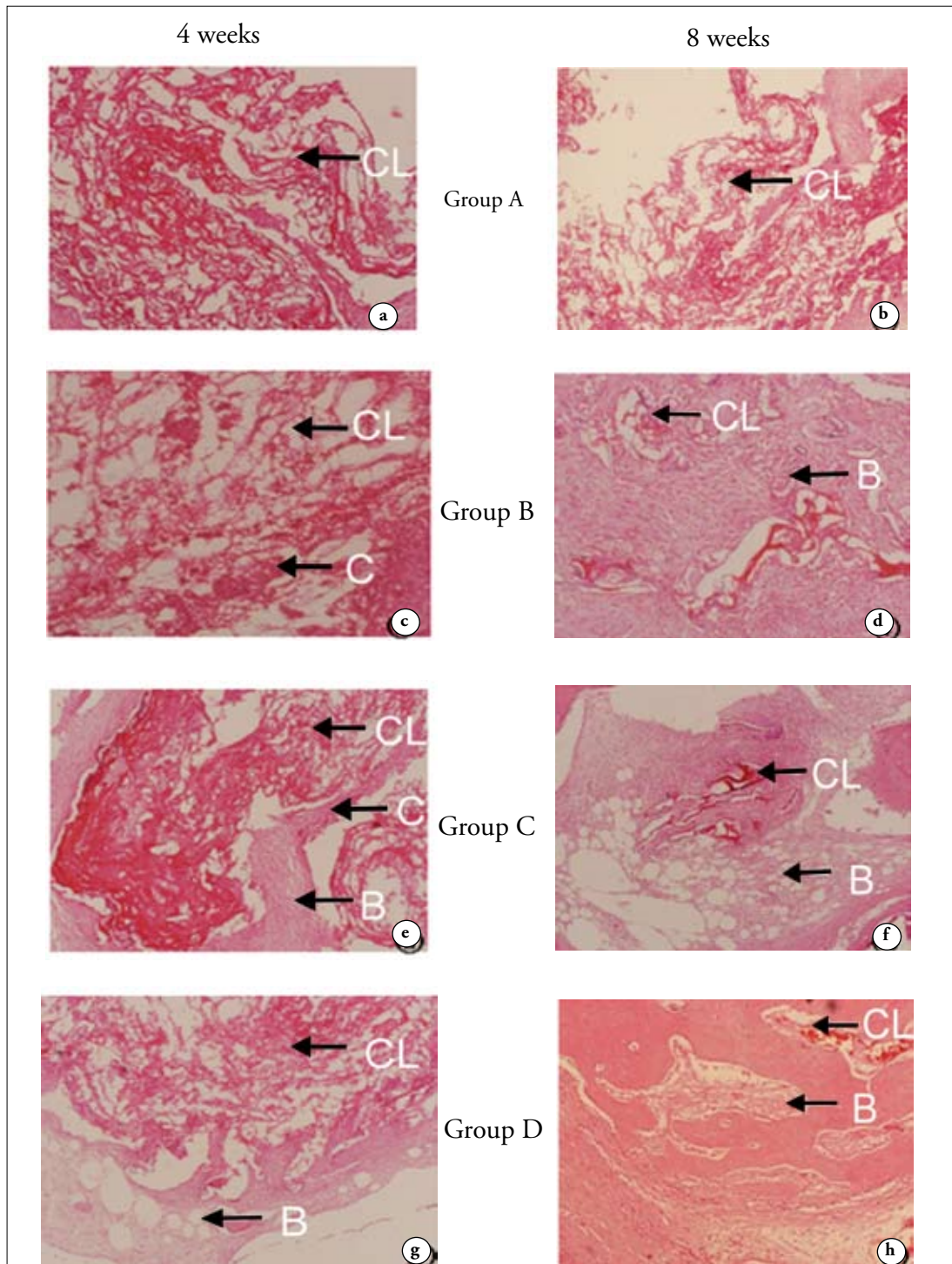


Figure 1 - Histological observation at 4 and 8 weeks after operation (Hematoxylin and Eosin [HE] $\times 100$) showing, a & b) collagen (CL [arrow]) partly absorbed and no bone and cartilage formation observed at 4 and 8 weeks postoperatively in group A, c) cartilage-like (C [arrow]) structure appeared, and CL has partly absorbed at 4 weeks after operation in group B, d) a few calcified bone (B [arrow]) tissue and increased CL resorption was found at 8 weeks after operation in group B, e) island-like of cartilages formed, and CL was partly absorbed at 4 weeks postoperatively in group C, f) increased CL resorption, matured bony structure, trabecula, and cavitas medullaris appeared at 8 weeks postoperatively in group C, g) the CL were partly absorbed, and a large quantity of cartilage and bones with bone trabecula-like structures and marrow cavity formed at 4 weeks postoperatively in group D, h) bone and lamellar bone presented, and CL was mostly absorbed 8 weeks after operation in group D.

Table 4 - Semi-quantitative evaluation of postoperative tissue at 4 and 8 weeks in groups B, C, and D in Scores (n=6).

Groups	Mean ± standard deviation			F-value	P-value
	4 weeks	8 weeks	Total		
Group B	1.350 ± 0.187	2.867 ± 0.258	2.108 ± 0.821	135.754	0.000
Group C	1.767 ± 0.258	3.750 ± 0.281	2.758 ± 1.067	162.025	0.000
Group D	2.217 ± 0.232	4.333 ± 0.476	3.275 ± 1.162	95.892	0.000
Total	1.778 ± 0.422	3.650 ± 0.703	2.714 ± 1.108	46.633*	0.000*
F	21.770	26.361	358.714*	3.386†	0.047†
P-value	0.000	0.000	0.030*		

*F statistic and P value of main effect; †F statistic and P value of crossover effect

proliferation/differentiation of many kinds of cells. All these procedures play an important role in bone formation and remodeling. In this study, owing to the limitation of time, we could not test the osteoinductive cooperativity by molecular biology.

In conclusion, the present results revealed that leptin and rhBMP-2 have cooperativity, but we could not demonstrate the effects whether leptin could alter the expression profile of genes/proteins that are associated with BMPs signaling and promoting bone formation in a dosage-dependent manner. Furthermore, we could not confirm whether these in vivo effects should be replicated in vitro using muscle-derived primary culture cells. Therefore, further work would be performed in this field to increase understanding of the pathways and mechanisms.

References

- Swiontkowski MF, Aro HT, Donell S, Esterhai JL, Goulet J, Jones A, et al. Recombinant human bone morphogenetic protein-2 in open tibial fractures. A subgroup analysis of data combined from two prospective randomized studies. *J Bone Joint Surg Am* 2006; 88: 1258-1265.
- Takaoka K, Yoshikawa H, Hashimoto J, Ono K, Matsui M, Nakazato H. Transfilter bone induction by Chinese hamster ovary (CHO) cells transfected by DNA encoding bone morphogenetic protein-4. *Clin Orthop Relat Res* 1994; 300: 269-273.
- Vaccaro AR, Whang PG, Patel T, Phillips FM, Anderson DG, Albert TJ, et al. The safety and efficacy of OP-1 (rhBMP-7) as a replacement for iliac crest autograft for posterolateral lumbar arthrodesis: minimum 4-year follow-up of a pilot study. *Spine J* 2008; 8: 457-465.
- Urist MR. Bone: formation by autoinduction. *Science* 1965; 150: 893-899.
- Chen B, Lin H, Wang J, Zhao Y, Wang B, Zhao W, et al. Homogeneous osteogenesis and bone regeneration by demineralized bone matrix loading with collagen-targeting bone morphogenetic protein-2. *Biomaterials* 2007; 28: 1027-1035.
- Burkus JK, Dorchak JD, Sanders DL. Radiographic assessment of interbody fusion using recombinant human bone morphogenetic protein type 2. *Spine (Phila Pa 1976)* 2003; 28: 372-377.
- Fujimura K, Bessho K, Okubo Y, Kusumoto K, Segami N, Iizuka T. The effect of fibroblast growth factor-2 on the osteoinductive activity of recombinant human bone morphogenetic protein-2 in rat muscle. *Arch Oral Biol* 2002; 47: 577-584.
- Nakamura Y, Tensho K, Nakaya H, Nawata M, Okabe T, Wakitani S. Low dose fibroblast growth factor-2 (FGF-2) enhances bone morphogenetic protein-2 (BMP-2)- induced ectopic bone formation in mice. *Bone* 2005; 36: 399-407.
- Kakudo N, Kusumoto K, Wang YB, Iguchi Y, Ogawa Y. Immunolocalization of vascular endothelial growth factor on intramuscular ectopic osteoinduction by bone morphogenetic protein-2. *Life Sci* 2006; 79: 1847-1855.
- Blumenfeld I, Srouji S, Lanir Y, Laufer D, Livne E. Enhancement of bone defect healing in old rats by TGF-beta and IGF-1. *Exp Gerontol* 2002; 37: 553-565.
- Thomas T, Martin A. Bone metabolism and energy balance: role for leptin. *Joint Bone Spine* 2005; 72: 471-473.
- Włodarski K, Włodarski P. Leptin as a modulator of osteogenesis. *Ortop Traumatol Rehabil* 2009; 11: 1-6.
- Gad HI. The potential osteogenic effects of systemic leptin and insulin administration in streptozotocin-induced diabetic female rats. *Saudi Med J* 2007; 28: 1185-1190.
- Xu J, Wu T, Zhong Z, Zhao C, Tang Y, Chen J. [Effect and mechanism of leptin on osteoblastic differentiation of hBMSCs] *Zhongguo Xiu Fu Chong Jian Wai Ke Za Zhi* 2009; 23: 140-144. Chinese.
- Cornish J, Callon KE, Bava U, Lin C, Naot D, Hill BL, et al. Leptin directly regulates bone cell function in vitro and reduces bone fragility in vivo. *J Endocrinol* 2002; 175: 405-415.
- Gruber HE, Ingram JA, Hoelscher GL, Hanley EN Jr. Leptin expression by annulus cells in the human intervertebral disc. *Spine J* 2007; 7: 437-443.
- Kaminski T, Smolinska N, Gajewska A, Siawrys G, Okrasa S, Kochman K, et al. Leptin and long form of leptin receptor genes expression in the hypothalamus and pituitary during the luteal phase and early pregnancy in pigs. *J Physiol Pharmacol* 2006; 57: 95-108.
- Xu JC, Wu T, Wu GH, Zhong ZM, Tang YZ, Chen JT. Leptin expression by heterotopic ossification-isolated tissue in rats with Achilles' tenotomy. *Saudi Med J* 2009; 30: 605-610.
- Hamrick MW, Della Fera MA, Choi YH, Hartzell D, Pennington C, Baile CA. Injections of leptin into rat ventromedial hypothalamus increase adipocyte apoptosis in peripheral fat and in bone marrow. *Cell Tissue Res* 2007; 327: 133-141.

20. Magni P, Motta M, Martini L. Leptin: a possible link between food intake, energy expenditure, and reproductive function. *Regul Pept* 2000; 92: 51-56.
21. Astudillo P, Rios S, Pastenes L, Pino AM, Rodriguez JP. Increased adipogenesis of osteoporotic human-mesenchymal stem cells (MSCs) characterizes by impaired leptin action. *J Cell Biochem* 2008; 103: 1054-1065.
22. Thomas T, Gori F, Khosla S, Jensen MD, Burguera B, Riggs BL. Leptin acts on human marrow stromal cells to enhance differentiation to osteoblasts and to inhibit differentiation to adipocytes. *Endocrinology* 1999; 140: 1630-1638.
23. Li PB, Jin H, Liu DX, Wang XY, Xu ZQ, Nan WK, et al. Study on the effect of Leptin on fibroblastic proliferation and collagen synthesis in vitro in rats. *Zhongguo Xiu Fu Chong Jian Wai Ke Za Zhi* 2005; 19: 20-22.
24. Gordeladze JO, Drevon CA, Syversen U, Reseland JE. Leptin stimulates human osteoblastic cell proliferation, de novo collagen synthesis, and mineralization: Impact on differentiation markers, apoptosis, and osteoclastic signaling. *J Cell Biochem* 2002; 85: 825-836.
25. Talavera-Adame D, Xiong Y, Zhao T, Arias AE, Sierra-Honigmann MR, Farkas DL. Quantitative and morphometric evaluation of the angiogenic effects of leptin. *J Biomed Opt* 2008; 13: 064017.
26. Murad A, Nath AK, Cha ST, Demir E, Flores-Riveros J, Sierra-Honigmann MR. Leptin is an autocrine/paracrine regulator of wound healing. *FASEB J* 2003; 17: 1895-1897.

Related topics

Al-Dokhi LM. Adipokines and etiopathology of metabolic disorders. *Saudi Med J* 2009 Sep;30(9):1123-32.

Xu JC, Wu T, Wu GH, Zhong ZM, Tang YZ, Chen JT. Leptin expression by heterotopic ossification-isolated tissue in rats with Achilles' tenotomy. *Saudi Med J* 2009; 30: 605-610.

Sanlier N. The effect of body composition on blood lipids, leptin, bone mineral density, and nutrition in females. *Saudi Med J* 2008; 29: 1636-1642.

Shafi R, Afzal MN. Status of serum leptin levels in females with infertility. *Saudi Med J* 2008; 29: 1419-1422.