

# Thrombosis of the internal jugular vein resulting from migration of a sharp esophageal foreign body

Yahya A. Al-Qabtani, MD, Khalid A. Al-Qabtani, MD.

## ABSTRACT

يعد التجلط الداخلي للوريد الوداجي من الحالات النادرة، غير أنها يمكن أن تكون قاتلة. نستعرض في هذا المقال حالة مريضة تبلغ من العمر 59 عاماً وقد تم تحويلها إلى المستشفى بعد مرور 3 أسابيع من تناول جسم غريب. وقد أجري لها تنظيراً داخلياً مرتين في المستشفى الذي حولها وكانت النتائج سلبية. كانت هذه المريضة تعاني من ألم وتورم في الجانب الأيسر من عنقها، وكشفت الأشعة المقطعية عن وجود جسم غريب محدب وأسطواني الشكل في الجهة اليسرى من الوريد الوداجي مع كتلة متجلطة كبيرة تحتوي على خراج مركزي وصغير. لقد تم إجراء عملية جراحية لاستئصال الجسم الغريب مع ربط الوريد الوداجي الأيسر. وكانت فترة النقاهة بعد الجراحة هادئة وخالية من الأعراض السلبية. نستنتج من هذه الدراسة أنه ينبغي على المراكز الطبية الصغيرة وغير مجهزة تحويل مثل هذه الحالات مباشرة إلى المراكز المجهزة لاستقبالها.

Internal jugular vein (IJV) thrombosis is a rare, but potentially fatal condition. A 59-year-old female patient was referred to our hospital 3 weeks after ingesting a foreign body (FB). Twice endoscopic examinations at the referring hospital were negative. On arrival at our hospital, she was in pain, and the left side of her neck was swollen. A CT of the neck revealed the presence of a slender pointed radio-opaque FB in the left IJV together with a large thrombus containing a small central abscess. Surgical removal of the FB was performed together with ligation of the left IJV. The postoperative recovery was uneventful. Medical centers without proper diagnostic facilities should transfer such cases to better-equipped centers.

*Saudi Med J 2011; Vol. 32 (1): 77-79*

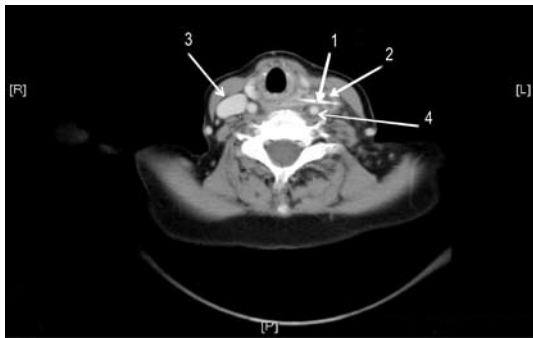
*From the Ear, Nose and Throat Department, Armed Forces Hospital, Khamis Mushayt, Kingdom of Saudi Arabia.*

*Received 4th October 2010. Accepted 29th November 2010.*

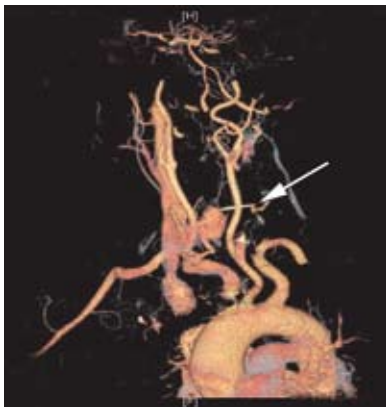
*Address correspondence and reprint request to: Dr. Yahya A. Al-Qabtani, Head of ENT Department, Armed Forces Hospital, PO Box 101, Khamis Mushayt, Kingdom of Saudi Arabia. Tel. +966 548031584. E-mail: yahyaalkabtani@hotmail.com*

In the literature, various cases have been described where foreign bodies (FB) are ingested and lodged in the upper aerodigestive tract, but only a few of these FB perforate the esophagus, and even fewer migrate extraluminally.<sup>1</sup> If untreated, they may result in life threatening suppurative or vascular complications. Exploration of the neck via an external approach to remove the FB is the recommended treatment. The CT scan is superior to plain radiographs for localization and identification of FBs in 83-100% of cases. The CT scan is highly reliable in localizing FBs in the esophagus.<sup>2,3</sup> Esophageal penetration, and migration of an esophageal FB into the left internal jugular vein (IJV), with a large thrombus containing a small abscess surrounding the intravascular part of the FB is extremely rare. We report an unusual case of an ingested FB that perforated the esophagus and penetrated the left IJV. A neck exploration was required to remove the foreign body. We present this case to study the management, presentation, and complication of this rare ingested FB.

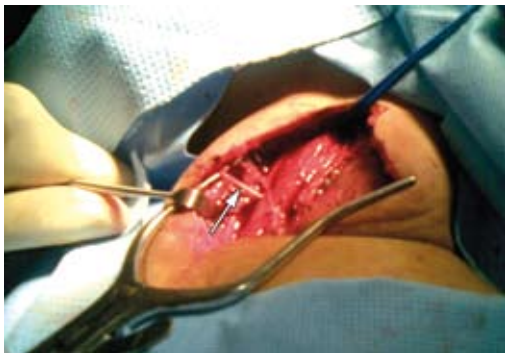**Case Report.** A 59-year-old edentulous female ingested a FB body during a meal. Rigid esophagoscopy carried out at a local hospital resulted in negative findings. As her condition persisted for 3 more days, revision endoscopy was carried out with the same negative results. Two weeks later, she was referred to our hospital with dysphagia, pain, and swelling of the left side of the neck, which was tender along the anterior border of the left sternomastoid muscle. She was afebrile. There was only mild congestion of the arytenoids on flexible endoscopy. A CT demonstrated the presence of a pointed radio-opaque slender FB approximately 3 cm long (Figure 1). Contrast CT scan, and angiography were carried out, which showed the FB was already in the left IJV, with a large thrombus containing a small abscess surrounding the intravascular part of the FB (Figure 2). The complete blood count (CBC), prothrombin time, activated partial prothrombin time, and biochemical tests were all within normal ranges. She was started on antibiotics and analgesics. Through an incision along the anterior border of the left sternocleidomastoid



**Figure 1** - The CT cut with contrast in the neck at the C6 level. Slender foreign body (1) traversing a thrombosed left internal jugular vein (2), while the right internal jugular vein is over-distended (3). (4) Left common carotid artery.



**Figure 2** - Three-dimensional image showing the foreign body transect the left internal jugular vein.



**Figure 3** - Left neck exploration of a foreign body.



**Figure 4** - Sharp, linear, serrated wood foreign body.

muscle (Figure 3), the carotid sheath was opened and the IJV vein ligated distal to the thrombus. The FB was removed and was found to be a piece of green wood (Figure 4) from a palm tree used in the preparation of meat recipes in rural areas. She made a full recovery.

**Discussion.** It is relatively common in the edentulous individual for a FB to be lodged in the pharynx or esophagus, being swallowed undetected due to the absence of the proper chewing process. This condition may become more exaggerated if structural anomalies of the esophagus are present, for example, strictures, webs, diverticulae, or motor dysfunction.

The vast majority of FBs become impacted in the tonsils, base of tongue, or vallecula. In approximately 75-80% of the cases, the FB becomes lodged at the cricopharynx upper gastrointestinal tract, or at one of the other constrictions along the esophagus, requiring a rigid esophagoscopy under general anesthesia for removal.<sup>4</sup> An even smaller fraction of cases occur in which the FB penetrates the esophageal mucosa and “migrates” through the deeper submucosal and muscular layers. Thrombosis of the IJV is a rare but potentially fatal condition. It usually arises following trauma to the IJV, but is also seen in association with coagulopathies and advanced malignancies as part of a para-neoplastic syndrome.<sup>5</sup> The incidence appears to be increasing secondary to the increased use of central venous catheters placed in the IJV and subclavian vein, and because of the increased use of the IJV by intravenous drug abusers.<sup>6</sup> In the reviewed literature, vascular catheter infections and catheter thrombosis are the 2 most common and serious complications, reported in 0-7.7 and 1.5-13%.<sup>7</sup>

Thrombosis of the IJV is very rare as a complication of migrating esophageal FB. Plain x-ray may fail to locate the exact site. Diagnosis is usually confirmed with Doppler ultrasound or CT scans with intravenous contrast. Ultrasonographic findings include a dilated and incompressible vein, intraluminal clot (a late finding), and lack of response to the Valsalva’s manoeuvre (expected change in intraluminal volume secondary to enhanced venous return). Ultrasonography is less accurate when the area under the mandible or clavicle is examined, and therefore CT with IV contrast is considered by many to be the study of choice for suspected IJV thrombosis. The CT scan findings include low-density intraluminal thrombus, a sharply defined bright vessel wall (contrast uptake by the vasa vasorum), soft tissue swelling surrounding the IJV, and a distention of the vein proximal to the thrombus.<sup>8</sup> Possible complications are numerous and may include the formation of deep neck abscess, thyroiditis, or thyroid abscess, esophageo-vascular fistula or skin granuloma.

Management requires neck exploration, FB removal, and preventing the possible embolization from the thrombus. In infants and children, prompt treatment of a suspected esophageal FB is crucial because of the potential for severe complications. Radiographic evaluation of the esophageal FB is warranted in both symptomatic and asymptomatic patients. Ingestion of foreign materials that are witnessed are generally managed without problems. Conversely, diagnosis of nonwitnessed ingestions can often be difficult and delayed. This delay in diagnosis can result in severe morbidity and mortality.<sup>9-11</sup>

In conclusion, the management of this rare presentation of ingested FBs becomes less daunting when approached systematically. A careful rigid esophagoscopy examination and one mm cut CT scan with and without oral contrast are the 2 important steps to a successful outcome. Systematic exploration of the neck via an external approach using the CT scan as a guide will decrease the chances of an unsuccessful exploration. Successful removal of the FB will prevent the occurrence of life threatening complications. Medical centers without proper diagnostic facilities should expedite transferring such cases to better equipped centers.

## References

1. Sreetharan SS, Prepageran N, Satwant S. Unusual migratory foreign body in the neck. *Singapore Med J* 2004; 45: 487-488.
2. Palme CE, Lowinger D, Petersen AJ. Fish bones at the cricopharynx: a comparison of plain-film radiology and computed tomography. *Laryngoscope* 1999; 109: 1955-1958
3. Eliashar R, Dano I, Dangoor E, Braverman I, Sichel JY. Computed tomography diagnosis of esophageal bone impaction: a prospective study. *Ann Otol Rhinol Laryngol* 1999; 108: 708-710.
4. Munter DW. Foreign Bodies, Gastrointestinal: Differential Diagnoses & Workup. [updated 2010 March 16] Available from URL: <http://emedicine.medscape.com/article/776566-diagnosis>
5. Ball E, Morris-Stiff G, Coxon M, Lewis MH. Internal jugular vein thrombosis in a warfarinised patient: a case report. *J Med Case Reports* 2007; 1: 184.
6. Jonas N, Fagan J. Internal Jugular Vein Thrombosis: A Case Study and Review of the Literature. *The Internet Journal of Otorhinolaryngology* 2007. Volume 6. [updated 2009 Feb 13] Available from URL: [http://www.ispub.com/journal/the\\_internet\\_journal\\_of\\_otorhinolaryngology/volume\\_6\\_number\\_2\\_11/article/internal\\_jugular\\_vein\\_thrombosis\\_a\\_case\\_study\\_and\\_review\\_of\\_the\\_literature.html](http://www.ispub.com/journal/the_internet_journal_of_otorhinolaryngology/volume_6_number_2_11/article/internal_jugular_vein_thrombosis_a_case_study_and_review_of_the_literature.html)
7. Vlasveld LT, Rodenhuis S, Rutgers EJ, Dubbelman AC, Hilton AM, Batchelor D, et al. Catheter-related complications in 52 patients treated with continuous infusion of low dose recombinant interleukin-2 via an implanted central venous catheter. *Eur J Surg Oncol* 1994; 20: 122-129.
8. Shankar L, Hawke M, Mehta MH. The radiologic diagnosis of internal jugular vein thrombosis. *J Otolaryngol* 1991; 20: 138-140.
9. Dokler ML, Bradshaw J, Mollitt DL, Tepas JJ 3rd. Selective management of pediatric esophageal foreign bodies. *Am Surg* 1995; 61: 132-134.
10. Emslander HC, Bonadio W, Klatzo M. Efficacy of esophageal bougienage by emergency physicians in pediatric coin ingestion. *Ann Emerg Med* 1996; 27: 726-729.
11. Gilchrist BF, Valerie EP, Nguyen M, Coren C, Klotz D, Ramenofsky ML. Pearls and perils in the management of prolonged, peculiar, penetrating esophageal foreign bodies in children. *J Pediatr Surg* 1997; 32: 1429-1431.

### Related topics

Al-Mazrou KA, Makki FM, Allam OS, Al-Fayez AI. Surgical emergencies in pediatric otolaryngology. *Saudi Med J* 2009; 30: 932-936.

Bhat VS, Al-Saadi KA, Bessiouni IE, Tuffaha AS. Embedded esophageal foreign body. A diagnostic challenge. *Saudi Med J* 2009; 30: 433-435.

El-Khushman HM, Sharara AM, Sa Ada MA, Hijazi MA. Tracheobronchial straight metallic pin aspiration in young Jordanian females. *Saudi Med J* 2007; 28: 913-916.

Gunay N, Isir AB, Yildirim C, Akieke M. A rare foreign body into the male penile urethra. *Saudi Med J* 2006; 27: 704-706.