

## Brief Communication

### Single port videothoracoscopy under epidural anesthesia for undiagnosed pleural effusions. *An alternative approach*

Serbat Yalcinkaya, MD,  
Ahmet H. Vural, MD, Ahmet F. Ozyazicioglu, MD.

Pleural effusion is a common medical problem and may occur due to various causes.<sup>1</sup> Diagnostic investigations include thoracentesis, closed pleural biopsy, thoracoscopy (TC), video-assisted thoracic surgery (VATS), and thoracotomy.<sup>2</sup> Thoracoscopy is a minimally invasive procedure that allows visualization of the pleural space and intrathoracic structures, allows obtaining pleural biopsies under direct vision, therapeutic drainage of effusions, and pleurodesis in one session.<sup>2</sup> Pulmonologists usually perform TC under local anesthesia, regional anesthesia, and/or sedation with the use of a single port in a thoracoscopy suite.<sup>3</sup> We planned to perform videothoracoscopy (VT) in the operation room under general anesthesia (GA) in our first patient. In order to avoid the disadvantages of GA in a 73 year-old female patient with hypertension and compensated cardiac failure referred to our department due to undiagnosed pleural effusion, we performed single port VT under thoracic epidural anesthesia (TEA) in September 2002. Following successful initial use in 3 consecutive patients in 2 months with a median age of 71 years, we started using the method as a standard procedure in patients presenting with undiagnosed pleural effusion.

The anesthesiologist performed epidural anesthesia using an epidural catheter at the T4-T5 level. After the initial local anesthesia of skin using 2 ml of 2% lidocaine hydrochloride (Jetmonal ampoule 2%, Adeka Drug Co., Samsun, Turkey), the anesthesiologist placed the 18 G epidural catheter (Portex® Epidural Minipac, Smiths Medical ASD Inc., Keene, NH 03431, USA) and directed it approximately 2 cm downwards in the epidural space. Anesthesia was then administered using a combination of 6 ml of 0.05% bupivacaine (Marcaine 0.05% vial, AstraZeneca Drug Co., Istanbul, Turkey), 2 ml of fentanyl (Fentanyl-Janssen ampoule, Janssen Pharmaceutica N.V., Beerse, Belgium), and 2 ml of saline solution. Following the initial dose, we positioned the patient lying on the affected side. Once the anesthesia was effective, we positioned the patient with the affected side up. We monitored the patients for heart rate, blood pressure, and pulse oxymetry. The patients received O<sub>2</sub> through a face mask at a rate of 3-5 l/min during the procedure.

All patients were operated from the sixth or seventh intercostal space at the midaxillary line on the affected side. Iodine solution was used for skin preparation. After a 2 cm skin incision, we used blunt dissection to enter the pleural space. In order to exclude any adhesions, we used digital exploration. After placing the 12 mm Thoracoport, we introduced the conventional Hopkins straight forward telescope thoracoscope (Karl Storz Endoskope, Germany) with an attached CCD camera (Telecam DX PAL, Karl Storz Endoskope, Germany) to the pleural space for visual exploration and biopsy. Following biopsy, we placed a 32 Fr chest tube attached to an underwater seal drainage system. Before the patients were transferred to a bed, a final dose of 10 ml of the drug cocktail was administered, and the epidural catheter was withdrawn. All biopsy specimen were sent for pathologic examination.

Between September 2002 and June 2011, 50 patients underwent VT under TEA. Following permission granted by the Local Ethical Committee for an archive study, the files of all these patients referred to the Thoracic Surgery Department of Bursa Yuksek Ihtisas Hospital for Education and Research due to undiagnosed pleural effusion were reviewed. The age, gender, affected side, time until anesthesia, duration of operation, complications (if any), diagnosis, additional procedures (if any), and length of hospital stay were noted from the charts. We used Microsoft Office 2007 Excel software in the data evaluation.

There were 26 male (52%) and 24 female (48%) patients with an average age of 59.3 ± 10.9 years (range 36-83 years). Forty patients were more than 50 years old. Hypertension was noted in 38 (76%), cardiac dysfunction in 26 (52%), chronic pulmonary disease in 24 (48%), cardiac rhythm disorders in 15 (30%), and diabetes in 8 (16%) of the patients. The affected side was right in 30 (60%), and left in the remaining 20 (40%). The anesthesia was started at an average of 15 minutes (range 12-18 minutes), and the average operation time was 24 minutes (range 20-30 minutes). The diagnosis was pleural effusion due to infections other than tuberculosis in 20 (40%), pleurisy due to tuberculosis in 14 (28%) (Figure 1), malignant pleural mesothelioma in 7 (14%), and metastatic malignancy in 5 (10%) patients. In 4 patients (8%), no differential diagnosis could be made. In 12 patients with malignant pleural effusion, chemical pleurodesis with either talc slurry (n=8), or bleomycin (n=4) as an adjunct to drainage following diagnosis was performed. Patients were discharged from the hospital on the day of drain removal. The average length of hospital stay was 5.1 ± 2.3 days (3-11 days).

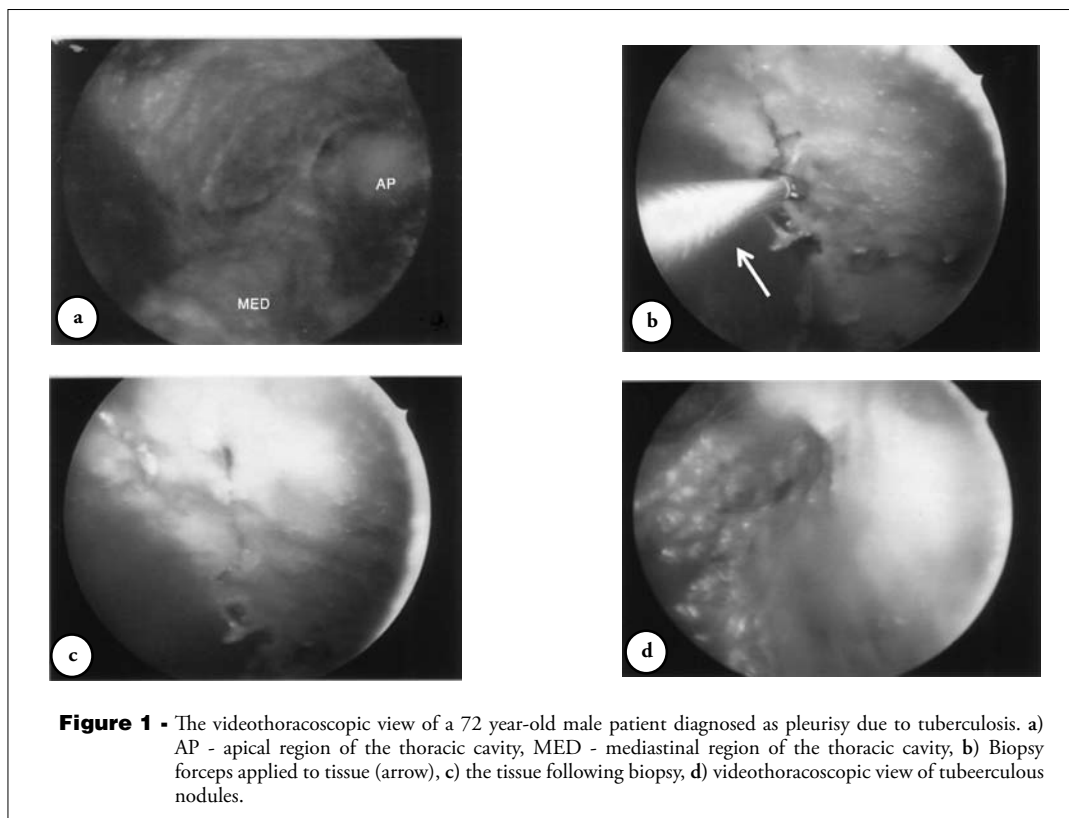
In all patients, the initial dose of drug combination was sufficient for complete anesthesia of the operation region, and no patient needed additional local infiltration anesthesia. All of the patients returned to their beds following surgery, except for 2 patients who needed O<sub>2</sub> supplement therapy in the recovery room. One of the patients needed O<sub>2</sub> for 3 hours, whereas the other needed O<sub>2</sub> for 4 hours. No other operational or postoperative complications were encountered. In patients with pleural effusion, the pleural fluid assessment includes thoracentesis, percutaneous needle biopsy, and thoracoscopy.<sup>1</sup> In a prospective study<sup>4</sup> in 208 patients, the diagnostic yield of medical thoracoscopy was found to be 95% against to 62% for pleural fluid cytology, and against to 44% for percutaneous needle biopsy. In our practice the diagnosis percentage was 92%, which is slightly lower than reported. This may be due to the small number of patients in our study.

There are several benefits of TC technique under local or regional anesthesia including an increase in patient comfort, better pulmonary functions during the operation, biopsy under direct vision, smaller incision than thoracotomy, and shorter hospital stay.<sup>2</sup> General anesthesia, however, has many disadvantages

including increased risk of pneumonia, impaired cardiac performance, neuromuscular disorders, barotrauma, atelectasis in the dependent lung, right-to-left shunt of blood, and muscle paralysis.<sup>1</sup> Most recently Mineo et al<sup>5</sup> suggested that epidural anesthesia avoids these disadvantages, permits a faster operation room to ward transfer, and increases the non-invasiveness of the procedure. These advantages lead us to use epidural anesthesia in our patients requiring VT.

The single port technique for TC is preferred mostly, especially under local anesthesia.<sup>3</sup> Discomfort due to pain and stitches are limited to a single incision of 1.5-2 cm, which is the same as for chest tube insertion. The optimal point of entry depends on the patient's suspected disease a point of entry at the sixth, or seventh intercostal space is preferred, as most pleural malignancies are expected to be found in the lower area of the pleura. Accordingly, we preferred single port entry at the sixth or seventh intercostal space at the midaxillary line during our practice.

Alrawi et al<sup>2</sup> performed medical TC under local anesthesia on 20 patients, and reported their series in 2002, where they concluded that their new TC technique represented an acceptable alternative to the



traditional treatment of pleural effusions and empyema with comparable outcome parameters and morbidity. They suggested that the technique might eventually become the standard of care for the treatment of pleural effusions. The TC has a low rate of complications, chest pain after the procedure being the most common. Other reported complications are empyema, prolonged air leakage, subcutaneous emphysema, postoperative fever, wound infection, cardiac arrhythmias, hypotension, bleeding, and seeding of chest wall from mesothelioma. We performed single port VT under TEA in the operating room with a diagnosis rate over 90% as a standard procedure in undiagnosed pleural effusions, and besides the 2 patients needed O<sub>2</sub> therapy in the recovery room, we did not experience any complications in our series.

We conclude that VT under TEA in the operating room maybe a good adjunct in the diagnosis of pleural effusions. With the help of experienced and willing anesthesiologists, this technique offers fast and complete anesthesia. Although we did not use visual analogue scale and patient comfort scale, we believe the patients were more comfortable when compared to local anesthesia. The technique may offer shorter hospital stay, and higher diagnostic yield. We performed this technique in every patient with undiagnosed pleural effusion. Further studies with larger number of elderly patients with various co-morbidities in the prospective setting may prove it useful.

**Acknowledgment.** The authors wish to thank Dr. Hasan Ozal, for his initial effort, and the team of anesthesiology doctors (Alper Akin, Ali Ekber Yürekli, Filiz Ata, Ihsan Magunaci, and Sabin Yuksek) for their continuous help and support.

Received 18th May 2011. Accepted 8th August 2011.

From the Departments of Thoracic Surgery (Yalcinkaya), and Cardiovascular Surgery (Vural, Ozyazicioglu), Bursa Yuksek Ihtisas Hospital for Education and Research, Bursa, Turkey. Address correspondence and reprints request to: Dr. Serhat Yalcinkaya, Bursa Yuksek Ihtisas Egitim ve Arastirma Hastanesi, Gogus Cerrahisi Servisi, Yildirim 16330, Bursa, Turkey. Tel. +90 5053941627. Fax. +90 (224) 3605055. E-mail: drserhatyalcinkaya@gmail.com

## References

1. Hooper C, Lee YCG, Maskell N. Investigation of a unilateral pleural effusion in adults: British Thoracic Society pleural disease guideline 2010. *Thorax* 2010; 65: 4-17.
2. Alrawi SJ, Raju R, Acinapura AJ, Cunningham JN Jr, Cane JS. Primary thoracoscopic evaluation of pleural effusion with local anesthesia: an alternative approach. *JSLs* 2002; 6: 143-147.
3. Rahman NM, Ali NJ, Brown G, Chapman SJ, Davies RJ, Downer NJ, et al. Local anaesthetic thoracoscopy: British Thoracic Society Pleural Disease Guideline 2010. *Thorax* 2010; 65 (Suppl 2): 54-60.
4. Rodriguez-Panadero F, Janssen JP, Astoul P. Thoracoscopy: general overview and place in the diagnosis and management of pleural effusion. *Eur Respir J* 2006; 28: 409-421.
5. Mineo TC, Pompeo E, Mineo D, Tacconi F, Marino M, Sabato AF. Awake nonresectional lung volume reduction surgery. *Ann Surg* 2006; 243: 131-136.

## Ethical Consent

All manuscripts reporting the results of experimental investigations involving human subjects should include a statement confirming that informed consent was obtained from each subject or subject's guardian, after receiving approval of the experimental protocol by a local human ethics committee, or institutional review board. When reporting experiments on animals, authors should indicate whether the institutional and national guide for the care and use of laboratory animals was followed.