

## Case Report

# Bacillus Calmette-Guerins vaccination at birth causing tuberculous granulomatous lymphadenitis

Abdulaziz A. Al-Hassan, CABP, MD, Abumusa M. Absanullah, MBBS, MS.

### ABSTRACT

يعد مرض السل من المضاعفات النادرة التي يمكن حدوثها بعد التطعيم بلقاح هذا المرض (BCG)، حيث يمكن أن يؤدي إلى الإصابة بالتهاب العقد اللمفية الورمي الحبيبي. نستعرض في هذا المقال مجموعة من المرضى الذين أصيبوا بهذه المضاعفات بعد التطعيم بلقاح السل. تظهر أعراض المرض متأخرة وذلك بعد مرور أشهر من أخذ اللقاح، ويعد تشكل الأورام الحبيبية في العقد اللمفية من الدلائل التشخيصية على حدوث مرض السل، كما أن ظهور عصابات مرض السل في العينات النسيجية يعد من الدلائل على وجود هذا المرض.

A rare but severe complication of Bacillus Calmette-Guerin (BCG) vaccination is the development of BCG disease, which can result in necrotizing granulomatous lymphadenitis. Symptoms can present as late as several months following the BCG vaccination. The key finding in BCG disease is the formation of caseating granulomas in draining lymph nodes; detection of BCG organisms from tissue samples are evident.

*Saudi Med J 2011; Vol. 32 (4): 412-414*

*From the Department of Pediatric Medicine (Al-Hassan) and the Department of Pediatric Surgery (Absanullah), Domat Al-Jandal General Hospital, Al-Jouf, Kingdom of Saudi Arabia.*

*Received 3rd November 2010. Accepted 31st January 2011.*

*Address correspondence and reprint request to: Dr. Abdulaziz A. Al-Hassan, Department of Pediatric Medicine, Domat Al-Jandal General Hospital, PO Box 866, Al-Jouf, Kingdom of Saudi Arabia. Tel. +966 504552850. Fax. +966 (4) 6224660. E-mail: dr\_asddo@hotmail.com*

**B**acillus Calmette-Guerin (BCG) vaccine, used against *Mycobacterium tuberculosis* (MTB) infection is named after the 2 French investigators responsible for the development of this vaccine. This vaccine was developed first from an attenuated strain of *Mycobacterium bovis* by subculture every 3 weeks for 13 years. This strain was distributed to many laboratories that continued to subculture the organism on different

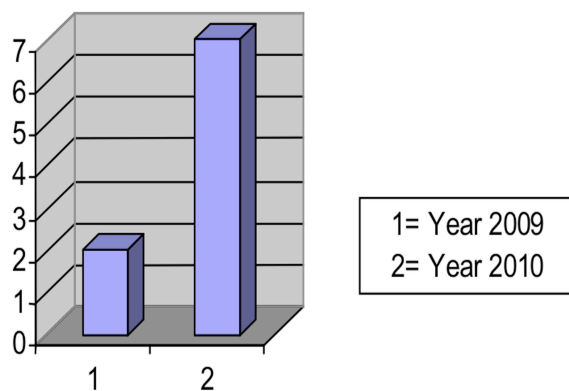
media under various conditions. As a result, there has been production of many vaccines that differ widely in morphology, growth, characteristics, sensitizing potency, and animal virulence.<sup>1</sup> The route of administration and dosing schedule for BCG vaccine are important factors for efficacy. The preferred route of administration is intradermal injection on the upper left arm with a very small dose of 0.05 ml of vaccine by a fine needle, 10 mm, 26 gauge. Although serious complications with BCG vaccines are uncommon, but can range from local symptoms of abscess formation and ulceration at the inoculation site to necrotizing granulomatous disease of the regional lymph nodes in 0.1-1% of vaccine recipients.<sup>1</sup> Local lesions do not suggest that host immune is lowered and do not affect the level of protection by the vaccine. Most local reactions are mild and they usually resolve spontaneously, but in some cases anti-biotherapy is needed. Surgical excision of a suppurative draining node is rarely necessary and should be avoided when ever possible.<sup>1</sup> After BCG vaccination usually there is no complain, but rarely may be associated with fever, convulsion, loss of appetite, and irritability.<sup>1</sup>

The official recommendation of BCG vaccine scheduled by the World Health Organization is a single dose administered during infancy. In this study, those patients are presented who developed necrotizing granulomatous disease of regional lymph node following BCG vaccination. We report these cases because of infrequent occurrence, but with increasing awareness, which may need further evaluation and clinical trials, so that these cases can be managed more uniformly.

**Case Reports.** These patients were present with necrotizing granulomatous disease of the regional lymph node after BCG vaccination, were first seen

**Disclosure.** This study is not supported or funded by any research organization.

as consultation group at our hospital (out patient department) over a period of one year and 6 months, from 01 January 2009 to 30 June 2010. A total of 9 patients were detected with this complication of lymphadenitis, 7 patients with left axillary and 2 patients with left supraclavicular lymph node involvement. During this period, we observed a gradual increase in frequency of the complication. In the year 2009, only 2 patients were detected, but in the first 6 months of 2010, 7 patients were detected (Figure 1). Among the 9 patients, 3 girls and 6 boys, the average age of presentation was 3.5 months, with a range from 3 months to 12 months. In all patients, BCG vaccine was given at birth on the upper left arm by intradermal route. After a latent period of 2-8 months there was a gradual enlargement of only one regional lymph node in one particular patient. No other lymph node group was involved. Six patients presented as lymph node abscess and 3 presented as lymphadenitis. Systemic review was unremarkable. Basic blood investigations and chemistry were within normal range. Chest radiography was normal. Mantoux tuberculin skin test was positive. Fine needle aspiration cytology (FNAC) from the affected lymph node was carried out in 5 patients and were reported to have a pattern of caseating and follicular granulomatous inflammatory tuberculous lymphadenitis consistent with BCG disease. The FNAC was carried out as part of diagnostic procedure of histopathological confirmation. It was observed that the trauma of FNAC may have expedited the formation of abscess. So, later treatment was started on the basis of clinical assessment without histopathological confirmation. Incision and drainage of the abscess and excision of the remaining lymph nodes were carried out in 6 cases. Pus was sent for Zeihl-Nelsen stain for acid fast bacillus (AFB) and also culture. Lymph nodes were sent for histopathology. In one case of supraclavicular lymph node abscess and necrosis of overlying skin, pus was too little for sampling.



**Figure 1** - Number of cases with lymphadenitis detected in the year 2009 and in the first 6 months of 2010.

All the samples for Zeihl-Nelsen stain demonstrated AFB. Histopathology of lymph nodes demonstrated the caseating and follicular granulomatous inflammatory tuberculous lymphadenitis, but no growth of AFB in the culture. Among the surgical patients, postoperative recovery and wound healing were uneventful. All the patients were treated with INH (Isoniazide) 10mg/kg/day for a initial duration of 12 weeks.<sup>2</sup> Patients were treated and followed up with Mantoux tuberculin skin test, complete blood count, liver function test, and chest radiology as out patient basis.<sup>3</sup>

**Discussion.** Granuloma may be defined as a small area composed of granulation tissue resulting from injury, inflammation or infection. In most of the cases of BCG disease, granulomas are present uniformly.<sup>4</sup> Characteristically, BCG vaccine also causes necrotizing granulomas same as MTB. It is a matter of debate about the cause of these granulomatous lesions. It may be the result of hypersensitivity reaction only or because of the hematogenous spread of BCG bacteria. Cultures of the involved tissue showed positive results in many reported cases, but in our cases, BCG organisms was not detected on culture. Tuberculosis of superficial lymph nodes is the most common form of extra pulmonary tuberculosis in children, known as Scrofula.<sup>5</sup> This occurs by drinking unpasteurized cow's milk laden with *Mycobacterium bovis*. Most current cases occur within 6-9 months of primary infection. The tonsillar, anterior cervical, submandibular, and supraclavicular lymph nodes becomes involved secondary to primary lesion of upper lung fields or abdomen. The nodes enlarges gradually in the early stage of lymph node disease. Nodes involvement is mostly unilateral but may be bilateral. Systemic signs and symptoms, other than low-grade fever, are usually absent. Mantoux tuberculin skin test is usually reactive, chest radiology is normal in 70% cases. Tuberculous lymphadenitis usually respond well with antitubercular drugs, although may take many months to years for lymph nodes to come to normal size. Some times may need surgical removal of the enlarged lymph node.<sup>1,5</sup>

The Mantoux tuberculin skin test is the intradermal injection of 0.1ml containing 5 tuberculin unit (TU) of purified protein derivative (PPD), that induce indurations through vasodilatation, edema, fibrin deposition and recruitment of inflammatory cells at the site of inoculation. The amount of indurations in response to the test should be measured 48-72 hours after administration. Previous vaccination with BCG can also cause a reaction to a tuberculin skin test, it usually causes <10 mm of induration. In general, a tuberculin skin reaction >10 mm in a BCG vaccinated child indicates infection with *Mycobacterium tuberculosis*.<sup>6</sup>

To avoid the development of tuberculosis disease, it is an established practice to start the treatment of children with asymptomatic tuberculosis infection (reactive tuberculin skin test, normal chest radiograph and normal physical examination). Any child with a positive tuberculin skin test but no clinical or radiological evidence of the disease should be treated with INH (Isoniazid) as this is highly effective in case of children. Current recommendation of regimen is of 2 weeks to 9 months of daily INH therapy. If the repeat tuberculin test is negative, INH is discontinued, but if the second skin test is reactive (>5 mm), the child has tuberculosis infection, and a full course of INH therapy must be given.<sup>1,7</sup> Disseminated BCG infections are not very common, but after BCG vaccination lymphadenitis are occurring with an increasing frequency. As there has not been much clinical trials, the treatment procedures are also inconsistent. Most antitubercular medications are effective against BCG organism. The length of treatment may be as short as 2 weeks in cases of mild symptoms or as long as 6-9 months for severe disseminated disease.<sup>5,8</sup> According to the results of a small study from South Africa, BCG vaccine administered at 10 weeks of age produces a better immune response against MTB than when given at birth. As the researcher explained that the protective effect of BCG vaccine against tuberculosis depends on the vaccine strain, the route of administration, dose and host immune response. As the cell-mediated immune response is "immature" at birth, they proposed for delaying the vaccination time, which could enhance the immune response by an increased production of "polyfunctional" BCG-specific CD4 T cells. "Polyfunctional cells make multiple cytokines together which are important for protection against TB.<sup>9</sup> Expanded Program on Immunization (EPI) of vaccination schedule was first designed in 1984. During the past years many new vaccines have been developed and included in the schedule. It was suggested in a previous study<sup>10</sup> that EPI schedule should be updated. Suggested updates includes reducing the number of doses, changing the vaccination schedule, and incorporating booster shots. Vaccines have effectively reduced the mortality rate among infants and children through out

the world. But it also has to be mentioned that many adverse events have been linked to vaccination, which needs further surveillance, collection, and reporting of adverse events following immunization both before and after licensure. Among the cases we have presented, we narrated the positive and the important negative findings only, but could not ascertain the exact cause of the lymphadenitis. We carried out this study for the probable possibilities of the complications.

In conclusion, although not so frequent, but we observed a gradual increasing frequency of regional tuberculous lymphadenitis after BCG vaccination. Thus, our recommendations are for long-term studies and clinical trials to evaluate the efficacy and the effect of BCG vaccination; and also to develop a protocol to address this complication more uniformly.

## References

1. Munoz FM, Starke JR. Mycobacterium tuberculosis; Bacille Calmette Guerin Vaccination. In: Behrman RE, Kliegman RM, Jenson HB, Stanton BF, editors. Nelson Text book of Pediatrics. 18th ed. Philadelphia, Pennsylvania: WB Saunders; 2007. p. 1240-1254.
2. Al-Dossary FS, Ong LT, Correa AG, Starke JR. Treatment of childhood tuberculosis with a six month directly observed regimen of only two weeks of daily therapy. *Pediatr Infect Dis J* 2002; 21: 91-97.
3. Polesky A, Grove W, Bhatia G. Peripheral tuberculous lymphadenitis: epidemiology, diagnosis, treatment and outcome. *Medicine (Baltimore)* 2005; 84: 350-362.
4. Gonzalez OY, Musher DM, Brar I, Furgeson S, Boktour MR, Septimus EJ, et al. Spectrum of bacille Calmette-Guérin (BCG) infection after intravesical BCG immunotherapy. *Clin Infect Dis* 2003; 36: 140-148.
5. McMaster P, Isaacs D. Critical review of evidence for short course therapy for tuberculous adenitis in children. *Pediatr Infect Dis J* 2000; 19: 401-404.
6. Lee E, Holzman RS. Evolution and current use of the tuberculin test. *Clin Infect Dis* 2002; 34: 365-370.
7. Hsu KH. Thirty years after isoniazid. Its impact on tuberculosis in children and adolescents. *JAMA* 1984; 251: 1283-1285.
8. Lamm DL. Efficacy and safety of bacille Calmette-Guérin immunotherapy in superficial bladder cancer. *Clin Infect Dis* 2000; 31 Suppl 3: S86-S90.
9. Shankar CV. Delayed BCG Vaccine May Improve Immune Response Against TB. *Vaccine* 2009; 27: 5488-5495.
10. O'Brien J. 12th Annual Conference on Vaccine Research.