

Cholecystectomy without intraoperative cholangiogram in gallstone pancreatitis

Hamad H. Al-Qabtani, CABS, FRCS, Mohammed K. Alam, MS, FRCS, Mohammed H. Al-Akeely, MBBS, CABS, Saleh M. Al-Salamah, MBBS, FRCS.

ABSTRACT

الأهداف: تحديد النتائج المحتملة على المدى الطويل لاستئصال المرارة بدون تصوير الأوعية الصفراوية وذلك لدى المرضى المصابين بالتهاب البنكرياس الحاد الناتج عن الحصاة الصفراوية والذين لا يشكون من أية مشاكل في وظائف الكبد أو في نتائج التصوير.

الطريقة: أُجريت هذه الدراسة في مدينة الملك سعود الطبية، الرياض، المملكة العربية السعودية، حيث قمنا باسترجاع سجلات المرضى المصابين بالتهاب البنكرياس الناتج عن الحصاة الصفراوية، والذين خضعوا لعملية استئصال المرارة بدون تصوير الأوعية الصفراوية وذلك خلال الفترة من يناير 2005م إلى ديسمبر 2009م. لقد قمنا باستثناء المرضى الذين يعانون من التهاب البنكرياس المزمن، أو أولئك الذين خضعوا للتصوير الرجوعي التنظيري لمجري الصفراء والبنكرياس. وبعد ذلك قمنا بجمع وتحليل البيانات التالية للمشاركين في الدراسة: بيانات المرضى الديموغرافية، والأعراض، ونتائج المختبر، والنتائج التي ظهرت قبل وبعد إجراء العملية الجراحية، ومدة البقاء في المستشفى، والمعلومات المتعلقة بمتابعة المرضى في العيادة الخارجية.

النتائج: لقد قمنا بعلاج ما مجموعه 160 مريضاً مصاباً بالتهاب البنكرياس الحاد من جراء الحصاة الصفراوية، وقد قمنا باستثناء 44 مريضاً ممن خضعوا للتصوير الرجوعي التنظيري لمجري الصفراء والبنكرياس قبل العملية (العدد=39)، أو ممن كان مصاباً بالتهاب البنكرياس المزمن (العدد=5). لقد خضع العدد المتبقي من المرضى (العدد=116) للعلاج التقليدي، والذي تبعه عملية استئصال المرارة من دون تصوير الأوعية الصفراوية، وتمت متابعة المرضى بمعدل 2-4 زيارة. أشارت نتائج الدراسة إلى دخول 5 مرضى (4.3%) مرة أخرى للمستشفى بسبب التهاب البنكرياس الانسدادي والنتائج عن الحصاة الصفراوية، ولقد تم استخراج الحصاة بالتصوير الرجوعي التنظيري لمجري الصفراء. ولقد تم فقدان 4 مرضى أثناء المتابعة، فيما لم يعاني العدد المتبقي من المرضى (107 مريضاً) من أية أعراض خلال المدة 12-55 شهراً بعد إجراء العملية الجراحية.

خاتمة: لقد كانت نسبة الإصابة بمشاكل البنكرياس والجهاز المراري الناتجة عن استئصال الحصيات المرارية من دون تصوير القناة الصفراوية لدى المرضى المصابين بالتهاب البنكرياس الانسدادي متدنية للغاية، ولهذا فإنه يمكن الاستغناء عن تصوير القناة الصفراوية.

Objectives: To determine the long term outcome of cholecystectomy without intraoperative cholangiogram

(IOC) in patients recovering from acute gallstone pancreatitis with normal preoperative liver function tests and imaging.

Methods: The medical records of all patients who underwent cholecystectomy without IOC for gallstone pancreatitis at King Saud Medical City, Riyadh, Saudi Arabia between January 2005 and December 2009 were studied retrospectively. Patients with severe pancreatitis and those who had preoperative endoscopic retrograde cholangio-pancreatography (ERCP) were excluded from the study. Data on patients' demography, symptoms, laboratory findings, intraoperative and postoperative findings, length of hospital stay, and outpatient follow up were collected and analyzed.

Results: A total of 160 patients were treated for acute gallstone pancreatitis. Forty-four patients with preoperative ERCP (n=39), and severe pancreatitis (n=5), were excluded. The remaining 116 patients initially underwent conservative treatment followed by cholecystectomy without IOC. All were followed up for an average of 2-4 visits. Five patients (4.3%) were re-admitted with gallstone related bilio-pancreatic complications. They underwent ERCP and CBD stone clearance. Four patients were lost to follow up. The remaining 107 patients have remained asymptomatic 12-55 months after cholecystectomy.

Conclusion: The incidence of bilio-pancreatic complications from unsuspected CBD stones in patients of biliary pancreatitis that underwent cholecystectomy without IOC is very low. Therefore, a routine IOC in these patients can be omitted safely.

Saudi Med J 2011; Vol. 32 (7): 714-717

From the Department of Surgery, College of Medicine, King Saud University, Riyadh, Kingdom of Saudi Arabia.

Received 23rd February 2011. Accepted 9th May 2011.

Address correspondence and reprint request to: Dr. Hamad H. Al-Qabtani, Assistant Professor & Consultant General and Hepatobiliary Surgeon, Department of Surgery, College of Medicine, King Saud University, PO Box 7805, Riyadh 11472, Kingdom of Saudi Arabia. Tel. +966 (1) 2074787. Fax. +966 (1) 2075655. E-mail: Hamad_qah@hotmail.com

Gallstone pancreatitis results from obstruction, usually transient, by the passing biliary duct stones at the ampulla of Vater. The clinical course of the disease is mostly mild but in few it may take a complicated course and result in morbidity and mortality.¹ Early cholecystectomy and clearance of bile duct stones, once the acute phase of the disease has subsided, can prevent further attacks. Delaying definitive treatment can put these patients at a higher risk of subsequent attacks of acute pancreatitis.² Since the introduction of laparoscopic cholecystectomy bile duct stones have usually been dealt with by preoperative endoscopic retrograde cholangiopancreatography (ERCP) in patients with deranged liver function tests (LFTs), biliary duct dilatation, or stones seen on imaging. However, in others with normal preoperative LFTs and imaging studies, routine intraoperative cholangiogram (IOC) is a recommended practice.^{3,4} This was the practice in our unit until the realization of a very low yield of routine IOC. This observation was supported by publications of similar conclusion by others.⁵ Over the last few years, at our unit, cholecystectomy in patients of biliary pancreatitis with a normal preoperative LFTs and ultrasonography is being performed without IOC. This retrospective study was undertaken to follow-up these patients for any long-term consequences of unsuspected bile duct stones as a result of omitting IOC.

Methods. In this retrospective study, the medical records of patients who were admitted with acute gallstone pancreatitis at King Saud Medical City, Riyadh, Saudi Arabia between January 2005 and December 2009 were retrieved. Only patients recovering from acute gallstone pancreatitis with a normal or near normal preoperative LFTs, and no extra hepatic bile duct dilatation who underwent cholecystectomy without IOC during the same hospital admission were analyzed and included in this study. Patients with severe pancreatitis and those who had undergone preoperative ERCP were excluded from the study. The records were reviewed for age, gender, presenting symptoms, laboratory findings, imaging studies, course, intraoperative and postoperative findings, complications, length of hospital stay, and OPD follow up. The diagnosis of acute gallstone pancreatitis was based on presentation with upper abdominal pain, a serum amylase level of >500 U/l (25-115 U/L), and presence of gallstones on trans-abdominal ultrasonography. The initial management included nil orally, fluids and electrolytes replacement, and analgesia. Oral feeding was introduced on clinical improvement and decline in serum amylase level. The LFTs were repeated preoperatively in all patients. Laparoscopic cholecystectomy was performed without IOC on complete clinical resolution during the same hospital admission. After discharge from the

hospital all patients were followed up in the outpatient department (OPD) with an average of 2-4 OPD visits over 3-6 months. They were discharged from the OPD if they remained completely asymptomatic. Before the commencement of this study all patients were contacted and recalled for clinical and LFT assessment in the OPD. Ethical approval was obtained from the department research committee before commencement of this study. The study was conducted according to the principles of Helsinki declaration.

We used the Statistical Package for Social Sciences (SPSS Inc., Chicago, IL, USA) version 17.0 to perform data analysis. Student t-test was used to compare all parameters. We assumed a statistically significant difference when $p < 0.05$. We also calculated mean and standard deviation and the range for all parameters.

Results. During the study period, 160 patients were treated for acute gallstone pancreatitis at our facility. Forty-four patients were excluded from the study for the following reasons: 1) preoperative ERCP for deranged LFTs and/or dilated biliary tree (≥ 8 mm) in imaging studies ($n=39$), and 2) severe pancreatitis ($n=5$). Preoperative ERCP revealed dilated CBD with sludge and evidence of recently passed stones ($n=15$), CBD stones that were extracted ($n=12$), and a normal CBD ($n=12$) (Figure 1). These patients were not included in data analysis. One hundred and sixteen patients, 73 women, and 43 men, were included in the study. Their mean age was 44.6 ± 10.5 years (range

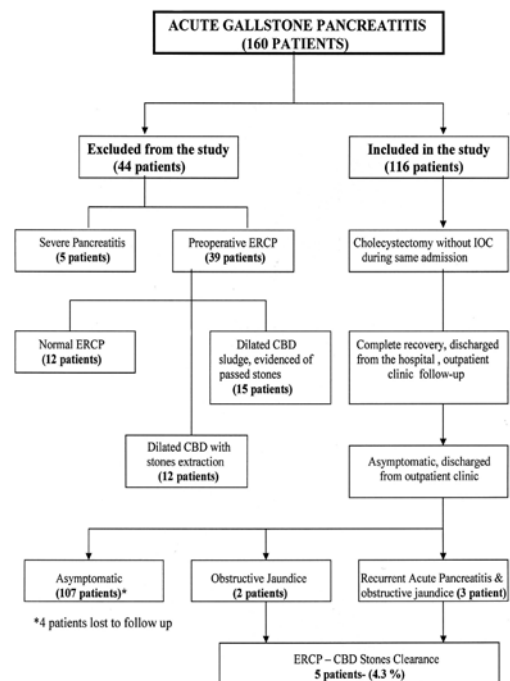


Figure 1 - Algorithm showing patients distribution and management.

Table 1 - Admission and immediate preoperative laboratory values of cholecystectomy without IOC patients (n=116).

Laboratory values	Mean admission value±SD (Range)	Mean immediate preoperative value±SD (Range)	P-value
WBC (x10 ³ /mm ³)	10.72±2.627 (5-17)	8.33±6.09 (4-71)	0.0000144
Amylase (IU/L)	1436.39±391.67 (772-2211)	96.49±16.57 (61-137)	0.00002
ALT (U/L)	106.84±25.845 (45-165)	46.79±9.39 (26-71)	0.000013
AST (U/L)	68.32±22.947 (29-131)	35.72±9.914 (19-121)	0.000021
ALP (U/L)	142.89±25.571 (14-181)	102.14±25.546 (8-145)	0.000015
TB (µmol/L)	24.22±6.44 (7-37)	11.98±4.44 (3-21)	0.000051
DB (µmol/L)	11.02±4.18 (2-17)	3.06±1.752 (1-8)	0.00005

IOC - intraoperative cholangiogram, WBC - white blood cells, ALT - alanine aminotransferase, AST - aspartate aminotransferase, ALP - alkaline phosphatase, TB - total bilirubin, DB - direct bilirubin, SD - standard deviation

28-71 years). The mean length of hospitalization from admission to cholecystectomy was 4.22±0.835 days (range 3-7 days), whereas the overall mean length of hospital stay was 6.66±1.128 days (range 5-10 days). There was a significant decrease in all laboratory values, returning almost to normal levels, between the admission and surgery dates (Table 1). All 116 patients underwent cholecystectomy without IOC. Laparoscopic cholecystectomy was successfully performed in 108 patients (93%) whereas in 8 patients it was converted to open cholecystectomy. All patients were discharged with an OPD follow up in one week. Four patients (3.5%) developed umbilical port site infection, which resolved with a course of cefuroxime and wound care. There was no mortality. Five patients (4.3%) developed bilio-pancreatic complications. Three patients were admitted 4, 7, and 11 months after cholecystectomy with recurrent acute pancreatitis with jaundice. They underwent ERCP with CBD stones clearance. Two patients, 4 months, and 15 months after cholecystectomy were admitted with obstructive jaundice. Their ERCP showed mildly dilated CBD, sludge and impacted stone at the ampulla of Vater, which was successfully cleared. One hundred and seven of the remaining 111 patients could be contacted by telephone on commencement of this study. All reported to have remained asymptomatic. They were asked to attend the OPD for clinical assessment and liver function test. However, only

101 patients attended the OPD clinic. They were all asymptomatic with normal LFTs 12-55 months after cholecystectomy. Four patients were lost to follow up.

Discussion. Gallstone pancreatitis accounted for 68.5% of acute pancreatitis in a study from Saudi Arabia,⁶ whereas in the USA the incidence is approximately 40% of all cases of pancreatitis.⁵ Treatment of acute gallstone pancreatitis has traditionally included surgical removal of the gallbladder and clearance of any stone in the CBD to prevent further attacks of pancreatitis. The risk of subsequent attacks of acute gallstone pancreatitis among patients recovering from the first attack is 30-fold higher than in the general population.² Therefore, early performance of cholecystectomy within one week of admission to the hospital has become the accepted standard of care.^{3,7} All patients in this study group had cholecystectomy performed within 7 days of hospital admission.

During the era of open cholecystectomy for gallstone pancreatitis, performance of IOC was mandatory with possible CBD exploration, to ensure a clear biliary passage. With the advent of laparoscopic surgery, preoperative ERCP was considered essential to clear CBD stones for a successful laparoscopic cholecystectomy.⁸ Currently, the most common practice to ensure CBD clearance is selective preoperative ERCP in patients with abnormal biochemistry or imaging and IOC in the remainder.^{9,10} Selective use of preoperative ERCP is currently the standard practice in our unit for patients with persistently elevated LFT with or without biliary dilatation or demonstrable stones within the CBD on ultrasonography. However, all patients who had preoperative ERCP were excluded from this study (Figure 1). In the early part of this decade, those who did not qualify for preoperative ERCP underwent routine IOC and laparoscopic cholecystectomy in our unit. With gradual realization of a very low yield of IOC and publications of similar conclusions by other authors,¹¹ the routine use of IOC markedly declined in our practice. During the last few years cholecystectomy in patients of biliary pancreatitis, with normal preoperative LFTs and ultrasonography, is being performed without IOC at our unit.

In the natural history of biliary pancreatitis, the majority of patients spontaneously pass the bile duct stones. A decrease in the incidence of bile duct stone from 70% on the admission day to less than 20% by the fourth day of admission has been reported. A decline in LFTs towards a normal level within 4-7 days of acute pancreatitis seen in our patients is probably evidence of a free bile duct due to spontaneous passage of stones. The incidence of unsuspected CBD stones in such low risk patients, with normal preoperative imaging and biochemistry, undergoing elective laparoscopic

cholecystectomy with IOC, varies between 2.8-5.8%.¹² Such patients rarely present with complications following laparoscopic cholecystectomy.¹⁰ Shayan et al⁵ recently concluded in their study that the incidence of CBD stones among patients recovering from acute mild to moderate gallstone pancreatitis with normal preoperative biochemistry and imaging is not significantly (7.6%) higher than patients undergoing elective laparoscopic cholecystectomy for symptomatic cholelithiasis. A very similar CBD stone rate in patients undergoing cholecystectomy for symptomatic gall stone disease or biliary pancreatitis has also been reported by other authors.¹³

Several authors have questioned the need for routine IOC in low risk patients undergoing cholecystectomy for biliary pancreatitis. Ito et al¹⁴ reported 8% recurrent pancreatitis due to retained stone in patients who did not have preoperative ERCP or IOC during cholecystectomy for biliary pancreatitis. He recommends to omit routine ductal evaluation in low risk patients. In the present study, only 5 patients (4.3%) developed symptoms due to missed CBD stones in a long term follow up after cholecystectomy without IOC. Such a low complication rate due to missed stones cannot justify routine IOC in low risk patients recovering from mild to moderate acute gallstone pancreatitis. Thus, routine IOC in such patients can safely be avoided.¹⁰ However, the retrospective nature of this study limits the strength of this recommendation, which needs to be supported by controlled trials.

Intraoperative cholangiogram in patients operated for acute gallstone pancreatitis results in a longer operative time and a prolonged postoperative course, but has no effect on the incidence of retained CBD stones.¹¹ Those who later develop symptoms even after a normal IOC will need re-evaluation by either ERCP or magnetic resonance cholangiopancreatography (MRCP). Thus, routine IOC does not alter the postoperative management of patients recovering from acute gallstone pancreatitis who develop recurrent symptoms.^{5,11} It is our belief that routine IOC will lead to more conversion to open surgery as the experience in laparoscopic exploration of CBD is limited. There is also a possibility of false positive IOC, which may lead to unnecessary CBD exploration. Therefore, avoiding the routine IOC in low risk patients (normal LFT, no bile duct dilatation or stone on ultrasound) will reduce the operative time, hospital stay, and the cost for the patients and healthcare providers. In our study, only 5 patients (4.3%) developed complications related to unsuspected bile duct stones due to omission of IOC during cholecystectomy. All were successfully treated by ERCP. Newer technologies for extrahepatic biliary tract evaluation, such as endoscopic ultrasonography, have greater than 90% sensitivity and 85% specificity

in identifying CBD stones.¹⁵ This may lead to a more selective CBD exploration. However, we have no experience with these techniques.

In conclusion, patients recovering from mild to moderate acute gallstone pancreatitis with normal preoperative biochemistry and imaging can safely undergo cholecystectomy without IOC. The long-term sequelae of unsuspected CBD stones are not significant to justify routine IOC.

References

1. Larson SD, Nealon WH, Evers BM. Management of gallstone pancreatitis. *Adv Surg* 2006; 40: 265-284.
2. Hernandez V, Pascual I, Almela P, Anon R, Herreros B, Sanchiz V, et al. Recurrence of acute gallstone pancreatitis and relationship with cholecystectomy or endoscopic sphincterotomy. *Am J Gastroenterol* 2004; 99: 2417-2423.
3. Schwesinger WH, Page CP, Gross GW, Miller JE, Strodel WE, Sirinek KR. Biliary pancreatitis: the era of laparoscopic cholecystectomy. *Arch Surg* 1998; 133: 1103-1106.
4. Chang L, Lo SK, Stabile BE, Lewis RJ, de Virgilio C. Gallstone pancreatitis: a prospective study of the incidence of cholangitis and clinical predictors of retained common bile duct stones. *Am J Gastroenterol* 1998; 93: 527-531.
5. Shayan H, Kopac D, Sample CB. The role of intraoperative cholangiogram in the management of patients recovering from acute biliary pancreatitis. *Surg Endosc* 2007; 21: 1549-1552.
6. Abu-Eshy SA. Pattern of acute pancreatitis. *Saudi Med J* 2001; 22: 215-218.
7. Nealon WH, Bawduniak J, Walser EM. Appropriate timing of cholecystectomy in patients who present with moderate to severe gallstone-associated acute pancreatitis with peripancreatic fluid collections. *Ann Surg* 2004; 239: 741-749.
8. Leitman IM, Fisher ML, McKinley MJ, Rothman R, Ward RJ, Reiner DS, et al. The evaluation and management of known or suspected stones of the common bile duct in the era of minimal access surgery. *Surg Gynecol Obstet* 1993; 176: 527-533.
9. Ricci F, Castaldini G, de Manzoni G, Borzellino G, Rodella L, Kind R, et al. Treatment of gallstone pancreatitis: six-year experience in a single center. *World J Surg* 2002; 26: 85-90.
10. Uhl W, Müller CA, Krähenbühl L, Schmid SW, Schölzel S, Büchler MW. Acute gallstone pancreatitis: timing of laparoscopic cholecystectomy in mild and severe disease. *Surg Endosc* 1999; 13: 1070-1076.
11. Bennion RS, Wyatt LE, Thompson JE. Effect of intraoperative cholangiography during cholecystectomy on outcome after gallstone pancreatitis. *J Gastrointest Surg* 2002; 6: 575-581.
12. Collins A, Maguire D, Ireland A, Fitzgerald E, O'Sullivan GC. A prospective study of common bile duct calculi in patients undergoing laparoscopic cholecystectomy: natural history of choledocholithiasis revisited. *Ann Surg* 2004; 239: 28-33.
13. Bertolin-Bernades R, Sabater-Orti L, Calvete-Chornet J, Camps-Vilata B, Cassinello-Fernandez N, Oviedo-Bravo M, et al. Mild acute biliary pancreatitis vs cholelithiasis: are there any difference in the rate of choledocholithiasis? *J Gastrointest Surg* 2007; 11: 875-879.
14. Ito K, Ito H, Tavakkolizadeh A, Whang EE. Is ductal evaluation always necessary before or during surgery for biliary pancreatitis. *Am J Surg* 2008; 195: 463-466.
15. Stabuc B, Drobne D, Ferkolj I, Gruden A, Jereb J, Kolar G, et al. Acute biliary pancreatitis: detection of common bile duct stones with endoscopic ultrasound. *Eur Gastroenterol Hepatol* 2008; 20: 1171-1175.