Operative laparoscopy in pregnancy for a large paraovarian cyst

Abdulrahim A. Rouzi, MBChB, FRCSC.

ABSTRACT

يعد اللجوء للجراحة التنظيرية خلال فترة الحمل ومن أجل استئصال الأكياس الظاهرة حول المبيض من الأمور الحديثة. نستعرض في هذا المقال حالة مريضة حامل للمرة الأولى تبلغ من العمر 26 عاماً وفي أسبوعها العشرين من الحمل، وقد تم اكتشاف إصابتها بالأكياس الملحقية أثناء التصوير بالأمواج فوق الصوتية. استئصلت الأكياس الموجودة حول المبيض والتي كانت بقياس 20–15 سم أثناء التنظير الجراحي وذلك بعد رشف 2.5 لتر من السوائل ومن دون ظهور أية مشاكل أثناء الجراحة. استغرقت العملية الجراحية 60 دقيقة، وقد خرجت المريضة من المستشفى بعد أقل من 24 ساعة من العملية الجراحية وبحالة جيدة. لقد كانت متابعة المريضة في عيادة المرضى الخارجية مرضية، كما وأكد التشريح النسيجي وجود الأكياس حول المبيض والتي كان حجمها يتراوح ما بين 20–15 سم. لقد ولدت المريضة مهبلياً وبطريقة تلقائية بعد إكمال تمام الحمل. يمكن أن تكون الجراحة التنظيرية أثناء فترة الحمل ومن أجل إزالة الأكياس الكبيرة الظاهرة حول المبيض من الطرق الآمنة.

The use of operative laparoscopy for paraovarian cysts in pregnancy is relatively new. A 26-year-old primigravida at 20 weeks of gestation was discovered to have a 20 x 15-cm adnexal cyst during ultrasound. Laparoscopic excision of the 20 x 15-cm paraovarian cyst after aspiration of 2.5 L of fluids was performed without complications. The operative time was 60 minutes. The patient was released from the hospital less than 24 hours after surgery in good general condition. Follow-up in the outpatient clinic was satisfactory. The final histopathology confirmed the 20 x 15-cm paraovarian cyst. The patient delivered vaginally and spontaneously at term. Operative laparoscopy may be safe for removing large paraovarian cysts during pregnancy.

Saudi Med J 2011; Vol. 32 (7): 735-737

From the Department of Obstetrics and Gynecology, King Abdulaziz University, Jeddah, Kingdom of Saudi Arabia.

Received 21st March 2011. Accepted 16th April 2011.

Address correspondence and reprint request to: Dr. Abdulrahim A. Rouzi, Department of Obstetrics and Gynecology, King Abdulaziz University, PO Box 80215, Jeddah 21589, Kingdom of Saudi Arabia. Tel. +966 505602587. Fax. +966 (2) 6408316. E-mail: aarouzi@gmail.com

Paraovarian cysts may arise from the Wolffian duct or paramesonephric duct remnants. They are simple cysts that usually range from 1- 8 cm in diameter. These cysts are generally asymptomatic, but may present with abdominal pain due to enlargement, torsion, or rupture.[1] In pregnancy, they are diagnosed because of pain, during physical examination, or routine ultrasonography. In a recent review of the of ovarian tumors in pregnancy, paraovarian cysts were the third most common type after benign cystic teratomas and serous cystadenomas.[2] Surgical treatment for paraovarian cysts can be carried out by operative laparoscopy or laparotomy. In non-pregnant women, operative laparoscopy has almost replaced laparotomy.[3] Laparoscopy-assisted and laparoscopic management for large adnexal cysts was recently reported.[4,5] The aim of this case report is to document successful laparoscopic removal of a large paraovarian cyst during pregnancy.

Case Report. During routine ultrasonography at 20 weeks of gestation, a 26-year-old primigravida was found to have a 20 x 15-cm simple and unilocular adnexal cyst (**Figure 1**). She had conceived spontaneously without experiencing infertility. She complained of vague and infrequent mild to moderate pelvi-abdominal pain. On examination, she was well. Her vital signs were normal. Abdominal examination revealed symphysis-fundal height of 28 cm with no tenderness and positive fetal heart. The situation was discussed in detail with the couple. Counseling regarding laparoscopy and conversion to laparotomy was carried out. Operative laparoscopy under general endotracheal anesthesia was performed at 20 weeks gestation at King Abdulaziz University, Jeddah, Saudi Arabia. Entry into the abdomen was through a left sub-costal incision. Secondary and tertiary punctures were made through 5 mm incisions in the right and left lower quadrants under direct vision. Total removal of the 20 × 15-cm paraovarian cyst was completed without complications. The procedure involved detailed visualization of the abdominal cavity followed by aspiration of 2.5 L of fluids from the cyst and hydro-dissection to excise the

cyst in the usual manner (**Figures 2, 3, & 4**). A 10 mm trocar placed in the middle supra-pubic area under direct vision was used to remove the specimens and were sent to the histopathology department (**Figure 5**). The operative time was 60 minutes. The patient was released from the hospital less than 24 hours after surgery in good general condition. Follow-up in the outpatient clinic was satisfactory. The final histopathology report confirmed the 20 × 15-cm simple paraovarian cyst as reported previously.[3] The patient had a spontaneous vaginal delivery at term.

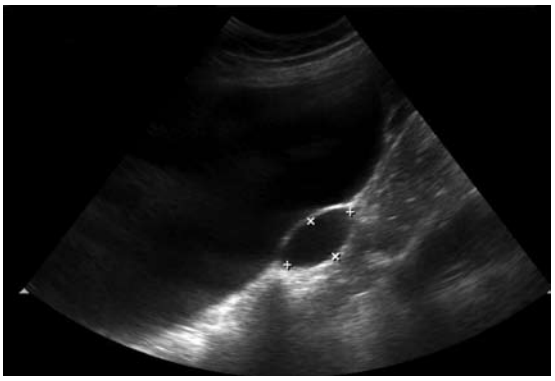

Figure 1 - Ultrasound picture of the right ovary and right paraovarian cyst.

Discussion. The incidence of diagnosing an adnexal mass by ultrasound in pregnancy is approximately 1%.[6] Management of adnexal masses in pregnancy is usually expectant, because (a) most lesions are discovered incidentally during routine ultrasonography and resolve spontaneously, (b) the incidence of malignancy is rare, and (c) unnecessary surgical interventions may lead to adverse maternal and fetal outcomes. However, in certain clinical situations, surgery can be lifesaving or of paramount importance (such as acute abdomen, large cysts, suspicion of malignancy, or obstructed labor). There are some issues with surgery during pregnancy: specifically, the gestational age at which the surgery is carried out, the circumstances at the time of surgery (elective or emergency), and the route of surgery (laparotomy or laparoscopy). Ideally, surgery should be carried out electively early in the second trimester (at approximately 15 weeks of gestation) to minimize the risks of spontaneous abortion if surgery is carried out in the first trimester and the risks of preterm labor and/or intrauterine fetal death if surgery is carried out late in the second trimester or in the third trimester. With respect

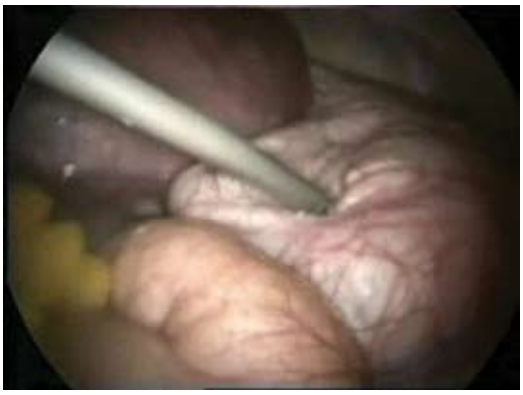

Figure 2 - Aspiration of the cyst.

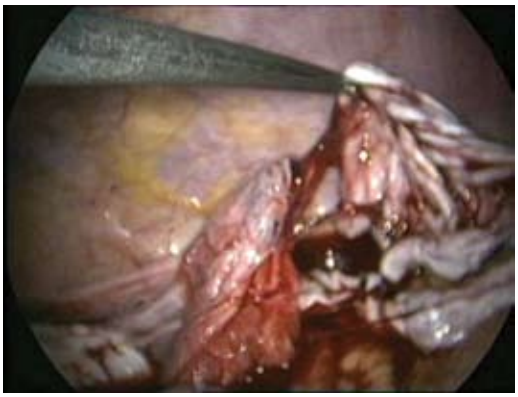

Figure 4 - Complete excision of the cyst.

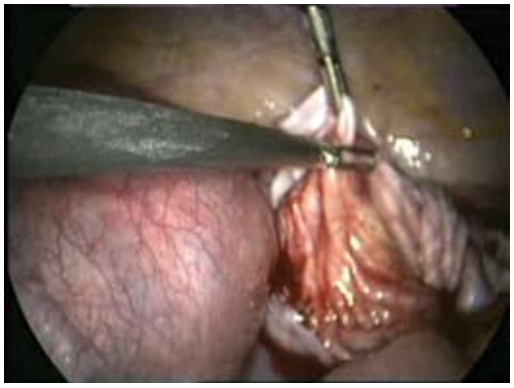

Figure 3 - Dissection of the cyst.

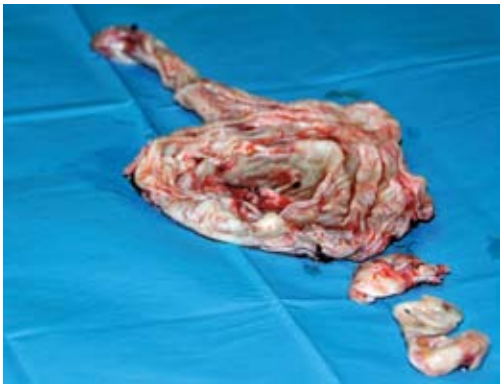

Figure 5 - Specimens for pathology

to the surgical route, excision of a cyst by laparotomy was once the standard treatment. Currently, operative laparoscopy is the most effective and preferred way of managing paraovarian cysts in non-pregnant women because of reductions in febrile morbidity, urinary tract infections, postoperative complications, postoperative pain, length of stay in the hospital, and cost. The possible risk of operating laparoscopically on malignant cysts can be minimized by proper selection of patients. Premenopausal women with unilateral, unilocular, and simple cysts with negative tumor markers are less likely to have malignant cysts. The importance of tumor markers during pregnancy is controversial. In addition, intraoperative assessment and careful assessment to rule out malignancy is of paramount importance. Laparoscopic options include excision, cyst fenestration, and marsupialization.[7] Laparoscopic management of small ovarian cysts during early pregnancy is gaining popularity over laparotomy.[8] However, laparoscopic removal of a large paraovarian cyst during pregnancy is not yet documented. Despite several MEDLINE and other searches of the terms "laparoscopy" , "large paraovarian cyst", and "pregnancy", nothing was reported. The case reported here suggests that in properly selected cases with adequate training and equipments removal of large paraovarian cysts during pregnancy is feasible and may be a safe treatment option. Further studies are needed to confirm it.

References

1. Perlman S, Hertweck P, Fallat ME. Paratubal and tubal abnormalities. ***Sem Pedia Surg*** 2005; 14: 124-34.
2. Bignardi T, Condous G. The management of ovarian pathology pregnancy. ***Best Prac Resear Clin Obstet Gynecol*** 2009; 23: 539-548.
3. Smorgick N, Herman A, Schneider D, Halperin R, Pansky M. Paraovarian cysts of neoplastic origin are underreported. ***JSLS*** 2009; 13: 22-26.
4. Göçmen A, Atak T, Uçar M, Sanlikal F. Laparoscopy-assisted cystectomy for large adnexal cysts. ***Arch Gynecol Obstet*** 2009; 279: 17-22.
5. Ron S, Abraham G, Marek G. Laparoscopic management of extremely large ovarian cysts. ***Obstet Gynecol*** 2005; 105: 1319-1322.
6. Dede M, Yenen MC, Yilmaz A, Goktolga U, Baser I. Treatment of incidental adnexal masses at cesarean section: a retrospective study. ***Int J Gynecol Cancer*** 2007; 17: 339-341.
7. Rouzi AA, McComb PF. Laparoscopic marsupialization of a parovarian cyst: A case report and review of the literature. ***J Obstet Gynaecol Can*** 1994; 16: 2267-2270.
8. Lee YY, Kim TJ, Choi CH, Lee JW, Kim BJ, Bae DS. Factors influencing the choice of laparoscopy or laparotomy in pregnant women with presumptive benign ovarian tumors. ***Int J Gyn Obstet*** 2010; 108: 12-15.

Related topics

Abdollahi SF, Bahlouli A, Mostafa PG, Rasooli S, Morteza G. Comparison of laparoscopy-assisted hysterectomies with conventional hysterectomies. ***Saudi Med J*** 2009; 30: 813-816.

Yildiz F, Terzi A, Coban S, Zeybek N, Uzunkoy A. The handmade endoloop technique. A simple and cheap technique for laparoscopic appendectomy. ***Saudi Med J*** 2009; 30: 224-227.

Diab AE, Abdul-Latif EE, Eldash M, Mahdy MS, Shalaby H, Shafik M. Laparoscopic supracervical hysterectomy compared with total abdominal hysterectomy. ***Saudi Med J*** 2008; 29: 1597-600.

Dilbaz B, Akdag D, Cengiz H, Akyunak A, Dilbaz S, Haberal A. Intraoperative complications of outpatient interval tubal sterilization at a teaching hospital in Turkey. ***Saudi Med J*** 2008; 29: 692-697.