

# Kidney metastasis of invasive ductal breast carcinoma mimicking renal cell carcinoma

Yigit Akin, MD, Isil Basara, MD.

## ABSTRACT

نستعرض في هذا المقال حالة سيدة تبلغ من العمر 56 عاماً وقد أتت إلى العيادات الخارجية بقسم المسالك البولية وكانت تعاني من دم شديد في البول يُرى بالعين المجردة. لقد شخصت حالتها على أنها مصابة بسرطان في الكلية اليمنى وذلك بعد الفحص السريري والإشعاعي، وبعد استئصال الورم بالكلية اليمنى بالتنظير أظهر الفحص الباثولوجي انتقال شديد للسرطان من الصدر إلى الكلية اليمنى. وبعد عمل التقييم الجسدي والإشعاعي لها تم تحويلها إلى قسم الجراحة العامة، وتم استئصال الثدي جذرياً بالإضافة إلى استئصال الغدد الليمفاوية الأبطية. وبعد ذلك تم تحويلها إلى قسم الأورام لعمل العلاج الكيميائي. لقد كان هدفنا من عرض هذه الحالة هو لفت انتباه الأطباء إلى الأورام التي يمكن أن تنتقل إلى الكليتين، كما يجب عليهم عمل الفحوصات اللازمة للثدي سنوياً.

A 56-year-old female patient was admitted to the urology outpatient clinic with severe macroscopic hematuria. She was diagnosed with right kidney cancer after clinical and radiological evaluations. Pathology reported a metastasis of invasive ductal breast carcinoma in the right kidney after laparoscopic radical right nephrectomy was performed. After physical and radiological evaluations, she was referred to the Department of General Surgery, and was treated with radical mastectomy and axillary lymph node dissection for breast cancer. She was later referred to the Department of Medical Oncology at our institute for chemotherapy. We aimed for clinicians to be more aware of metastasis to the kidney, and perform regular and thorough breast examination for women every year.

*Saudi Med J 2012; Vol. 33 (12): 1346-1349*

*From the Department of Urology (Akin), Erzincan University School of Medicine, Erzincan, and the Department of Radiology (Basara), Celal Bayar University School of Medicine, Manisa, Turkey.*

*Received 11th June 2012. Accepted 19th August 2012.*

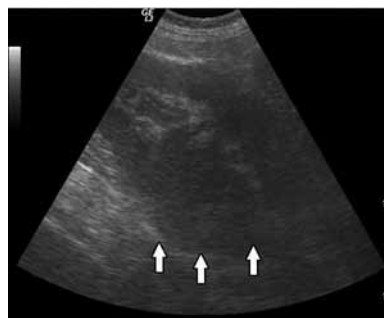*Address correspondence and reprint request to: Assistant Professor Yigit Akin, Department of Urology, Erzincan University School of Medicine, Erzincan 24040, Turkey. Tel. +90 (446) 2261818. Fax. +90 (446) 2261819. E-mail: yigitakin@hotmail.com*

Although the lung, bone, liver, lymph nodes, and skin are the most common sites for breast cancer metastasis, less frequently it involves the brain, adrenal glands, ovaries, spleen, pancreas, kidney, thyroid, and heart.<sup>1</sup> The kidney, urinary bladder, and retroperitoneum are considered as unusual sites of breast cancer metastasis.<sup>2</sup> Excluding lung, liver, or bone metastases, the statistical rate of metastasis from primary breast cancer is less than 3%.<sup>3</sup> In the literature, there are only few cases with initial kidney metastasis of breast cancer.<sup>2,4</sup> Patients with a history of renal mass and metastasis from a primary tumor should be considered. Renal metastasis usually presents in the late stages of primary tumor's dissemination.<sup>4</sup> Physical examination, laboratory and radiological evaluations should be performed for diagnosing the kidney metastasis. In differential diagnosis, primary renal tumors must be considered. Such suspicious metastatic kidney masses can be diagnosed with percutaneous renal biopsy exactly.<sup>2</sup> Treatment options depend on patient's general conditions, the stage of primary and metastatic tumors.<sup>4</sup> The aim of this article is to present unusual cause of hematuria, and also to increase awareness of metastasis to the kidney. Another purpose of the case report is to encourage women to undergo regular breast examination every year.

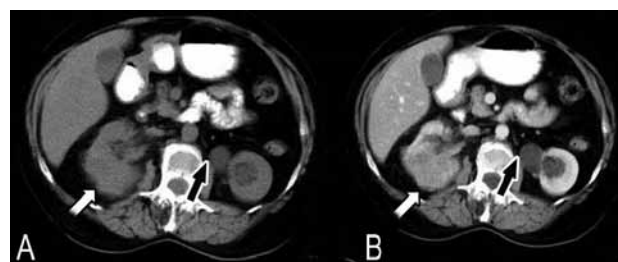
**Case Report.** A 56-year-old female patient was admitted to the Urology Outpatient clinic with severe, continued macroscopic hematuria for 2 days. Up to that time, she had no co-morbidity or operation history, except cesarean 28 years ago. Physical examination and laboratory tests were normal, and there was no palpable mass on the right side of the abdomen. In gray scale ultrasonography (US), there was a mass in

**Disclosure.** The authors have no conflict of interests, and the work was not supported or funded by any drug company.

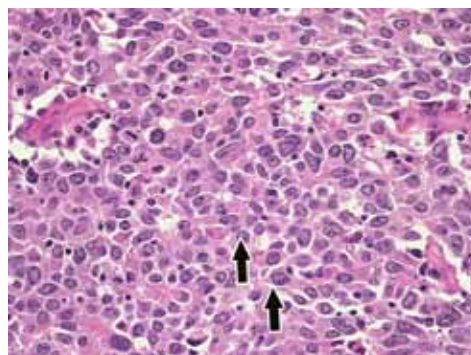
the right kidney with a diameter of 4.5 cm. The mass was extending to the calyceal structures of the right kidney as shown in **Figure 1**. After US was performed, the patient was redirected to the CT unit for further evaluation in order to investigate likely metastasis in the abdomen. An enhanced CT evaluation was performed. A solid, markedly enhancing right renal mass and left extra renal pelvis were determined (**Figures 2A & 2B**). In CT, the mass in the right kidney was extending, and nearly infiltrating the calyceal structures. The patient was diagnosed as right renal cell carcinoma in the light of clinical and radiological findings. The clinical stage was described as T1bN0M0.<sup>5</sup> Lung x-ray was performed, and there was no proof of metastasis of renal cell carcinoma before the operation. Additionally, there was no proof of metastasis in abdominal CT. Laparoscopic radical nephrectomy was performed for the right kidney mass. The pathology reported that the mass in the right kidney was a metastasis of invasive ductal breast cancer (**Figure 3**). Furthermore, immunohistochemical stains were performed and pathology demonstrated kidney metastasis of poorly differentiated invasive breast cancer and positive membrane staining for HER2/Neu as shown in **Figure 4**. She was referred to our institute's Department of General Surgery for breast cancer. Physical examination and mammography were performed. There was a palpable, sensitive, and painful mass on the lower-outer quadrant of the right breast in physical examination. The pattern of breast was liposclerosing (American College of Radiology type 3) pattern in mammogram. There was a cluster of microcalcification in the lower middle-outer quadrant of the right breast. Additionally, there was markedly pleomorphism in microcalcifications. The measure of the microcalcification area was approximately 15 mm (**Figure 5A**). In US of breast and axilla, there was microlobulated irregularly contoured solid mass in the right breast, and mass size was 16.3 x 9.1 mm, also there was metastatic lymph nodes with thick cortex in the right axilla in **Figures 5B & 5C**. Furthermore, the lesion was categorized as Breast Imaging Reporting and Data System 5 lesion. Additionally, there was no proof of bone metastasis in skeletal scintigraphy and thoraco-abdominal metastases in CT. Radical mastectomy and axillary lymph node dissection were performed for painful mass in the breast, and pathology report verified invasive ductal carcinoma (**Figure 6**). In follow-up procedure, the patient was referred to our institute's oncology clinic for chemotherapy regimens.<sup>4</sup> Six cycles of Doxorubicin and Paclitaxel were used for chemotherapy regimens. In follow-up, brain and bone metastasis occurred, and she died in 6 months.



**Figure 1** - A gray scale ultrasonography examination showing a hypoechoic solid mass measuring 45x40 mm at the lower pole of the right kidney (arrows). The echogenicity of the mass is heterogeneous. Additionally intra-renal collecting systems are minimal dilated. The degree of dilatation is grade 1.



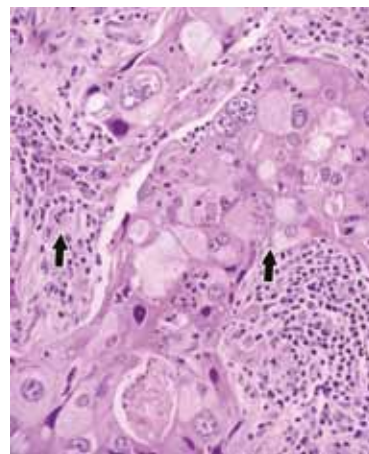
**Figure 2** - An image showing: A) in non-enhanced CT examination, there is a hypodense, irregular contoured, solid mass. There are striations at the peri-renal fatty tissue due to renal mass (white arrow shows mass in left kidney). Additionally, there is an extra-renal pelvis in the left kidney (black arrow). The diameter of the mass was 45 mm; B) in enhanced CT examination, there is significant enhancement in the right kidney mass (white arrow shows mass in right kidney, black arrow shows extra-renal pelvis in left kidney).



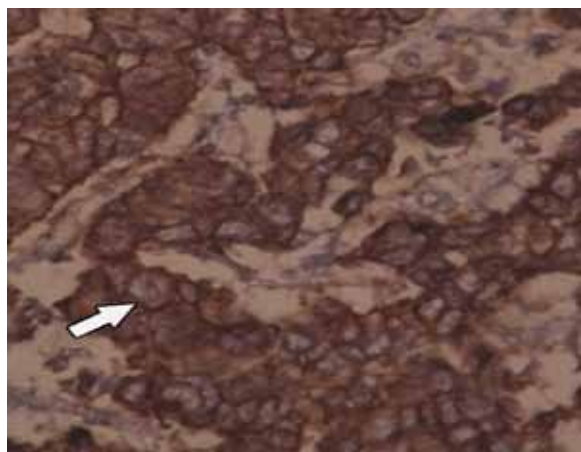
**Figure 3** - Histological features of metastasis. Arrows show poorly differentiated nuclei of invasive ductal carcinoma cells with dark stains, and they have less mitotic activity on gross fibrous stroma (H&E x100).

**Discussion.** Breast carcinoma usually metastasizes to the bone, lungs, and liver.<sup>6,7</sup> The central nervous system, endocrine organs (ovary, adrenal, pituitary), pericardium, peritoneum, spleen, retroperitoneal pelvic lymph nodes and eye are infrequently involved

organs.<sup>6-8</sup> However, tumor can be found in almost any site of the body. Urinary system (kidney ureter and bladder), pancreas, subcutaneous tissue, muscle, gallbladder, and retro-orbital region are extremely rare sites for metastasis of breast cancer.<sup>6-8</sup> The spread of the cancer to the kidney may be from a primary kidney cancer involving the opposite kidney, or from a cancer at a distant site. Urinary system metastasis of breast cancer, especially kidney metastasis is very rare. In patients with a history of malignancy, renal metastases outnumbered renal cell carcinomas by approximately 4:1.<sup>9</sup> Choyke et al<sup>9</sup> reported renal metastasis of different primary malignancies and they evaluated 27 patients with kidney metastasis arising from 8 different types of non-lymphomatous tumors. Most of the patients who were included in the study did not have any



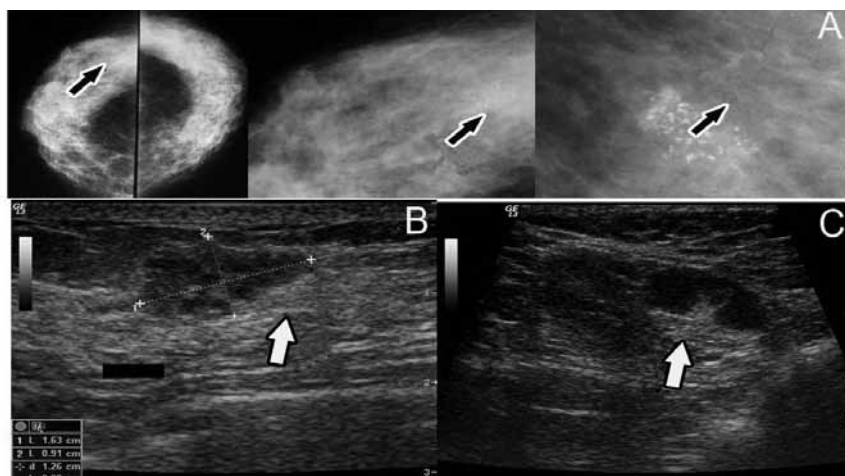
**Figure 6** - A poorly differentiated invasive ductal carcinoma is seen in the figure. Multinucleated tumor giant cells are also seen (arrows).



**Figure 4** - A positive membrane staining for Her-2/neu of metastasis of invasive ductal carcinoma in kidney. (HER-2/ neu + and H&E x100).

clinical symptoms of urinary system. Only 9 of the patients had macroscopic hematuria as our patient.<sup>9</sup> In radiological evaluations, metastatic masses were mainly multifocal, but metastases arising from lung, colon, and breast carcinomas were sometimes large, solitary, and otherwise indistinguishable from primary renal cell carcinoma.<sup>9,10</sup> Breast carcinoma is associated with contiguous, lymphatic, and hematogenous spread, and usually metastasize to bone, lungs, and the liver.<sup>6</sup> The renal parenchyma can be a site for hematogenous spread as in our case.<sup>7</sup>

Our case is unique in that kidney metastasis of breast cancer was represented with hematuria. Clinical presentations of metastasis in the kidney may range from hematuria to lumbar pain, or irritative voiding symptoms, such as urgency, or dysuria. On rare occasions, urinary metastases from breast cancer



**Figure 5** - Images showing: A) in cranio-caudal, medio-lateral oblique view, there is a cluster of pleomorphic microcalcifications (arrows); B) in the breast ultrasound examination, hypoechoic, microlobulated solid mass is noted (arrows); and C) in axilla, there is metastatic lymph node (arrow).



presented with hydronephrosis.<sup>11</sup> As in our case, the patient admitted with severe macroscopic hematuria. At first, we diagnosed the renal mass in the right kidney. We were redirected to invasive ductal breast carcinoma after laparoscopic right radical nephrectomy and pathological evaluations. Although Choyke et al<sup>9</sup> stated that CT is the most sensitive modality for diagnosis, there was no proof of metastasis in abdomen CT, lung x-ray, and even in skeletal scintigraphy.<sup>4,10</sup> The breast mass and axillary lymph nodes were detected by mammography and US after pathologic evaluation of the kidney mass. Additionally, in the literature it is proven true that HER2/Neu amplification predicts poor survival.<sup>12</sup> In this case, had HER2/Neu amplification and short survival after diagnosis of kidney metastasis of her breast cancer.

In summary, although kidney metastasis of breast cancer is rare, the diagnosis of metastatic breast cancer has increased over the last decade due to improved diagnosis techniques and technology. Physical examination is very important for diagnosis, and even subtle urinary symptoms should be evaluated carefully and detailed. Clinicians should be aware of secondaries to the kidney, and must perform thorough and regular breast examination to women every year. Furthermore, clinicians should be aware of the route of breast cancer metastasis. Hematuria, or even mild urinary symptoms in these patients should be evaluated further for metastasis.

## References

1. Shah KG, Modi PR, Rizvi J. Breast carcinoma metastasizing to the urinary bladder and retroperitoneum presenting as acute renal failure. *Indian J Urol* 2011; 27: 135-136.
2. Takehara K, Koga S, Nishikido M, Kanetake H, Hayashi T, Hara S, et al. Breast cancer metastatic to the kidney. *Anticancer Res* 1999; 19: 5571-5573.
3. Lee YT. Patterns of metastasis and natural courses of breast carcinoma. *Cancer Metastasis Rev* 1985; 4: 153-172.
4. Begara Morillas F, Silmi Moyano A, Rapariz González M, Esteban Fuertes M, Blanco González J, Chicharro Molero J, et al. [Renal metastasis from breast carcinoma: a new case and review of the literature] *Arch Esp Urol* 1995; 48: 199-203. Spanish
5. Iimura Y, Saito K, Fujii Y, Kumagai J, Kawakami S, Komai Y, et al. Development and external validation of a new outcome prediction model for patients with clear cell renal cell carcinoma treated with nephrectomy based on preoperative serum C-reactive protein and TNM classification: the TNM-C score. *J Urol* 2009; 181: 1004-1012.
6. Beaver BL, Dennig DA, Minton JP. Metastatic breast carcinoma of the gallbladder. *J Surg Oncol* 1986; 31: 240-242.
7. Brookes M, MacVicar D, Husband J. Metastatic carcinoma of the breast: the appearances of metastatic spread to the abdomen and pelvis as demonstrated by CT. *Br J Radiol* 2007; 80: 284-292.
8. Dieing A, Schulz CO, Schmid P, Roever AC, Lehenbauer-Dehm S, Jehn C, et al. Orbital metastases in breast cancer: report of two cases and review of the literature. *J Cancer Res Clin Oncol* 2004; 130: 745-748.
9. Choyke PL, White EM, Zeman RK, Jaffe MH, Clark LR. Renal metastases: clinicopathologic and radiologic correlation. *Radiology* 1987; 162: 359-363.
10. Aksu G, Fayda M, Sakar B, Kapran Y. Colon cancer with isolated metastasis to the kidney at the time of initial diagnosis. *Int J Gastrointest Cancer* 2003; 34: 73-77.
11. Schneidau T, Stroumbakis N, Choudhury M, Eshgi M, Mallouh C. Metastatic breast cancer to the bladder. *Int Urol Nephrol* 1995; 27: 297-300.
12. Ross JS, Fletcher JA. The HER-2/neu Oncogene in Breast Cancer: Prognostic Factor, Predictive Factor, and Target for Therapy. *Oncologist* 1998; 3: 237-252.

### Related Articles

Al-Rawi H, Al-Jafari M, Mathew H. Metastatic breast cancer mimicking cholecystitis. A rare clinical presentation. *Saudi Med J* 2012; 33: 1128-1130.

Hasukic SI, Iljazovic ES, Odobasic AH, Matovic EA. A rare case of primary rectal adenocarcinoma metastatic to the breast. *Saudi Med J* 2012; 33: 1014-1017.

Al-Maghrabi J, Zekri J. Metastatic breast neuroendocrine tumor from the rectum. *Saudi Med J* 2012; 33: 676-679.