

Prevalence of carotid calcification detected on panoramic radiographs in a Saudi population from a training institute in Central Saudi Arabia

Hamad A. Alzoman, MS, DABP, Ra'ed I. Al-Sadban, M.Dent.Sci., ABOMR, Ziyad H. Al-Lahem, BDS, Abdullah N. Al-Sakaker, BDS, Yasser F. Al-Fawaz, BDS.

ABSTRACT

الأهداف: تقدير مدى انتشار تكلسات الشريان السباتي التي يمكن الكشف عنها في صور الأشعة البانورامية لدى عينة من السعوديين البالغين.

الطريقة: أجريت هذه الدراسة المقطعية في عيادات كلية طب الأسنان، جامعة الملك سعود، الرياض، المملكة العربية السعودية وذلك خلال الفترة من مارس 2008م إلى يناير 2009م. لقد تمت مراجعة ملفات العينة المكونة من 555 مريض (تزيد أعمارهم عن 30 عاماً) ممن أجري لهم فحص الأشعة البانورامية ذات الدقة والوضوح المقبولة. ومن ثم تم فحص جميع صور الأشعة من قبل 3 أطباء مدرّبين لاكتشاف التكلسات في الشريان السباتي.

النتائج: أشارت نتائج الدراسة أن من أصل 555 صورة أشعة بانورامية لوحظ وجود تكلس في الشريان السباتي لدى عينة من السعوديين البالغين في 28 صورة أشعة (5%). وقد كان منهم 21 ذكر (3.75%) و7 إناث (1.25%).

خاتمة: تؤكد نتائج هذه الدراسة أهمية الفحص الشامل لصور الأشعة البانورامية، وأن لا يكون استخدامها حصراً على أمراض الفكين والأسنان بل وأيضاً لاكتشاف العلل في الأنسجة الطرية مثل تكلس الشريان السباتي. ويساعد الاكتشاف المبكر لهذه العلل في إنقاذ حياة المريض من بعض الأمراض الخطيرة وذلك بتحويله للطبيب المختص للعلاج المبكر لمثل هذه الحالات.

Objectives: To determine the prevalence of carotid artery calcification as detected on panoramic radiographs in a Saudi population.

Methods: This cross sectional study was conducted at the College of Dentistry, King Saud University, Saudi Arabia between March 2008 and January 2009. Five hundred and fifty-five panoramic radiographs of Saudi patients aged 30 years and above was collected from the patient charts. The panoramic radiographs were examined by 3 trained and calibrated examiners to detect any carotid artery calcification.

Results: Carotid artery calcification was noted in 28 (5%) of the 555 radiographs. Among these, 21 images were obtained from men (3.75%) and 7 from women (1.25%).

Conclusions: Dentists should be aware of the techniques to detect carotid artery calcification on the widely used panoramic radiographs. Consequently, information on a life-threatening condition could be provided to the patient, and a precautionary treatment could be suggested.

Saudi Med J 2012; Vol. 33 (2): 177-181

From the Department of Periodontics and Community Dentistry (Alzoman), Department of Oral Medicine and Diagnostic Sciences (Al-Sadban), Internship Training Program (Al-Lahem, Al-Sakaker, Al-Fawaz) College of Dentistry, King Saud University, Riyadh, Kingdom of Saudi Arabia.

Received 16th October 2011. Accepted 16th December 2011.

Address correspondence and reprint request to: Dr. Hamad A. Alzoman, Department of Periodontics and Community Dentistry, College of Dentistry, PO Box 60169, Riyadh 11545, Kingdom of Saudi Arabia. Tel. +966 (1) 4676648. Fax. +966 (1) 4679017. E-mail: Halzoman@ksu.edu.sa

Cerebrovascular accidents (CVAs) or strokes are the most common cause of death and permanent disability worldwide. According to the World Health Organization (WHO) estimates in 2002, 15 million people suffer from stroke each year worldwide; among these, 5 million are left permanently disabled, and 5.5 million die from stroke.¹ Presently, stroke is the third leading cause of death in the United States and Australia.² In Saudi Arabia, Tran et al³ reported that the overall distribution of stroke types was similar to that reported in western populations.³ World Health Association estimated that 3818 patients died from stroke in Saudi Arabia in the year 2004.¹ Stroke is frequently caused by atherosclerotic lesions (atheromas) in the bifurcation of the common carotid artery.

Atherosclerotic plaques develop when fatty substances, cholesterol, platelets, cellular waste products, and calcium are deposited in the lining of the carotid artery. Stroke is increasingly becoming a major health problem in Saudi Arabia.^{3,4} Moreover, diabetes mellitus, which is a common disease in Saudi Arabia, is an associated risk factor for stroke.⁵⁻⁷ Several studies have reported the identification of calcified carotid artery atheromas (CCAAs) by using panoramic radiography. Ohba et al⁸ were able to detect CCAAs in 5% of the panoramic radiographs of a population of 80-year-old.⁸ In another study, Friedlander et al⁹ reported that CCAAs could be identified in 3.3% of the panoramic radiographs obtained from a population with a mean age of 66 years.⁹ However, to our knowledge, there is no study on the prevalence of CCAAs as detected on panoramic radiographs in a Saudi population. The purpose of this study was to determine the prevalence of CCAAs as detected on panoramic radiographs in a Saudi population.

Methods. This study was conducted at the College of Dentistry, King Saud University, Saudi Arabia between March 2008 and January 2009. Ethical approval was obtained from the Ethical Committee of the College of Dentistry Research Center. A sample set of panoramic radiographs was collected from patients' charts. All the panoramic radiographs included in this study were obtained from Saudi patients aged 30 years and above. Panoramic radiographs were excluded if they had any of the following characteristics 1) incorrect patient positioning (excessive horizontal or vertical magnification in the anterior teeth, unequal ramus width bilaterally, superimposition of the cervical spine over the ramus). 2) Poor image quality (overexposed or underexposed). 3) If the radiograph did not include the upper neck region superior to the fourth cervical vertebra.

A total of 555 radiographs were included in this study. All radiographs were taken using either the orthopantomograph-OP100 (Instrumentarium Imaging, Tuusula, Finland), the Planmeca PM2002CC (Planmeca, Helsinki, Finland), or the Siemens Orthopantomograph 10 (Siemens AG, Munich, Germany) panoramic x-ray systems with Kodak dental film (T-MAT G; Eastman Kodak, Rochester, NY) and Kodak Lanex regular intensifying screen. The exposed films were processed with a Kodak X-OMAT 2000 automatic film processor according to the manufacturer's recommendations.

The panoramic radiographs were examined for CCAAs by 3 examiners, who analyzed the images on a viewing box with a high-intensity light and looked for irregular, heterogeneous, verticolinear, or circular

radiopaque masses located just below the mandibular angle and between the third and fourth cervical vertebrae (Figure 1). Other cervical calcifications, such as calcified triticeous cartilage, hyoid bone, superior horn of the thyroid cartilage, calcified lymph nodes, phleboliths, and submandibular salivary gland sialoliths, were excluded on the basis of the previously reported recommendations for differential diagnosis of CCAA by Almog et al.²

Prior to the study, all examiners had to undergo a training program; this program included lectures, case demonstration performed by an oral and maxillofacial radiologist, and specially designed training material (American Academy of Oral and Maxillofacial Radiology Training Packet for Identification of Carotid Artery Calcifications on Panoramic Radiographs).¹⁰ Inter- and intra-examiner reliability tests were performed; 2 calibration tests were conducted one week apart. The results of the calibration tests revealed a significant correlation of intra-observer reliability (Spearman-Brown coefficient = 0.85) and inter-observer reliability (Pearson correlation coefficient = 0.74). The panoramic radiographs were equally distributed into 3 groups, and the radiographs in each group were examined by an examiner. The right and left sides of each radiograph were examined for the presence or absence of unilateral or bilateral calcifications in the area of the carotid artery. Additionally, patient age and gender were recorded.

Results. Out of the 555 radiographs examined, 434 (78%) radiographs were of men and 121 (22%) were of women. The age range of the patients was 30-80 years (mean age of 46 years). Calcified carotid artery atheromas were observed on 28 panoramic radiographs (5%). Calcified carotid artery atheromas appeared as an irregular, heterogeneous or verticolinear radiopacity inferior to the angle of mandible and adjacent to the third and fourth cervical vertebrae (Figure 2).

Eighteen of these CCAAs (60%) were detected on the left side, while 12 (40%) were detected on the right side. Bilateral CCAAs were seen in 2 radiographs. Calcified carotid artery atheromas were seen in 21 images obtained from men (3.75%) and 7 images from women (1.25%). The percentage of detected CCAAs was similar in all age groups (ranged from 1.1-1.4%). The distribution of CCAAs according to patient age was summarized in Table 1.

Discussion. Carotid artery calcification, especially calcification near the carotid bifurcation, can cause significant vascular occlusion and lead to stroke. Since the first report on the detection of carotid artery calcifications by using panoramic radiography,¹¹ a

number of articles have described these findings on panoramic radiographs with prevalence ranged from 3-15% in different patient populations.¹²⁻¹⁵ The prevalence of CCAAs detected in the present study fall within this range. Bayer et al¹⁶ reported the presence of CCAAs in the panoramic radiographs of 4.8% of 2,557 patients older than 30 years of age. In their study, there

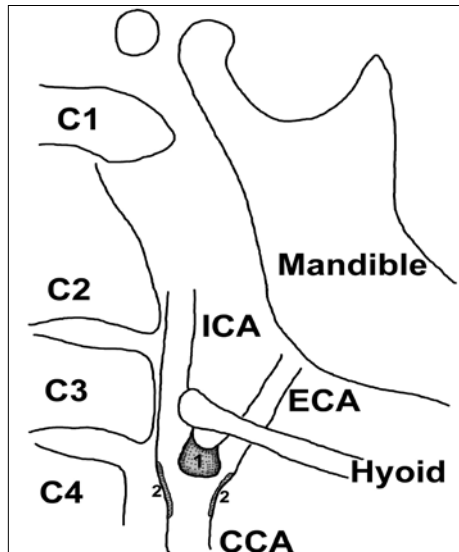


Figure 1 - A drawing depicting calcified carotid artery atheromas (CCAAs) on panoramic radiograph as a circular (1) or verticilinear (2) radiopaque in the bifurcation region of the common carotid artery (CCA) as it divides in the neck into the internal carotid artery (ICA) and the external carotid artery (ECA) just below the mandibular angle and between the third and fourth cervical vertebrae.

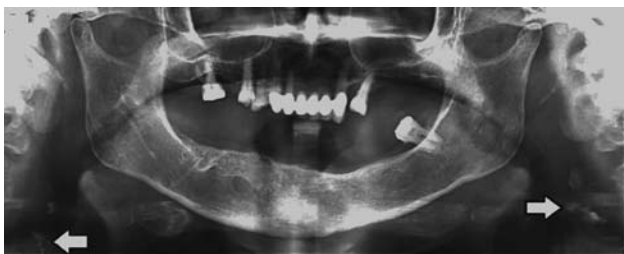

Figure 2 - Panoramic image showing multiple irregular radiopacities of the calcified carotid artery atheromas (arrows) on both right and the left side.

Table 1 - Distribution of calcified carotid artery atheromas according to age group (N=555).

Age group	Absent	Present	Total
30-40	185 (33.3)	8 (1.4)	193 (34.8)
40-50	146 (26.3)	6 (1.1)	152 (27.4)
50-60	98 (17.7)	7 (1.3)	105 (18.9)
>60	98 (17.7)	7 (1.3)	105 (18.9)
Total	527 (95.0)	28 (5.0)	555 (100.0)

was no selection carried out by gender or cardiovascular risk factors to recruit higher number of patients. Also, in another study, Madden et al¹⁷ reported the prevalence of CCAAs on patients aged ≥ 30 years. Similarly, the present study aimed to report the prevalence in a population of middle-aged and older subjects. In another study, Friedlander and Lande¹⁸ detected CCAAs in 37% of the panoramic radiographs obtained from 19 white men who had been hospitalized because of a recent cerebrovascular accident. Additionally, Friedlander et al¹⁹ reported the presence of CCAAs on panoramic radiographs obtained from 54 obstructive sleep apnea patients with an average age of 63.1 years. They found that 22.2% of the patients with obstructive sleep apnea also had CCAAs. In contrast, only 3.7% of the control patients had CCAAs. In general, in the studies conducted by Friedlander et al,^{11,18,19} 2-4.7% of asymptomatic patients showed CCAAs on panoramic radiographs. Ohba et al⁸ evaluated 659 panoramic radiographs from 80-year-old Japanese subjects. They found that 33 (5%) subjects had positive findings in their panoramic radiographs showing CCAAs. In these 33 patients (8 men and 25 women) the prevalence of CCAAs in women was higher than that in men. This high prevalence in women could be explained by the fact that the number of female subjects in their study was higher (262 men and 397 women). On the contrary, the patient population in the present study included more men (n=434) than women (n=121), and this might explain the higher prevalence of CCAAs in men in this study. The reason for the predominance of images from men in our sample could be that the study sample was drawn from the files of the male dentistry students in the dental school. Pornprasertsuk-Damrongsri et al¹² found 34 (2.5%) images showing CCAAs from 1,370 images obtained from Thai subjects aged 50 years and above. They found 16 men and 18 women, with a mean age of 69 years. They had one or more CCAAs. These calcifications were unilateral in 25 (73.5%) and bilateral in 9 (26.5%) subjects. In the present study, the presence of CCAAs could not be correlated to the medical status of the patients possibly because of the lack of proper medical history documentation in most of the patient charts. The percentage of detection of CCAAs in this study was slightly higher than that in the study by Friedlander et al.⁹ The main reason for this difference could be the difference in the age ranges of the subjects. The lower right corner of the panoramic film was usually utilized to record the patient's personal data and date of examination over the radiographic image. Therefore, more CCAAs were detected on the left side than the right side, which could be obscured by

the image identification markings. The most frequently used diagnostic investigations to identify CCAA are Doppler ultrasound, computed tomography (CT), and magnetic resonance angiography (MRA)²¹ Several studies have evaluated the precision of the panoramic radiographs in detecting CCAAs as compared to the gold standard test, namely, Doppler ultrasound.^{15,22-25} Ravon et al,²² detected 32 CCAAs on a sample of 83 panoramic radiographs. Ninety percent of these incidences were confirmed by Doppler ultrasound.²³ Furthermore, Ertas et al²⁴ tested the diagnostic reliability of panoramic radiographs in detection of CCAAs by comparing them with Doppler ultrasound. They have reported the sensitivity (79.8%), specificity (81.1%), and accuracy rates (80.5%) of panoramic radiographs in detection of CCAAs. Doppler ultrasound and CT are considered as the most prescribed investigations for identifying CCAAs precisely. However, the wide utilization of panoramic radiographs in dentistry advocates the importance of using this radiograph as an early detection tool to diagnose of calcified carotid artery atheromas.

In conclusion, the results of this study indicate the importance of meticulous examination of panoramic radiographs. Dentists should be aware of the techniques to detect carotid artery calcifications on routine panoramic radiographs. Consequently, information on a life-threatening condition could be provided to the patient, and a precautionary treatment could be suggested. Advanced diagnostic examinations such as ultrasonography, MRI, CT, and angiography should be recommended to confirm carotid stenosis in cases where CCAAs are accidentally detected in panoramic radiographs. Further research should be conducted on the relationship between CCAAs detected on panoramic radiographs of Saudi dental patients and the overall medical status. Furthermore, analysis of the correlation between CCAAs detected on panoramic radiographs and the carotid Doppler ultrasound findings for these subjects is also recommended.

References

- McKay J, World Health Organization, Mensah GA, Mendis S, Greenlund Kurt. The atlas of heart disease and stroke ([2004]). Geneva: World Health Organization; 2004.
- Almog DM, Tsimidis K, Moss ME, Gottlieb RH, Carter LC. Evaluation of a training program for detection of carotid artery calcifications on panoramic radiographs. *Oral Surg Oral Med Oral Pathol Oral Radiol Endod* 2000; 90: 111-117.
- Tran J, Mirzaei M, Anderson L, Leeder SR. The epidemiology of stroke in the Middle East and North Africa. *J Neurol Sci* 2010; 295: 38-40.
- Al Rajeh S, Awada A. Stroke in Saudi Arabia. *Cerebrovasc Dis* 2002; 13: 3-8.
- Al-Herbish AS, El-Mouzan MI, Al-Salloum AA, Al-Qurachi MM, Al-Omar AA. Prevalence of type 1 diabetes mellitus in Saudi Arabian children and adolescents. *Saudi Med J* 2008; 29: 1285-1288.
- Benamer HT, Grosset D. Stroke in Arab countries: a systematic literature review. *J Neurol Sci* 2009; 284: 18-23.
- Elhadd TA, Al-Amoudi AA, Alzaharani AS. Epidemiology, clinical and complications profile of diabetes in Saudi Arabia: a review. *Ann Saudi Med* 2007; 27: 241-50
- Ohba T, Takata Y, Ansai T, Morimoto Y, Tanaka T, Kito S, et al. Evaluation of calcified carotid artery atheromas detected by panoramic radiograph among 80-year-olds. *Oral Surg Oral Med Oral Pathol Oral Radiol Endod* 2003; 96: 647-50.
- Friedlander AH, Cohen SN. Panoramic radiographic atheromas portend adverse vascular events. *Oral Surg Oral Med Oral Pathol Oral Radiol Endod* 2007; 103: 830-835.
- Carter L. Panoramic radiography. Continuing education video on panoramic radiography, and differential diagnosis of soft tissue calcification. Proceedings of the American Academy of Oral and Maxillofacial Radiology. USA: American Academy of Oral and maxillofacial Radiology; 2000.
- Friedlander AH, Lande A. Panoramic radiographic identification of carotid arterial plaques. *Oral Surg Oral Med Oral Pathol* 1981; 52: 102-104.
- Pornprasertsuk-Damrongsri S, Thanakun S. Carotid artery calcification detected on panoramic radiographs in a group of Thai population. *Oral Surg Oral Med Oral Pathol Oral Radiol Endod* 2006; 101: 110-115.
- Sisman Y, Ertas ET, Gokce C, Menku A, Ulker M, Akgunlu F. The Prevalence of Carotid Artery Calcification on the Panoramic Radiographs in Cappadocia Region Population. *Eur J Dent* 2007; 1: 132-138.
- Johansson EP, Ahlqvist J, Garoff M, Karp K, Jaghagen EL, Wester P. Ultrasound screening for asymptomatic carotid stenosis in subjects with calcifications in the area of the carotid arteries on panoramic radiographs: a cross-sectional study. *BMC Cardiovasc Disord* 2011; 11: 44.
- Almog DM, Horev T, Illig KA, Green RM, Carter LC. Correlating carotid artery stenosis detected by panoramic radiography with clinically relevant carotid artery stenosis determined by duplex ultrasound. *Oral Surg Oral Med Oral Pathol Oral Radiol Endod* 2002; 94: 768-773.
- Bayer S, Helfgen EH, Bos C, Kraus D, Enkling N, Mues S. Prevalence of findings compatible with carotid artery calcifications on dental panoramic radiographs. *Clin Oral Investig* 2011; 15: 563-569.
- Madden RP, Hodges JS, Salmen CW, Rindal DB, Tunio J, Michalowicz BS, et al. Utility of panoramic radiographs in detecting cervical calcified carotid atheroma. *Oral Surg Oral Med Oral Pathol Oral Radiol Endod* 2007; 103: 543-548.
- Friedlander AH, Manesh F, Wasterlain CG. Prevalence of detectable carotid artery calcifications on panoramic radiographs of recent stroke victims. *Oral Surg Oral Med Oral Pathol* 1994; 77: 669-673.
- Friedlander AH, Friedlander IK, Yueh R, Littner MR. The prevalence of carotid atheromas seen on panoramic radiographs of patients with obstructive sleep apnea and their relation to risk factors for atherosclerosis. *J Oral Maxillofac Surg* 1999; 57: 516-521.

20. Krishnaswamy A, Klein JP, Kapadia SR. Clinical cerebrovascular anatomy. *Catheter Cardiovasc Interv* 2010; 75: 530-539.
21. Hoke M, Schmidt B, Schillinger T, Kluger W, Wiesbauer F, Mlekusch W, et al. Evidence of carotid atherosclerosis in orthopantomograms and the risk for future cardiovascular events. *Vasa* 2010; 39: 298-304.
22. Ravon NA, Hollender LG, McDonald V, Persson GR. Signs of carotid calcification from dental panoramic radiographs are in agreement with Doppler sonography results. *J Clin Periodontol* 2003; 30: 1084-1090.
23. Friedlander AH, Garrett NR, Chin EE, Baker JD. Ultrasonographic confirmation of carotid artery atheromas diagnosed via panoramic radiography. *J Am Dent Assoc* 2005; 136: 635-640.
24. Ertas ET, Sisman Y. Detection of incidental carotid artery calcifications during dental examinations: panoramic radiography as an important aid in dentistry. *Oral Surg Oral Med Oral Pathol Oral Radiol Endod* 2011; 112: e11-e17.

Copyright

Whenever a manuscript contains material (tables, figures, etc.) which is protected by copyright (previously published), it is the obligation of the author to obtain written permission from the holder of the copyright (usually the publisher) to reproduce the material in Saudi Medical Journal. This also applies if the material is the authors own work. Please submit copies of the material from the source in which it was first published.