

Management of appendiceal abscess

A 10-year experience in Central Saudi Arabia

Muhammad I. Hussain, FCPS (Pak), MRCS (UK), Mohammed H. Al-Akeely, MBBS, CABS, Mohammed K. Alam, MS, FRCSEd, Hamad H. Al-Qabatani, MBBS, FRCSI, Saleh M. Al-Salamah, MBBS, FRCSI, Otham A. Al-Ghamdi, MD.

ABSTRACT

الأهداف: مقارنة نتائج المرضى الذين يعانون من مرض خراج الزائدة الدودية ما بعد التدخل الجراحي الآني والعلاج الغير جراحي من خلال المضاعفات وفترة الإقامة في المستشفى.

الطريقة: أجريت هذه الدراسة الاسترجاعية في قسم الجراحة، مدينة الملك سعود الطبية، الرياض، المملكة العربية السعودية خلال الفترة ما بين يوليو 2002م حتى شهر يونيو 2011م. وتمت مراجعة السجل الطبي للمرضى الذين تم معالجتهم من الخراج الناتج من التهاب الزائدة الدودية حيث تم تقسيم المرضى إلى مجموعتين هما: المجموعة الأولى التي تم معالجتهم من خلال قسرة التصريف بواسطة التصوير الطبقي المحوري مع استخدام المضادات الحيوية الوريدية (مجموعة المعالجة الغير جراحية)، والمجموعة الثانية التي تم معالجتها عن طريق التدخل الجراحي الآني. وقد أجريت هذه الدراسة وفقاً للمتغيرات الديموغرافية، ودرجة حرارة المريض عند دخوله المستشفى، وعدد كريات الدم البيضاء، والمضاعفات، ومعدل تكرار الخراج، وفترة الإقامة بالمستشفى.

النتائج: بلغ عدد المرضى الذين يعانون من مرض خراج الزائدة الدودية 80 مريضاً خلال فترة الدراسة. وقد تمت معالجة 42 مريض (52.5%) عن طريق المعالجة الغير الجراحية، بينما خضع 38 مريض (47.5%) لعمليات جراحية آنية. وكان معدل المضاعفات أعلى بشكل ملحوظ في مجموعة المعالجة الجراحية إذا ما قورنت بمجموعة المعالجة الغير جراحية (44.7% مقابل 11.9%) ($p=0.0012$). وبلغت نسبة النجاح في مجموعة المعالجة الغير جراحية 92.8%. وتم تسجيل فرق ملحوظ في معدل فترة الإقامة بالمستشفى لمرضى المعالجة الغير جراحية 8.54 ± 2.25 مقارنة بمرضى المعالجة الجراحية 10.86 ± 4.32 ($p=0.003$).

خاتمة: أثبتت هذه الدراسة بأن معالجة مرض خراج الزائدة الدودية الغير جراحي أفضل من المعالجة الجراحية لأن الأولى تعتبر معالجة آمنة، وفعالة، وتكون مصحوبة بمضاعفات أقل، كما أن معدل المضاعفات وفترة الإقامة بالمستشفى أقصر إذا ما قورنت بالثانية.

Objectives: To study the outcome of patients with appendiceal abscess (AA) following immediate operative and non-operative management in terms of complications and hospital stay.

Methods: Medical records of all adult patients treated for AA between July 2002 and June 2011 in the Department of Surgery, King Saud Medical City, Riyadh, Kingdom of Saudi Arabia were reviewed. We identified 2 main groups of patients with the diagnosis of AA. The first group of patients were managed by CT-guided percutaneous drainage and parenteral antibiotics (non-operative management [NOM group]). The second group were patients who underwent surgical intervention (operative management [OM]). The outcome was determined in terms of complications, recurrence rate, and hospital stay.

Results: Eighty AA patients were managed during the study period. Forty-two patients (52.5%) received NOM, while 38 patients (47.5%) underwent immediate OM. The complication rate was significantly higher in the OM group compared with the NOM group (44.7% versus 11.9%; $p=0.0012$). Successful NOM was achieved in 92.8% of patients. The overall mean hospital stay of the NOM group was 8.54 ± 2.25 , and the OM group was 10.86 ± 4.32 days ($p=0.003$).

Conclusion: Non-operative management is associated with significantly lower complication rate and shorter hospital stay than OM.

Saudi Med J 2012; Vol. 33 (7): 745-749

From the Department of Surgery (Hussain), College of Medicine, Taibah University, Al-Madina Al-Munawarah, Department of Surgery (Al-Akeely, Alam, Al-Qabatani, Al-Salamah), King Saud University and the Department of Radiology (Al-Ghamdi), King Saud Medical City, Riyadh, Kingdom of Saudi Arabia.

Received 30th April 2012. Accepted 23rd June 2012.

Address correspondence and reprint request to: Dr. Muhammad I. Hussain, Department of Surgery, College of Medicine, Taibah University, PO Box 30107, Al-Madina Al-Munawarah 41477, Kingdom of Saudi Arabia. Tel. +966 536718069. E-mail: ibnarne@yahoo.com

Early appendectomy is the gold standard management for acute appendicitis since more than a century, but for appendicitis complicated by perforation and abscess formation the optimal treatment is still controversial.¹⁻⁵ Traditionally, these patients were managed by immediate surgical drainage with or without appendectomy, eliminating the risk of recurrent appendicitis. However, it is associated with risk of more extensive surgery, operative injuries, postoperative wound infection, and extended paralytic ileus.^{6,7} With the advancement in interventional radiology, there is a growing trend of non-operative management (NOM) of appendiceal abscess (AA), which includes CT-guided drainage along with broad spectrum parenteral antibiotics. This approach has become well established because of its proven safety and efficacy.⁸⁻¹³ Moreover, it avoids the risks of general anesthesia, reduces the hospital stay, and cost of medical care. However, this management policy needs the availability of interventional radiologist, and a well-equipped radiological suite and close collaboration between the general surgery and radiology departments. Over the years, with gaining experience, and developing more confidence on interventional radiology, an increasing trend of NOM has been observed in our institution as well. Most patients with AA are now being managed by this approach. The objective of the study was to study the outcome of patients with AA, following immediate operative management (OM), and NOM in terms of complications and hospital stay.

Methods. This is a retrospective study of all adult patients, who were treated for AA in the Department of Surgery, King Saud Medical City, Riyadh, Kingdom of Saudi Arabia from July 2002 to June 2011. We included all consecutive adult patients with the final diagnosis of AA, necessitating either CT-guided drainage or open drainage in this study. Patients with appendiceal mass or small abscess less than 3 cm were managed by conservative means without drainage. Patients with generalized peritonitis required an emergency exploratory laparotomy. Patients of pediatric age group (<13 years) were also excluded from the study. Diagnosis of AA was based on the CT scan findings or review of operative notes, describing localized collection of pus without the evidence of generalized peritonitis. Medical

records of all patients were reviewed retrospectively after the approval of the research and ethical committee of our hospital.

In our department guidelines, patients with suspected appendicitis undergo emergency appendectomy based on clinical and laboratory findings. A CT scan is generally requested for those patients who have uncertain diagnosis, long history of pain, or presence of mass in the right lower quadrant of the abdomen. If the CT findings are suggestive of AA, without evidence of generalized peritonitis, initial NOM approach, which includes CT-guided percutaneous drainage of abscess and parenteral antibiotics is adopted, provided CT-guided aspiration is technically possible. All multi loculated, deeply seated, or inter loop abscesses, which are difficult to approach by CT-guided percutaneous drainage, are managed by immediate open surgery (OM).

We identified 2 groups of patients with diagnosis of AA. The first, who had the diagnosis based on the CT scan findings, and were managed by CT-guided drainage, and parenteral antibiotics (NOM group). The second group included all those patients who failed to respond to NOM within 72 hours of admission, or who were not suitable for CT-guided drainage because of difficult percutaneous access, or primarily operated for appendectomy and found to have AA intraoperatively, underwent surgical drainage, and appendectomy if technically feasible and safe during the initial surgery (OM group). Informed written consent was obtained from the patients of both groups.

Patients of both groups received varied combination of broad spectrum parenteral antibiotics for 5 days. They were kept *nil per oral* for the initial few days, monitored for improvement in subjective complaints, fever, abdominal tenderness, and white blood cell count (WBC). They were discharged when they became afebrile, pain free, and tolerating normal diet. Follow up CT scans were usually not requested unless clinically indicated. Failure of NOM was defined as worsening of the patient's symptoms and signs within 72 hours after the start of therapy. Recurrence was defined as episode of abdominal pain associated with other clinical evidence of appendicitis occurring after being discharged from hospital. All patients were scheduled for follow up in the outpatient department bi-weekly for the first 3 months and 3 monthly thereafter for the appearance of recurrent symptoms of appendicitis in NOM group and for wound evaluation in the OM group. Interval appendectomy was offered in patients with recurrent appendicitis. Data regarding the demography, admission temperature, WBC, hospital course, techniques of drainage, reasons for open drainage, complications, and follow up were

Disclosure. Authors have no conflict of interests, and the work was not supported or funded by any drug company.

documented. Outcome variables like hospital stay, complications, failure of non-operative therapy, and recurrence rate was retrospectively reviewed. Length of hospital stay in NOM group included second admission for interval appendectomy when it was performed.

The data were analyzed by using Statistical Package for Social Sciences software version 13 (SPSS®, Inc; Chicago, IL, USA). The comparison of means and 95% confidence interval were calculated by student t-test. Categorical data analysis (complication rate of both groups) was performed by Fisher's Exact Test. Kaplan-Meier survival analysis was plotted to calculate the accumulated risk of recurrence in NOM group. The probability value of <0.05 was considered as statistically significant.

Results. Between July 2002 to June 2011, 80 patients with AA were managed during the study period. Forty-two patients (52.5%) were managed by CT-guided percutaneous drainage and broad spectrum parenteral antibiotics (NOM group) and 38 patients (47.5%) underwent open surgical drainage (OM group). Appendectomy was performed in 28 (74%) out of 38 patients in OM group during the initial surgery. Most of our patients (42%) in OM group underwent surgical drainage because of difficult access for CT-guided percutaneous drainage or non-availability of interventional radiologist (34%). Uncertain diagnosis was attributed in 24% of patients in this group.

Patients of both groups were comparable regarding demography, duration of symptoms, admission temperature, and WBC (Table 1). The complication rate was significantly higher in the OM group as compared to the NOM group (44.7% versus 11.9%, $p=0.0012$). In the OM group, 7 patients (18.4%) developed surgical site infection. Two of them (5.3%) had fascial dehiscence, managed conservatively, and ultimately both developed incisional hernia (5.3%). Two patients

(5.3%) suffered from prolonged ileus and improved on conservative management. Three patients (7.9%) developed recurrent abscesses; 2 of them settled down by parenteral antibiotics; the third required CT-guided percutaneous drainage. One patient (2.6%) developed fecal fistula on the fourth postoperative day, which healed spontaneously without any surgical intervention. Failure of the NOM was observed in 3 patients (7.2%). One of them developed features of generalized peritonitis. The other 2 were operated because of failure in clinical improvement. Two patients (4.7%) had residual collections on follow up ultrasound; one was managed by repositioning of the initially inserted drainage catheter and the other required placement of a second drainage catheter.

The mean follow up of patients in OM and NOM group was 14.44 ± 6.57 and 17.73 ± 6.28 months ($p=0.02$). Five patients (11.9%) of the NOM group developed recurrent appendicitis after a mean interval of 3.6

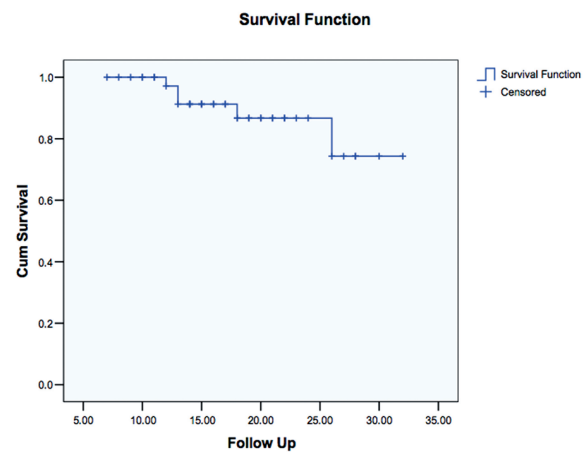


Figure 1 - Kaplan-Meier survival analysis. The median follow up time was 17 months.

Table 1 - Comparison between operative and non operative management groups.

Variables	NOM group	OM group	95% CI	P-value
Number of patients	42	38		
Male to female ratio	24:18	21:17		
Mean age (years)	31.50±15.47	31.60±13.30	-6.35 to 6.55	0.97
Mean duration of symptoms (days)	5.78±2.03	6.15±2.28	-0.58 to 1.32	0.44
Mean admission temperature (degree celsius)	38.28±0.47	38.20±0.49	-0.30 to 0.14	0.47
Mean admission white cell count (10 ⁹ /l)	17.50±3.73	17.19±3.57	-1.93 to 1.31	0.70
Mean hospital stay (days)	8.54±2.25	10.86±4.32	0.81 to 3.83	0.003
Mean follow up (months)	17.73±6.28	14.44±6.57	-6.15 to -0.42	0.02

OM - operative management, NOM - Non operative management, 95% CI - 95% Confidence interval

months and managed by interval appendectomy. One of these patients had iatrogenic perforation of terminal ileum during appendectomy, which was repaired primarily, and patient recovered well postoperatively. Kaplan-Meier survival analysis was plotted to calculate the accumulative risk of recurrence in the NOM group (Figure 1). One patient of the NOM group discovered to have adenocarcinoma cecum during follow up colonoscopy and barium enema and underwent elective right hemicolectomy. The overall mean hospital stay of the NOM group was 8.54 ± 2.25 and the OM group was 10.86 ± 4.32 days ($p=0.003$).

Discussion. Acute appendicitis is complicated by perforation and abscess formation in 2-14.2% of the patients.^{2,14} Delayed presentation to medical facility, age extremes and the hidden locations of appendix are the likely risk factors for perforation and abscess formation.¹² The wide availability of CT scan in emergency setting have helped the surgeons in establishing the diagnosis of acute appendicitis, complicated by perforation and abscess formation with great accuracy, and formulating the appropriate management plan.^{15,16}

In the absence of randomized controlled trial of adequate sample size, conflicting evidence exists regarding the optimum treatment of AA.⁵ The available options are immediate open drainage of AA with or without appendectomy or initial NOM, followed by selective or routine interval appendectomy.^{2,6} Some authors claimed the safety and efficacy of immediate surgery and stated that early surgery reduced the hospital stay, and eliminated the risk of recurrent appendicitis.¹⁷ Therefore, frequent follow ups, further investigations, and the need of another admission could be avoided. On the other hand, this approach has been associated with risk of more extensive surgery, such as ileocecal resection, temporary ileostomy, increased risk of operative injuries, hemorrhage, postoperative wound infection, paralytic ileus, and adhesions.^{1,2,6,7,18}

We encountered a complication rate of 44.7% in our OM group, and most of these complications (29%) were wound related. This is in consistent with other published studies.^{1,6,8} Brown et al⁶ and Oliak et al¹ reported an overall morbidity of 67% and 36% in their operative groups. These figures challenge the safety of immediate surgery in the presence of severely inflamed operative field. Interventional radiology has provided the clinicians with the alternative approach of percutaneous drainage of AA. Under antibiotics coverage, CT-guided percutaneous drainage offers all the benefits of minimally invasive approach.^{2,3,8,10} Moreover, it avoids the risk of general anesthesia, reduces hospital stay and cost

of treatment. The safety and efficacy of percutaneous drainage under image guidance have been proven well in published literature.^{1-6,8-10,12} We managed more than half of our patients with NOM, with a success rate of approximately 92% and there was no procedure related morbidity. Marin et al¹⁰ suggested that a large poorly defined AA and an extra luminal appendicolith on pre procedure CT image were independent predictors of clinical failure of this technique. Free appendicolith in peritoneal cavity may act as a nidus for continuous infection and recurrent abscess formation.

The complication rate of conservative management ranged between 17-24%.^{1,6} We had a lower complication rate (11.9%) because of selective approach for CT-guided drainage in complex abscesses with difficult access. With growing confidence and experience, interventional radiologists in our hospital are now accepting more difficult cases for percutaneous drainage. The risk of recurrent appendicitis, missing, or delaying the diagnosis of an underlying malignancy or Crohn's disease after NOM was considered a justification for recommending routine interval appendectomy (IA).^{1,6} We had a recurrence rate of 11.9% in the NOM group with the mean follow up of approximately 17 months, which is within the reported figure of 3-25%.^{8,19-22} Most of the recent literature supports the selective approach for IA.^{8,19-22} In a review article, Corfield¹⁹ observed that at least 75-90% of routine IA in adult population was unnecessary. Furthermore, Willemsen et al²⁰ reported 30% of the patients after IA had a normal appendix at pathological evaluation. After drainage of necrotic content, the remnant of appendix could heal and the inflammation could resolve without appendectomy. We did not advise IA after the successful NOM in our patients. We believe that recurrent appendicitis is not associated with serious morbidity and can be managed by simple appendectomy. In addition, asymptomatic patients are very reluctant to go for another hospital admission and surgery. The complication related to interval appendectomy (3-23%) further support the selective approach in symptomatic patients.^{1,4,6,8,19} On the other hand, the risk of missing malignancy or Crohn's disease is unlikely without symptoms, having CT scan was carried out during first admission and close follow up. However, we recommend screening colonoscopy in patients, above 40 years old during follow up.

Study limitations. Firstly, it is a retrospective study. Secondly, is the short follow up of patients in the NOM group (mean 17.7 months). All our patients in the NOM group were followed in the first 6 months after discharge, but some were lost to follow up thereafter.

They might have developed the recurrence and presented to other medical facility that could falsely reduced the recurrence rate in our study. Recurrence was frequently observed within 2 years of the development of initial symptoms in most of the studies.^{4,20,21} Thirdly, this study was carried out in adult population only, we believe that similar results can be achieved by NOM in children as well and various studies focusing on the pediatric age group has proved its safety and efficacy.^{3,11,13}

In conclusion, NOM is relatively safe, effective, and associated with significantly lower complication rate, and shorter hospital stay. We suggest close follow up and interval appendectomy only in patients with recurrent appendicitis. This approach avoids unnecessary readmission, and possible complications associated with IA. We also suggest conducting randomized controlled trials on the subject to draw a more precise conclusion, and further evaluate the scope of laparoscopic IA.

References

- Oliak D, Yamini D, Udani VM, Lewis RJ, Arnell T, Vargas H et al. Initial non operative management for periappendiceal abscess. *Dis Colon Rectum* 2001; 44: 936-941.
- Lasson A, Lundagards J, Loren I, Nilsson PE. Appendiceal abscesses: Primary percutaneous drainage and selective interval appendectomy. *Eur J Surg* 2002; 168: 264-269.
- Simillis C, Symeonides P, Shorthouse AJ, Tekkis PP. A meta-analysis comparing conservative treatment versus acute appendectomy for complicated appendicitis (abscess or phlegmon). *Surgery* 2010; 147: 818-829.
- Kim JK, Ryoo S, Oh HK, Kim JS, Shin R, Choe EK, et al. Management of appendicitis presenting with abscess or mass. *J Korean Soc Coloproctol* 2010; 26: 413-419.
- Aranda-Narváez JM, González-Sánchez AJ, Marín-Camero N, Montiel-Casado C, López-Ruiz P, Sánchez-Pérez B, et al. Conservative approach versus urgent appendectomy in surgical management of acute appendicitis with abscess or phlegmon. *J Rev Esp Enferm Dig* 2010; 102: 648-652.
- Brown CV, Abrishami M, Muller M, Velmahos GC. Appendiceal abscess: Immediate operation or percutaneous drainage? *Am Surg* 2003; 69: 829-832.
- Gibeily GJ, Ross MN, Manning DB, Wherry DC, Kao TC. Late -presenting appendicitis: a laparoscopic approach to a complicated problem. *Surg Endosc* 2003; 17: 725-729.
- Anderson RE, Petzold MG. Non surgical treatment of appendiceal abscess or phlegmon: A systematic review and meta-analysis. *Ann Surg* 2007; 246: 741-748.
- Kumar S, Jain S. Treatment of appendiceal mass: prospective randomized clinical trial. *Indian J Gastroenterol* 2004; 23: 165-167.
- Marin D, Ho LM, Barnhart H, Neville AM, White RR, Paulson EK. Percutaneous Abscess Drainage in Patients with Perforated Acute Appendicitis: Effectiveness, Safety, and Prediction of Outcome. *AJR* 2010; 194: 422-429.
- Emam AT, Awad FM. Appendiceal Abscess Imaging-Guided Drainage in Children: Can it Replace Laparotomy? *Med J Cairo Univ* 2009; 77: 17-22. Available from URL: <http://www.medicaljournalofcairouniversity.com>
- Zerem E, Salkic N, Imamovic G, Terzic I. Comparison of therapeutic effectiveness of percutaneous drainage with antibiotics versus antibiotics alone in the treatment of periappendiceal abscess: is appendectomy always necessary after perforation of appendix? *Surg Endosc* 2007; 21: 461-466.
- Roach JP, Partrick DA, Bruny JL, Allshouse MJ, Karrer FM, Ziegler MM. Complicated appendicitis in children: a clear role for drainage and delayed appendectomy. *Am J Surg* 2007; 194: 769-772.
- Hornez E, Gellie G, Entine F, Ottomani S, Monchal T, Meusnier F, et al. Is there still a benefit to operate appendiceal abscess on board French nuclear submarines? *Mil Med* 2009; 174: 874-877.
- Birnbaum BA, Wilson SR. Appendicitis at the millennium. *Radiology* 2000; 215: 337-348.
- Hogan MJ. Appendiceal abscess drainage. *Tech Vasc Interv Radiol* 2003; 6: 205-214.
- Zarba ME, Mazzocchi P, Lepiane P, Dalsasso G, Giacobuzzo F, Salvio A et al. The role of surgery in the treatment of appendicular abscesses. *Minerva Chir* 1997; 52: 577-581.
- Thompson JE Jr, Bennion RS, Schmit PJ, Hiyama DT. Cecectomy for complicated appendicitis. *J Am Coll Surg* 1994; 179: 135-138.
- Corfield L. Interval appendectomy after appendiceal mass or abscess in adults: What is "best practice"? *Surg Today* 2007; 37: 1-4.
- Willemsen P, Hoorntje L, Eddes E, Ploeg RJ. The need of interval appendectomy after resolution of an appendiceal mass questioned. *Dig Surg* 2002; 19: 216-220.
- Kaminski A, Liu IL, Applebaum H, Lee SL, Haigh PI. Routine interval appendectomy is Not justified after initial non operative treatment of acute appendicitis. *Arch Surg* 2005; 140: 897-901.
- Sakorafas GH, Sabanis D, Lappas C, Mastoraki A, Papani Kolaou J, Siristatidis C, et al. Interval routine appendectomy following conservative treatment of acute appendicitis: Is it really needed? *World J Gastrointest Surg* 2012; 27: 83-86.