

Management of an impacted maxillary central incisor with dilacerated root

Jun-Jie Xue, BDS, MD, Nian-Song Ye, BDS, MD, Jing-Yu Li, BDS, MD, Wen-Li Lai, DDS, PhD.

ABSTRACT

إن التفتيت هو تشوه الأسنان المتميز بالتزوُّ بين التاج والجذر مما تسبب في عدم بزوغ السن، وعادة ما يحدث التفتيت بعد حدوث الأذى للأسنان اللبنية التي قممها تقع بالقرب من براعم الأسنان الدائمة. وكان القلع الجراحي مستخدماً باعتباره أول الخيار في علاج الأسنان الشديدة التفتيت. تقرير الحالة هذا يعرض الترتيب السنّي التقويمي قاطعة مركزية يمتد دائماً بالفك العلوي لمريض يبلغ من العمر 8 أعوام وكان له قاطعة مركزية مقلوبة بالفك العلوي منحسرة، مع جذر مفتت، مع تفتيت الجذر الزاوي الوحشي من حيث محور التاج. بعد التعرض الجراحية بتقنية البزوغ المغلقة والجذر التقويمي المناسب، تم ترصيف السن في القوس السنوية بنجاح، وتبين شعاعياً أن الجذر تم تقويمه وتطوره بشكل جيد نسبياً. في الختام، ينبغي أن تقام المعالجة بالاستعانة بالجر التقويمي في حالة القاطعة المفتتة المنحسرة التي تم تشخيصها في وقت مبكر للتسنين المختلط.

Dilaceration is a comparatively uncommon dental deformity generally characterized by an angulation between crown and root, and consequently causing non-eruption of the tooth. Dilaceration generally occurs following trauma to the apices of deciduous dentition, which lies close to the permanent tooth buds. As a result, surgical extraction used to be the first choice when making the treatment plan for a case with severely dilacerated teeth. This case report presents the orthodontic alignment of a permanent maxillary right central incisor in an 8-year-old boy who had an impacted inverted maxillary central incisor, with distoangular root dilaceration through the crown. Following surgical exposure with the closed-eruption technique and appropriate orthodontic traction, the tooth was successfully aligned into the dental arch and the root was radiologically shown to be straightened and relatively well developed. The impacted dilacerated incisor diagnosed in the early mixed dentition should be treated with the aid of orthodontic traction.

Saudi Med J 2013; Vol. 34 (10): 1073-1079

From the Department of Orthodontics, State Key Laboratory of Oral Diseases, West China Hospital of Stomatology, Sichuan University, Sichuan, China.

Received 9th July 2013. Accepted 25th August 2013.

Address correspondence and reprint request to: Dr. Wen-Li Lai, Department of Orthodontics, State Key Laboratory of Oral Diseases, West China Hospital of Stomatology, Sichuan University, Chengdu, Sichuan 610041, China. Tel. 86 (028) 85501442. E-mail: wenlilai@hotmail.com

Under normal circumstances, the maxillary lateral incisors are the last of the incisors to erupt, completing the anterior dentition with their appearance about a year after the eruption of the adjacent central incisors. The occurrence of erupted lateral incisors associated with the non-appearance of one or both of the central incisors should always be deemed abnormal when a child is between 8 and 10 years of age.¹ Although impaction of a permanent tooth is rarely diagnosed during the mixed dentition period, an impacted central incisor is usually diagnosed accurately when there is delay in the eruption of the tooth. However, the abnormality in the appearance can also be due to other clinical features and malformation of other elements of the craniofacial complex. Tooth impaction may result from a number of local causes. The principal local factors involved in this anomaly are supernumerary teeth, odontomas, and trauma.² Dilaceration can be a sequel of trauma and is associated with maxillary central incisor eruption failure.² Dilaceration can be mild,

Disclosure. This study was supported by the National Natural Science Foundation of China (General Program) (Grant No. 81070858), the National Natural Science Foundation of China for Young Scholars (Grant No. 81100778), and the Natural Science Foundation of Xinjiang province of China for Young Scholars (Grant No. 2011211B35).

moderate, or severe and can alter the eruptive pathway of the tooth, causing impaction.² In an extensive review, Bishara³ lists the etiologic factors of tooth impaction. Although trauma was not included as a factor, he refers to the abnormal position of the tooth bud that might be caused by trauma. Dilaceration can add significant complexity to the treatment of impacted teeth. Therefore, careful planning is required when moving an impacted tooth by orthodontic treatment. Impacted teeth can be properly positioned with orthodontic traction.⁴ However, orthodontists often hesitate to align an impacted incisor with severe dilacerations, because there are chances of failure due to ankylosis,⁵ loss of attachment, external root resorption, and root exposure after orthodontic retraction. Hence, root canal therapy (RCT) and apicoectomy would be needed during the

traction of the impacted tooth. This article presents a case of an inverted impacted maxillary right incisor with a severely distoangular dilacerated root that was aligned into proper position after orthodontic traction combined with surgical exposure and apicoectomy.

Case Report. An 8-year-old Chinese boy presented with an impacted right maxillary central incisor. The chief complaint was non-eruption of the right maxillary central incisor (Figures 1a-1e & Figures 2a-2e). The child was in good health and no history of supernumerary teeth and odontoma, but he had a history of dental trauma when he was 4 years old and he had the habit of nail biting from the age of 3. The etiology of the impacted incisor may mainly because of the trauma history, as well as the positional relationship between

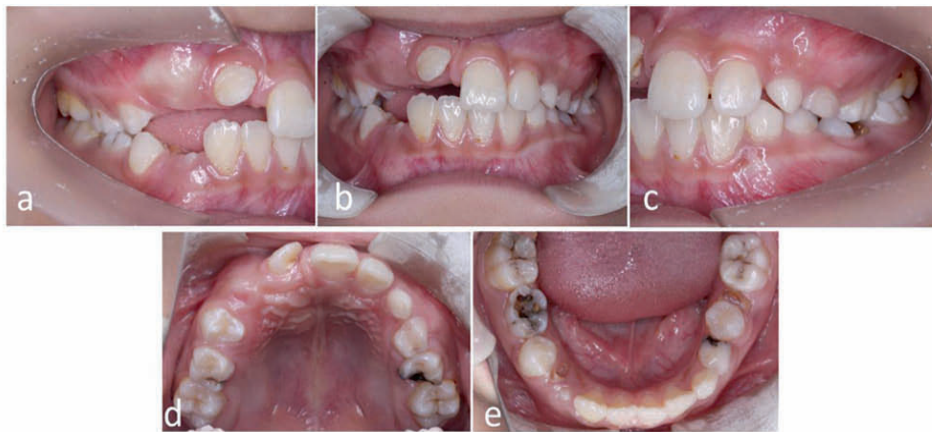


Figure 1 - Pretreatment intraoral photographs. The patient had mixed dentition, and the right maxillary central incisor had not erupted, the right maxillary lateral incisor occupied the position of the non-erupted central incisor. Three deciduous molars had caries on the occlusal surfaces.

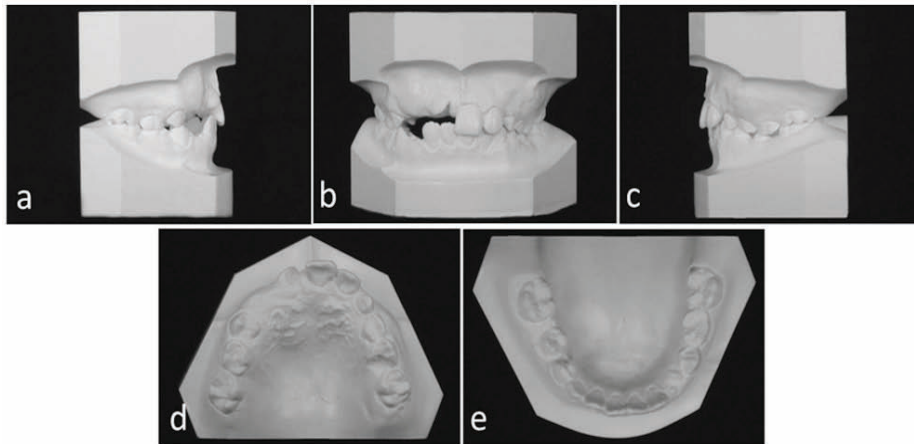


Figure 2 - Pretreatment dental casts. The patient had angle's class I relationship of the first molar for both left and right side, and deep overbite for anterior teeth.

the deciduous and permanent incisors during nail-biting, and a very specific directional relationship with the vector of the bite force, or ectopic position of the tooth bud.

The patient had a skeletal Class I malocclusion and a balanced facial pattern. Intraoral examination revealed an angle class I molar relationship with an overbite of 2 mm and an overjet of 1.5 mm. Panoramic radiograph demonstrated an impacted maxillary right central incisor (Figure 3). To locate the impacted right maxillary central incisor, we used 64-slice spiral computed tomography (CT) for this patient (Figure 4a-4f),

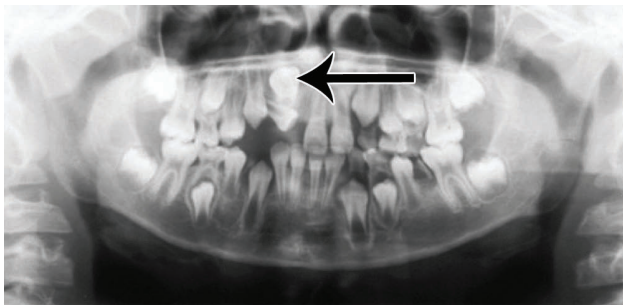


Figure 3 - The pretreatment panoramic radiographs showed that the maxillary right central incisor was impacted in an inverted position in the region of the nasal floor.

reconstructed for analysis of the relationship between the impacted central incisor and its adjacent teeth. The incisor was inverted vertically, which led to upheaval in the maxillary bone around the crown of the impacted central incisor, and apparent dilaceration with an angle of approximately 80 degrees between the apex and the root on the CT. The crown of the maxillary right lateral incisor inclined severely to the mesial side, and its root inclined to the distal side while under the maxillary right canine bud.

The following treatment objectives were established: 1) extraction of residual roots of the deciduous teeth, leveling and alignment of the erupted teeth in the maxilla; 2) recovery of space in the maxilla for the eruption of the right central incisor and canine; 3) provision of orthodontic traction for the impacted teeth; 4) creation of a stable functional occlusion; and 5) establishment of adequate attached gingiva and symmetrical gingival margins for both maxillary central incisors. Several possible treatment options were explained to the patient and his parents, including: (1) Extract the impacted central incisor, close the space, and align the lateral incisor into the place of the central incisor followed by prosthetic restoration, (2) Extraction of the impacted central incisor, creation of space by orthodontic treatment, and restoration with

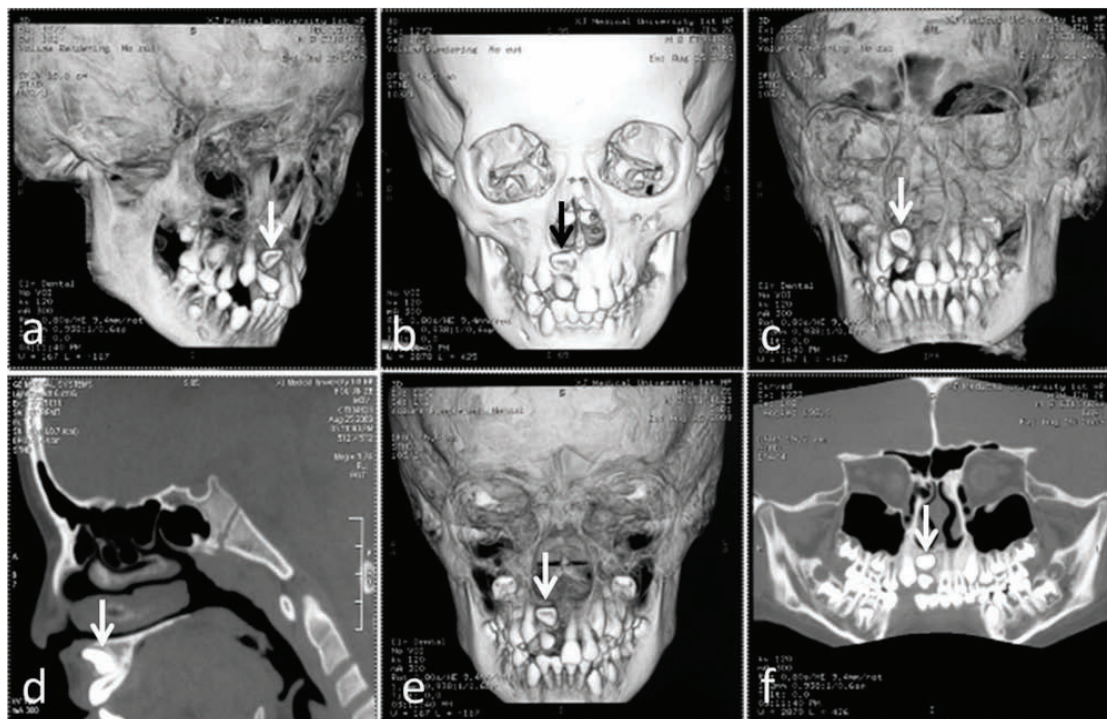


Figure 4 - Reconstruction of computed tomography for showing the exact 3-dimensional positions of the impacted central incisor and its adjacent teeth, the arrows in the figure are pointing to the impacted incisor.

a bridge or an implant in the future, when growth had ceased, and 3) Space-opening by orthodontic treatment for the impacted central incisor, surgical exposure, and traction of the impacted tooth into the proper position. After informed consent was obtained from the patient and his parents, and although it is generally considered that a severely dilacerated impacted incisor has a poor prognosis, we decided to expose the tooth and bring it into the arch by fixed orthodontic treatment, because the patient and his parents requested non-extraction treatment. The treatment plan consisted of space-opening by fixed orthodontic treatment, surgical exposure of the impacted incisor, and traction of the impacted dilacerated central incisor into proper position.

The residual roots of the deciduous teeth were extracted before orthodontic treatment, and bands were placed on the maxillary first permanent molars. The initial alignment was performed with a 0.012-inch Ni-Ti wire. After alignment and leveling, we placed an open coil spring in the position of the right central incisor on a 0.016*0.025-inch Ni-Ti square wire. By activation of the open coil spring, adequate space for

the traction of the impacted incisor was obtained. After 6 months' alignment and space expansion, 0.018*0.025 inches steel stainless wire was engaged with an open coil spring to maintain the space for the impacted central incisor. The patient was then transferred to the oral surgeon for exposure of the impacted incisor. The surgeon raised a wide mucoperiosteal flap similar to that described in the closed-eruption technique by Vermette et al.⁶ The alveolar bone layer and follicle of the labial surface were kept intact, to avoid the appliance that was used to achieve traction of the impacted incisor being covered by the mucous membrane because of wound healing. We bonded a small columnar attachment with a circular slot made by resin, instead of metal buttons, to the lingual surface of the impacted tooth during surgical exposure (Figure 5a), and made the attachment protrusion in the vestibule of the mouth. An elastic line was tied from the slot on the attachment to the arch wire for traction of the impacted incisor. Orthodontic traction of the impacted incisor was initiated with a force of approximately 50 g, which was applied by an elastic line (Figure 5b). The lingual attachment was shortened by stripping while the inverted vertical impacted crown

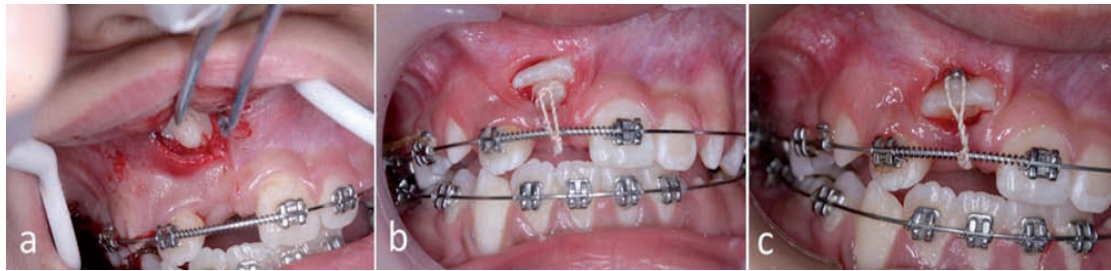

Figure 5 - Progress photographs: Surgical exposure of impacted incisor, A) a small columnar attachment bonded on the lingual surface of the impacted tooth; B) after shaping the attachment, tying the orthodontic elastic line from the slot of the attachment to the arch wire. C) a lingual button was bonded to the labial surface when the crown of the impacted incisor became vertical.

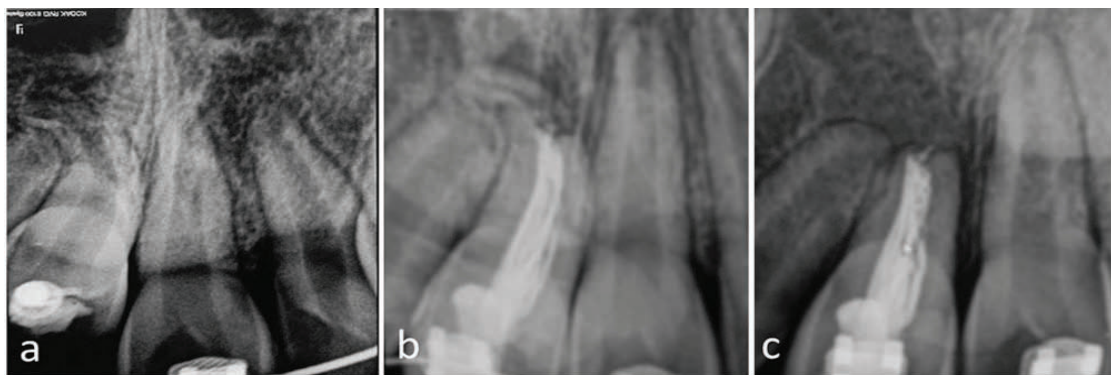


Figure 6 - Progress photographs: Disto-angular root apex of impacted incisor showing A) periapical radiograph, B) filling after root canal therapy, and C) apicoectomy of the impacted incisor after filling.

became horizontal, and a lingual button was bonded to the labial surface when the crown of the impacted incisor became vertical (Figure 5c). A bracket was bonded when the incisor reached the occlusal plane. A periapical radiograph revealed that the root apex of the impacted tooth was dilacerated on the distal side and disturbed the position of the lateral incisor (Figure 6a), and there was gingival accumulation on the lingual side of the impacted incisor that obstructed tooth movement into normal torque. Therefore, the patient was transferred to a periodontist for gingivoplasty, then to an endodontist and an oral surgeon for root canal filling and apicoectomy (Figures 6b & 6c). After 2 months, orthodontic treatment was resumed. The total duration of orthodontic treatment, including final alignment, was 24 months. The bands and brackets

were removed, and a bonding wire was attached to the upper incisors with a wrap around retainer. After 6 months of retention, the bonded wire was removed, and transparent maxillary and mandibular retainers were placed. The impacted right maxillary central incisor was successfully aligned into proper position. The repositioned incisor had an acceptable gingival contour and width of attached gingiva (Figures 7a-7e, Figures 8a-8e). The post-treatment radiograph showed no periodontal bone loss (Figure 9), but mild root resorption of the impacted incisor occurred. Bilateral Class I canine relationships, bilateral Class I molar relationship, and ideal overjet and overbite were achieved. The final radiographs indicated intact roots, proper root alignment, and no root disease. The color of the impacted incisor became gray because of the root

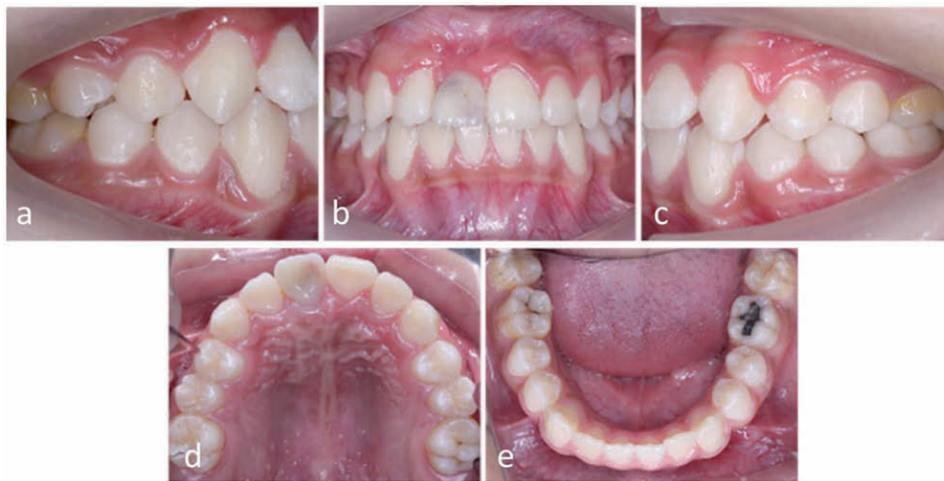

Figure 7 - Post-treatment intraoral photographs. The impacted right maxillary central incisor was successfully aligned into the proper position. The repositioned incisor had an acceptable gingival contour and width of attached gingiva.

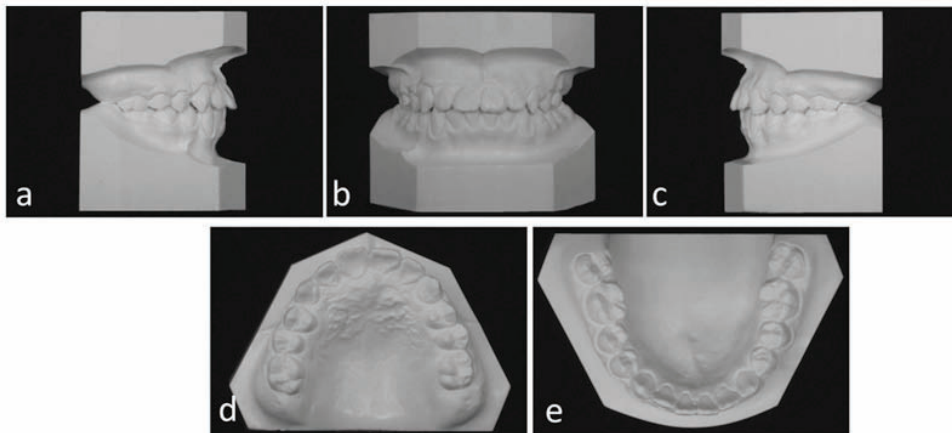


Figure 8 - Post-treatment dental casts. The impacted right maxillary central incisor was successfully aligned into the proper position. The repositioned incisor had an acceptable gingival contour and width of attached gingiva.

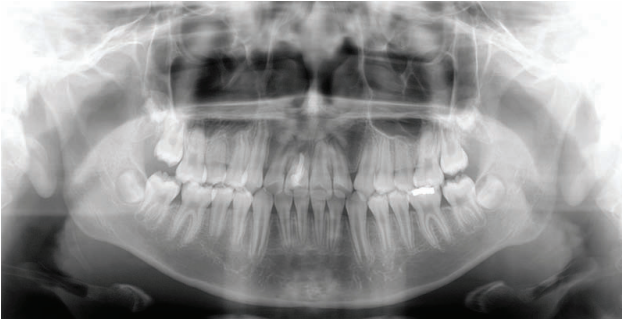

Figure 9 - Post-treatment panoramic radiograph showed no periodontal bone loss, but mild root resorption of the impacted incisor occurred.

canal filling and apicoectomy. We recommended that the patient receive a ceramic crown for the impacted tooth after the cessation of growth and development. Because of the inadequate alveolar bone around the labial side of the impacted tooth, the torque of the impacted incisor was not as normal as that of the contralateral central incisor. Telephone follow-up was carried out once a year after the treatment is accomplished. The record showed that the upper central incisor on the right side had remained in a good function, and showed no tendency of increasing mobility.

Discussion. Impacted maxillary incisors occur less frequently than impacted maxillary canines, but it causes concern to parents with children in the early mixed dentition stage of growth because of non-eruption of the anterior tooth.³ However, impaction with severely dilacerated root is seldom reported, especially for the inverted maxillary incisor, probably due to the clinical difficulty of bringing the dilacerated tooth into proper position. Traumatic injuries and obstructive causes are believed to have led to the impaction of maxillary central incisors; improper oral habits, such as nail biting and finger sucking, may also contribute to tooth impaction. The cause of incisor dilaceration has not yet been clearly established. Smith and Winter attributed the dilacerated permanent incisor to traumatic injury of the primary predecessor, leading to root dilacerations.⁷ The patient we report here had an apparent history of trauma experience, and did show dilacerated incisors. Thus, a history of trauma may be an indispensable basis for standard evaluation of dilacerated roots. Dilaceration will affect the methods of treatment and the prognosis of the impacted tooth; therefore, it is significant to ensure the root's anatomical morphology of the impacted tooth before the treatment plan is made.

In addition to panoramic radiography, CT in cases of impacted teeth is helpful for locating the exact 3-dimensional positions of these teeth, while eliminating the super-impositions inevitably seen in plane film radiography. Computerized tomography will also facilitate pinpointing the location of the initial curvature of the root of a dilacerated tooth, so that the orthodontist can decide whether a subsequent apicoectomy will be necessary. We chose CT to examine the relationship between the impacted incisor and the tissues around it. This approach will help the surgeon to decide where to open the initial flap; it will also assist us in assessing the difficulties that might be encountered in resolving the impaction and to facilitate the design of auxiliary appliances appropriate to the task.

Most orthodontists choose a metal lingual button or a bracket with a ligature wire, or titanium buttons with a chain weighted for traction of the impacted teeth.⁸ We chose to bond a small columnar attachment with a circular slot made by resin instead of metal buttons. This method managed to reduce the expulsion rate by decreasing the adhesive surface, and allowed us to shape the form of the attachment if necessary without de-bonding and re-bonding a new attachment on the same tooth surface. It can also reduce stimulation to the mucous membranes from the attachment.

Vermette et al⁶ compared 2 surgical techniques and found that the apically positioned flap technique had more esthetically negative effects, such as increased crown length and gingival scars, than the closed-eruption technique. Because the closed-eruption technique usually provides the most esthetically pleasing result, we used this surgical technique during the treatment.⁹ After the first stage of traction from the lingual side of the impacted incisor, the horizontal position of the impacted maxillary central incisor meant that direct movement of the incisor from the labial side was the only way to expose the tooth and attach the wire. This procedure has the disadvantage of producing a nonkeratinized vestibular gingival margin.¹⁰ Because of the relatively high prevalence of gingival defects in some studies, adjunctive post-orthodontic periodontal surgery might be required in many patients treated with this method, to achieve an esthetic gingival margin contour over the central incisors and provide the teeth with an adequate zone of attached gingival. In this case, the periodontal status of the exposed incisor after orthodontic treatment revealed an acceptable gingival contour. No further mucogingival surgery was recommended.

Acknowledgment. *The authors would like to acknowledge Prof. Hu Wang for his participation in taking computed tomography of the case.*

References

1. Crawford LB. Impacted maxillary central incisor in mixed dentition treatment. *Am J Orthod Dentofacial Orthop* 1997; 112: 1-7.
2. Valladares NJ, de Pinho CS, Estrela C. Orthodontic-surgical-endodontic management of unerupted maxillary central incisor with distoangular root dilaceration. *J Endod* 2010; 36: 755-759.
3. Bishara SE. Impacted maxillary canines: a review. *Am J Orthod Dentofacial Orthop* 1992; 101: 159-171.
4. Tanaka E, Watanabe M, Nagaoka K, Yamaguchi K, Tanne K. Orthodontic traction of an impacted maxillary central incisor. *J Clin Orthod* 2001; 35: 375-378.
5. Campbell KM, Casas MJ, Kenny DJ. Development of ankylosis in permanent incisors following delayed replantation and severe intrusion. *Dent Traumatol* 2007; 23: 162-166.
6. Vermette ME, Kokich VG, Kennedy DB. Uncovering labially impacted teeth: apically positioned flap and closed-eruption techniques. *Angle Orthod* 1995; 65: 23-33.
7. Smith DM, Winter GB. Root dilaceration of maxillary incisors. *Br Dent J* 1981; 150: 125-127.
8. Pinho T, Neves M, Alves C. Impacted maxillary central incisor: surgical exposure and orthodontic treatment. *Am J Orthod Dentofacial Orthop* 2011; 140: 256-265.
9. Becker A, Brin I, Ben-Bassat Y, Zilberman Y, Chaushu S. Closed-eruption surgical technique for impacted maxillary incisors: a postorthodontic periodontal evaluation. *Am J Orthod Dentofacial Orthop* 2002; 122: 9-14.
10. Chaushu S, Brin I, Ben-Bassat Y, Zilberman Y, Becker A. Periodontal status following surgical-orthodontic alignment of impacted central incisors with an open-eruption technique. *Eur J Orthod* 2003; 25: 579-584.

Illustrations, Figures, Photographs

Four copies of all figures or photographs should be included with the submitted manuscript. Figures submitted electronically should be in JPEG or TIFF format with a 300 dpi minimum resolution and in grayscale or CMYK (not RGB). Printed submissions should be on high-contrast glossy paper, and must be unmounted and untrimmed, with a preferred size between 4 x 5 inches and 5 x 7 inches (10 x 13 cm and 13 x 18 cm). The figure number, name of first author and an arrow indicating "top" should be typed on a gummed label and affixed to the back of each illustration. If arrows are used these should appear in a different color to the background color. Titles and detailed explanations belong in the legends, which should be submitted on a separate sheet, and not on the illustrations themselves. Written informed consent for publication must accompany any photograph in which the subject can be identified. Written copyright permission, from the publishers, must accompany any illustration that has been previously published. Photographs will be accepted at the discretion of the Editorial Board.