

Progeria with post-streptococcal glomerulonephritis

A rare case report with differential diagnosis

Alphy A. Sebastian, BDS, MDS, Auswaf K. Ahsan, BDS, MDS.

ABSTRACT

تعد متلازمة جيلفورد بروجيريا هاتشنيسون اعتلال جسمي مسيطر ملازم لهشاشة الجلد. يتصف بعدم تناسب قحفي وجهي، وتأخر التسنين، وصغر الفك، وظهور التقطه الطيور. كما أن العيب الوراثي الرئيسي هو طفرة جين دي نوبا في جين LMNA. يصف هذا التقرير حالة مريض يبلغ من العمر 16 عام مع ظهور أعراض جيلفورد بروجيريا هاتشنيسون والذي تم وصف الحالة في الأدبيات بشكل كبير. كما ظهرت أعراض تضخم الكبد لدى المريض. كما تم مناقشة التشخيصات المختلفة بالتفصيل في هذا المقال.

Hutchinson-Gilford progeria syndrome is a rare autosomal dominant disorder associated with skin fragility. It is characterized by craniofacial disproportion, delayed dentition, micrognathia, and plucked bird appearance. The genetic defect is mainly de nova mutation in the lamin A gene. This report describes a 16-year-old patient with classical features of progeria along with post-streptococcal glomerulonephritis. The symptoms of hepatomegaly were also present in the patient. The differential diagnoses of this lesion are also discussed in detail in this literature.

Saudi Med J 2013; Vol. 34 (2): 190-194

From the Department of Oral Medicine and Radiology (Sebastian), St. Gregorios Dental College, Kothamangalam, and the Department of Oral Medicine and Radiology (Ahsan), Kunbitharuwai Memorial Charitable Trust Dental College, Kozhikode, Kerala, India.

Received 5th September 2012. Accepted 28th October 2012.

Address correspondence and reprint request to: Dr. Alphy A. Sebastian, Department of Oral Medicine and Radiology, St. Gregorios Dental College, Kothamangalam, Kerala 686681, India. Tel. +91 (974) 4267536. Fax. +91 (485) 2572530. E-mail: alphyalphonsa1@yahoo.com

Hutchinson-Gilford progeria syndrome is a childhood disorder caused by a point mutation of the lamin A (LMNA) gene. It creates a form of the LMNA protein, which cannot be processed properly and accumulates in the cell nucleus. Lamin A protein causes early cell death, which results in premature ageing.¹ The classical features of progeria are craniofacial disproportion, wrinkled skin, pinched out nose, and horse riding stance. Renal involvement in this syndrome is quite rare. This article describes a rare case report of progeria with post-streptococcal glomerulonephritis. The patient exhibited symptoms of hepatomegaly, which is also uncommon.

Case Report. A 16-year-old boy reported with his mother for routine dental check up. Medical history revealed that he underwent cataract surgery 3 years back in a nearby hospital. His mother reported that he appeared healthy after delivery, except for sparse body hair, feeding difficulties, and small birth size. She also gave a history of tightened skin, delay in gaining weight, and also noted reduced growth when he reached one year old. Intelligence level was found normal, and also reported history of frequent fracture of both legs. He was under ayurvedic medication for arthritis, and also underwent blood transfusion at 2 years of age. He had a history of pharyngitis and oliguria, when he reported. Past dental history revealed delayed formation of deciduous and permanent teeth. There was no history of consanguineous marriage in the family. He was poorly nourished, and poorly built with wide gait. Pallor was also noted, and third degree clubbing was present.

A review of the systems revealed thinned out, wrinkled skin with loss of elasticity, and thin limbs with prominent knee joints were also present. Movements of the limbs were restricted with low muscular tonicity. The dilated veins were seen over the chest, and the chest circumference was well below normal (56 cm). Endocrine system revealed inadequate sexual

maturation. Liver was palpable 2.5 cm below the right costal margin, tender and soft with round borders. Extra oral examination revealed the characteristic frontal and parietal bossing, prominent eyes, protruding ears with hypoplastic lobules, pinched out nose, midface hypoplasia, hyperplastic scars on the left forehead region, hypopigmented lip, sparse eyelashes, and eyebrows and prominent chin (Figure 1). Intraoral findings revealed hypodontia with features of chronic periodontitis (Figure 2), ogival palate, generalized pallor of oral mucosa, and bilateral occurrence of angular cheilitis (Figure 3). On physical examination, short clavicle, hands, and feet were noticed (Figure 4 and Figure 5).

An abdomino-pelvic ultrasound showed slightly large kidneys with type 1 nephropathy and mild hepatomegaly. Renal biopsy revealed manifestations of diffuse proliferative glomerulonephritis in both kidneys. The x-ray findings of the extremities showed osteoporotic changes with calcification around the knee joint, distal phalanges showed osteolysis, and tufting, coxa valga, and pathological fracture of the lower extremities. An orthopantomogram revealed both condylar processes positioned inferiorly and posteriorly resulting in inferior-posterior bowing of the mandible, enlarged appearance of permanent teeth in proportion to the jaw bone, thin basal bone height with the developing root apices near the inferior cortical border, pronounced curvature of the maxilla, and overlapping of the posterior maxillary border by the distally tilted permanent maxillary molar. Generalized bone loss was seen extending up to the apical one-third, suggestive of generalized chronic periodontitis (Figure 6). True lateral radiograph revealed an absence of sphenoid sinus, hypoplastic maxillary sinus, and mid facial hypoplasia (Figure 7). Table 1 shows the results of the laboratory tests of the patient.

Cephalometric analysis showed steep mandibular plane angle, obtuse gonial angle, and lack of development of pogonion, which resulted in a retrognathic facial appearance. Smaller mandibular body length (Gonion-Gnathion) with respect to age, presence of hypoplastic mandible, shorter ramus than mandibular body, marked retardation of jaw bone as evidenced by the lack of anterior-posterior development, and increased vertical development of maxilla and mandible. Anterior-posteriorly, the enlarged jaw angles rendered an inferior-posterior bowing appearance to the mandible. Based on history, clinical findings, radiographical and laboratory investigations, a diagnosis of progeria with post-streptococcal glomerulonephritis was given.

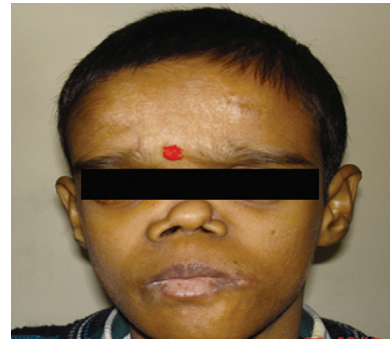

Figure 1 - Frontal profile showing pinched out nose.

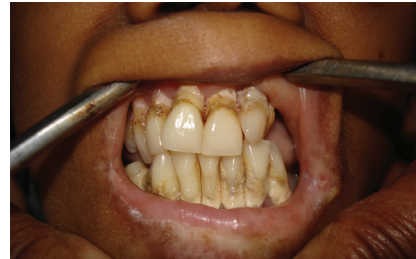

Figure 2 - Intraoral examination showing severe periodontitis, crowding, angular cheilitis and hypopigmented upper and lower lips.

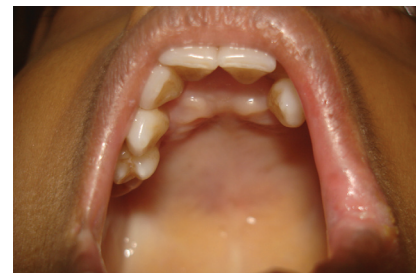

Figure 3 - Intraoral examination showing ogival palate and generalized pallor of the oral mucosa.

In general management, Asthalin nebulization was carried out 3 times daily for 6 days. Also Ventryl syrup 7.5 ml 3 times daily for 12 days was given, Supracef injection 250 mg intravenous 3 times daily for 11 days, injection Gentamycin 40 mg intravenous twice daily for 9 days, high dose steroids, along with which Tab Becosules and Cap Zevit was given once daily for 30 days. One week after the therapy, respiratory distress was resolved, and renal function was restored. Treatment for anemia was started with both intravenous and oral supplements. His condition remained stable one month following the treatment. He was sent for multidisciplinary approach, which included total extraction of his teeth, and thereafter oral rehabilitation with complete denture. However, he refused to undergo treatment.

Table 1 - Results of laboratory tests on a patient with Hutchinson-Gilford progeria syndrome seen at the Department of Oral Medicine and Radiology, St. Gregorios Dental College, Kothamangalam, Kerala, India.

Parameters	Values
Hemoglobin*	7.6 g%
Mean corpuscular volume*	75 microns ²
Mean corpuscular hemoglobin*	23 picogram
Neutrophils [†]	75.0%
Lymphocytes [†]	20.0%
Platelet count [‡]	4.4 lakhs/mm ³
Prothrombin time [‡]	15.5 seconds
High density lipoprotein [‡]	35 mg/dl
Blood urea [§]	102 mg/dl
Serum creatinine [§]	5.6 mg/dl
Sodium	137 millimol/l
Potassium	4.2 millimol/l
Alanine amino transferase**	50 IU/l
Aspartate amino transferase**	40 IU/l
Alkaline phosphatase**	200 IU/l
Urine albumin [§]	Slightly increased
Urine microscopy	
Pus cells [§]	15-20/HPF
Red blood cells [§]	10-15/HPF
Epithelial cells [§]	5-8/HPF
Compliment C ₃ ^{††}	50 mg/dl
Testosterone ^{††}	31.2 ng/dl
Anti-streptolysin O titer ^{§§}	1600 IU/ml

*These measurement revealed marked anemia of microcytic hypochromic nature. [†]Leukocyte series showed neutrophilia and mild lymphocytopenia. [‡]These features are pathognomonic for progeria, in which elevated platelet count and prothrombin time, and decreased high density lipoprotein is seen. [§]These parameters are pathognomonic for glomerulonephritis. ******These markers are suggestive of hepatic disorders. **††**These revealed reduced immunity. **†††**These revealed hypogonadism. **§§**The presence of elevated antibody titer signifies beta hemolytic streptococcal infection. IU/l - international unit per liter, IU/ml - international unit per milliliter, ng/dl - nanogram per deciliter, HPF - high power field, mg/dl - milligram per deciliter

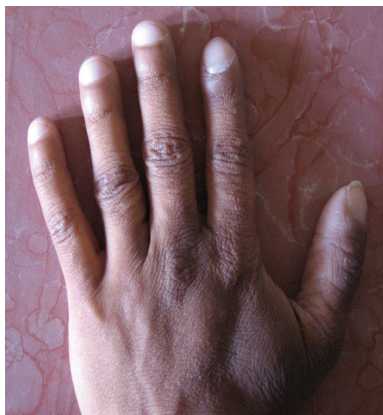

Figure 4 - A photograph showing the short fingers of the patient.

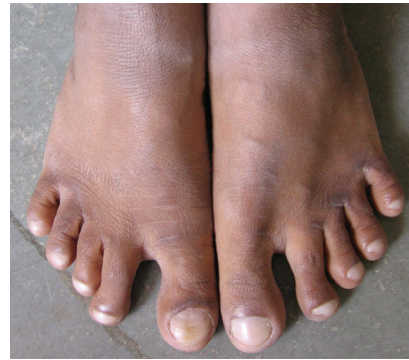

Figure 5 - A photograph showing the short toes of the patient.

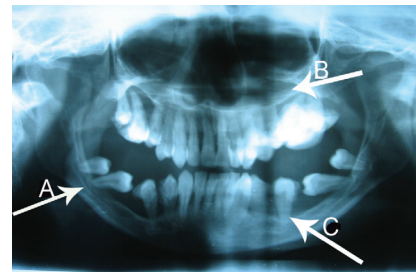


Figure 6 - Panoramic image showing: A) thinned basal bone height; B) pronounced curvature of the maxilla; C) severe periodontitis.

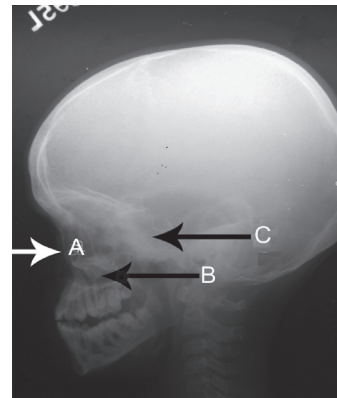


Figure 7 - True lateral radiograph showing: A) midfacial hypoplasia; B) hypoplastic maxillary sinus; C) absence of sphenoid sinus.

Discussion. Progeria is a rare genetic disorder, which includes oral abnormalities like micrognathia, thin lips, circumoral cyanosis, ogival palate, generalized pallor of oral mucosa, delayed eruption of teeth, hypodontia, most often missing second premolars, crowding, and ankyloglossia. The average dental age of some patients will not get along with chronologic age. The strength of the tongue is reduced. Our patient also gives a history of incomplete lip closure against pressure.¹

As part of treatment considerations, routine fluoride supplements should be provided to minimize the risk of dental caries. The regular oral prophylaxis minimizes the development of periodontal diseases, and also provide nutritional supplementation. In the first and second decades of life, accelerated atherosclerosis of major arteries is found to be the major cause of morbidity and mortality. Henceforth, awareness of certain clinical conditions that mimics the present disease would help physicians to bring a better treatment outcome.

Werner syndrome or Pangeria. An autosomal recessive condition characterized by later onset of premature ageing, usually in the second decade of life. The other features are high-pitched voice, beak shaped nose, sclerodermatous skin, immature sexual development, cataracts, and hypergonadism. In these patients, complications of atherosclerosis reduce life expectancy to the fifth decade.²

Gottron type of acrogeria. Inherited as autosomal recessive type. The onset is up to the age of 6 years. It is characterized by premature ageing of extremities, high-pitched voice, cutaneous atrophy, and subcutaneous wasting of face and extremities. Hair is unaffected in this condition. No atherosclerosis or systemic disease is noted.²

Rothmund-Thomson syndrome. The onset of this condition is 3-6 months of age. It is a rare autosomal recessive disorder, characterized by poikilodermatous skin changes, premature graying of the hair and/or alopecia, high-pitched voice, cataracts, microcephaly, short stature, increased photosensitivity, and hypogonadism. Intraoral findings are hypodontia, microdontia, supernumerary teeth, pronounced caries and delayed eruption.²

Cockayne syndrome. Is a rare autosomal disorder characterized by marked loss of subcutaneous fat, growth failure, increased photosensitivity, ocular abnormalities like optic atrophy, pigmented retinopathy, microcephaly, disproportionately large hands and feet, protruding ears, hoarse voice, sensori-neural hearing loss ataxia, and progressive mental deterioration. In this condition, death occurs earlier, typically by the age of 6-7 years.²

Seckel syndrome. The onset of this rare autosomal recessive condition is during neonatal or infancy. Consistent clinical features includes intrauterine growth retardation, high squeaky voice, bird head facies, dwarfism, trident hands, skeletal defects, hypodontia, hypersplenism, and premature graying of the hair.

Stiff skin syndrome. Inherited as autosomal dominant condition characterized by diffuse progressive hardening of skin, usually starting in the gluteal

region, beginning at birth, or early infancy. The onset of this disease range from infancy to 6 years of age, it is characterized by high-pitched hoarse voice, hyperpigmentation hypertrichosis, joint contractures, and increased cutaneous mucopolysaccharide levels.³

Restrictive dermopathy. A rare autosomal recessive condition characterized by weak voice, diffuse skin hardening, joint contractures, profound intrauterine growth retardation, characteristic facies, and pulmonary hypoplasia. Onset is during neonatal period or infancy. Other suggestive findings seen are wide cranial sutures, small pinched nose, low-set ears, microstomia, natal teeth, submucous cleft palate, dysplastic clavicles, rocker-bottom feet, scaly skin, and respiratory insufficiency.⁴

Berardinelli-Seip syndrome. The onset of the disease is at birth. Clinical presentation varies and the patients may present with decreased subcutaneous fat, pseudohypertrophy of muscles, hyperinsulinemia, acromegaloid appearance, deeper voice, baldness, acanthosis nigricans and hypertriglycerimias. The overall appearance is acromegalic due to enlargement of the mandible, hands, and feet.⁵

Growth retardation, alopecia, pseudoanodontia and optic atrophy (GAPO) syndrome. The onset of this disease is approximately one to 2 years, and the condition is characterized by growth retardation, alopecia, optic atrophy, coarse facies, craniofacial dysmorphism, aged appearance, joint laxity, and loose skin. Pseudoanodontia of both primary and permanent dentition with absence of alveolar ridge, micrognathia are the intraoral findings. Extra oral findings include protruding and thickened lips, prominent supraorbital ridges, depressed nasal bridge, and protruding auricles.⁶

Hallermann-Streiff syndrome. The onset is at birth, characterized by brachycephaly, steamy voice, absence of sexual maturation, alopecia, cutaneous atrophy of face and scalp, ocular abnormalities like cataract, nystagmus, microphthalmos, and dental anomalies such as hypodontia, coniform teeth, with hypoplastic enamel. Extra oral findings of the face are characteristically bird-like with low set ears, brachycephalic with frontal and parietal bossing, beaked nose, and microsomia with thin lips.⁷

Familial mandibuloacral dysplasia. The onset of the disease is during the age of 3-5 years. Condition is characterized by alopecia, high-pitched voice, delayed puberty, lack of sexual maturation, mandibular hypoplasia, premature loss of teeth, beaked voice, skin atrophy of extremities acroosteolysis, and delayed cranial suture closure.²

Bloom syndrome. The characteristic clinical findings includes short stature, a butterfly shaped rash on the cheeks that develops shortly after first exposure to the sun, and hypogonadism. Extra oral features includes high-pitched voice, long narrow face, micrognathic mandible, prominent nose and ears, hypo- and hyper-pigmented areas of the skin, and cafe-au-lait spots.

Mulvihill-Smith syndrome. This rare syndrome is characterized by premature ageing, low birth weight, short stature, and moderate mental retardation, associated with multiple pigmented nevi, and a distinctive bird-like facies. There is a small chin, with broad forehead, and the lack of facial subcutaneous fat gives an appearance of premature ageing. Other features include hypospadias, a high-pitched voice, irregular dentition, fine hair, hepatomegaly, and low immunoglobulin G.⁸

Geroderma osteodysplastica. Stunting of growth from early childhood is associated with senile changes in the skin with normal scalp hair. Wrinkly, lax skin is most prominent on the dorsa of the hands and feet. Generalized osteoporosis, multiple fractures, joint laxity and skeletal malformations, including Wormian bones occur. The face appears sad, with drooping eyelids, malar hypoplasia, and mandibular prognathism.²

Kindlers syndrome. An autosomal inherited recessive condition, presents with clinical features such as sun sensitivity, trauma-induced blistering, skin atrophy, poikiloderma and mucosal inflammation. Skin fragility and blistering are the most prominent findings seen among neonates. Other suggestive clinical findings include nail dystrophy, and pseudosyndactyly of the digits. In addition, periodontal disease with erosive gingivitis is seen in early stages.⁹

In conclusion, individuals diagnosed with progeria are relatively uncommon in the community. Furthermore, a combination of progeria with post-streptococcal glomerulonephritis is extremely rare. In this case report which depicts this rare combination, it resulted from

reduced level of compliment C₃ and lymphocyte count, which caused streptococcal infection that further led to glomerulonephritis. The authors also seek attention of clinician towards this disease, which by understanding of related abnormalities and clinical recognition, would help them to promptly initiate appropriate treatment, and to make appropriate referrals for best available patient care, which would in turn help them to improve treatment results.

Acknowledgment. *The authors gratefully acknowledge Dr. Ria Salim, Dr. Nithin Kurian, and Dr. Linu Maria for their valuable help in preparing this manuscript.*

References

1. Merideth MA, Gordon LB, Clauss S, Sachdev V, Smith AC, Perry MB, et al. Phenotype and course of Hutchinson-Gilford progeria syndrome. *N Engl J Med* 2008; 358: 592-604.
2. Burrows NP, Lovell CR. Disorders of connective tissue. In: Burns T, Breathnach S, Cox N, Griffiths C, editors. *Rook's Textbook of Dermatology*. West Sussex (UK): Wiley Blackwell; 2010. p. 45.1-45.7.
3. Liu T, McCalmont TH, Frieden IJ, Williams ML, Connolly MK, Gilliam AE. The stiff skin syndrome: case series, differential diagnosis of the stiff skin phenotype, and review of the literature. *Arch Dermatol* 2008; 144: 1351-1359.
4. Chiang MC, Huang SF, Hsueh C, Lai MW, Hou JW. Restrictive dermopathy: report of one case and the metabolic and post-mortem findings. *Turk J Pediatr* 2008; 50: 492-494.
5. Babu P, Sharma R, Jayaseelan E, Appachu D. Berardinelli-Seip syndrome in a 6-year-old boy. *Indian J Dermatol Venereol Leprol* 2008; 74: 644-646.
6. da Silveira HE, Quadros OF, Dalla-Bona RR, da Silveira HL, Fritscher GG. Dental findings in GAPO syndrome: case report. *Braz Dent J* 2006; 17: 1-4.
7. Kirzioğlu Z, Ceyhan D. Hallermann-Streif Syndrome: a case report from Turkey. *Med Oral Patol Oral Cir Bucal* 2009; 14: 236-238.
8. Yagoa K, Nakagawa T, Hyodo T, Kosakib K, Kawatac Y, Tanaka Y, et al. Mulvihill-Smith syndrome: A case report. *Asian Journal of Oral and Maxillofacial Surgery* 2011; 23: 186-190.
9. Salodkar A, Choudhary S, Koley S. Kindler syndrome: 2 Case Reports from India. *Iran J Dermatol* 2009; 12: 1-4.

Related Articles

Sui W, Dai Y, Zhang Y, Chen J, Liu H, Huang H, et al. Proteomic profiling of immunoglobulin A nephropathy in serum using magnetic bead based sample fractionation and matrix-assisted laser desorption/ionization-time of flight mass spectrometry. *Saudi Med J* 2010; 31: 1378-1379.

Dai Y, Sui W, Lan H, Yan Q, Huang H, Huang Y. Microarray analysis of micro-ribonucleic acid expression in primary immunoglobulin A nephropathy. *Saudi Med J* 2008; 29: 1388-1393.

Bohlega SA, Abu-Amero KK. Cerebral autosomal dominant arteriopathy with subcortical infarcts and leukoencephalopathy in Arabs. *Saudi Med J* 2008; 29: 952-956.