

Recurrent plunging ranula of the neck

Khalid A. Al Rubaimi, BDS, MSc Dr Med Dent.

ABSTRACT

يصف التقرير حالة تكرر الإنتفاخ الكيسي اللعابي المندفع والذي يشغل جزء كبير من العنق. يعد الانتفاخ الكيسي المندفع كيس كاذب يتكون من الإفراز اللعابي المستمر وبشكل رئيسي يعود لإنسداد الفتحات الإفرازية، ويظهر غالباً في قاع الفم. على أي حال الإنتفاخ الكيسي العنقي يحدث حين ينسد الإفراز اللعابي جريانه من الفتحات الإفرازية اللعابية ويسيل نحو الأسفل عبر المستوى الوجهي ويتجمع تحت الذقن، وتحت الفك وفي الفراغات العنقية. يشخص الإنتفاخ الكيسي بشكل رئيسي بالفحص السريري، ولكن في حال غياب العلامات المرئية داخل الفم قد يؤدي إلى الخطأ في التشخيص واللجوء للعلاج الجراحي الغير صحيح. أن وجود خميرة النشاء في السائل المسحوب من الكيس مساعد مهم في التشخيص التفريقي ويؤكد الأصول اللعابية للسوائل المتجمعة. هنالك طرق متعددة لعلاج الإنتفاخ الكيسي اللعابي تم طرحها في العديد من المقالات العلمية وبناتج متباينة. يتراوح معدل النكس حسب الإجراءات المتبعة وهذه الطرق العلاجية تتضمن التفجير، والإستئصال أو تصريف المحتوى، وإستئصال الغدة اللعابية تحت اللسان وتفرغها. إن الطريقة الصحيحة لعلاج الإنتفاخ الكيسي اللعابي المندفع يعتمد على إستئصال كامل للغدة اللعابية تحت اللسان المصابة وتفرغ محتواها. يصف هذا المقال طرق التحري والتشخيص الصحيحة والطريقة الصحيحة للعلاج.

The reported case describes a mismanaged extensive recurrent plunging ranula that occupied a large portion of the neck. The ranula is usually clinically diagnosed. However, absence of visible intra-oral signs may mislead the diagnosis and leads to improper surgical management. Presence of amylase in the aspirated fluids is an important aid in the differential diagnosis. Thereby confirming the salivary origin of the fluids and thus avoiding extensive investigations. The recurrence rate varies according to the procedure performed. Diverse methods of treating ranula have been reported in the literature with variable results. These include marsupialization, excision of the ranula, incision of the ranula and drainage of the contents, excision of the sublingual gland and drainage. The successful procedure to treat plunging ranula depends on complete excision of the affected sublingual gland

and drainage of its contents. In this paper, the useful diagnostic investigations and the recommended surgical intervention procedure were described.

Saudi Med J 2013; Vol. 34 (3): 313-315

From the Department of Oral and Maxillofacial Surgery, College of Dentistry, King Saud University, Riyadh, Kingdom of Saudi Arabia.

Received 15th December 2012. Accepted 13th January 2013.

Address correspondence and reprint request to: Prof. Khalid A. Al Rubaimi, Department of Oral and Maxillofacial Surgery, College of Dentistry, King Saud University, PO Box 60169, Riyadh 11545, Kingdom of Saudi Arabia. Tel. +966 (1) 4677320. Fax. +966 (1) 4695892. E-mail: rubaimi@ksu.edu.sa/Pr.Khalid@yahoo.com

The ranula is essentially pseudocystic entity arising from damage of one or more of the sublingual salivary gland ducts. The pathophysiology involved in the accumulation of the extravagated fluids is hypertension on the duct due to obstruction leads to acinar rupture in the salivary gland and then extravasation of its fluid. Subsequent accumulation of saliva may extend to the neck spaces through the facial planes.^{1,2} The oral ranula is more common than extraoral ranula, it raises the tongue upwards and presents as blue-domed translucent swelling.² The plunging or cervical ranula, on the other hand, develops when mucus passes through or below the mylohyoid muscle along the facial planes into the submental, submandibular or cervical spaces. Plunging ranula with a cervical extension may appears as a submandibular or neck swelling without visible intra-oral swelling and thus misleads the diagnosis.³⁻⁵

Case Report. A 35-year-old Saudi male patient was referred to our department for diagnosis and treatment of a swelling in his neck. Initial patient's history revealed that he had suffered from a swelling in the right side of the floor of the mouth 6 years before presenting to us. The patient stated that at the beginning, the swelling appeared sublingually and was fluctuant and gradually enlarged, remained for 3 months then resolved by itself without a need for a surgical intervention. Later, the

swelling recurred after 4.5 years from the first onset and appeared in the right submandibular region. Firstly, the patient had undergone a surgical intervention in another hospital which aimed to decompress and evacuate the fluids through a submandibular incision at the affected side. The patient reported that the swelling disappeared immediately after the surgery but recurred again in a few weeks time at the same site. He added that he had undergone a similar surgery at the same site for treating the same clinical presentation in a second hospital in a period of 6 months after the first surgery but the swelling recurred again in few months from the second surgery. He mentioned that the swelling had increased in size and extended to occupy the neck region. His past medical history was unremarkable and he did not suffer from pain during meal times but felt continuous pressure in the neck due to the swelling. He was referred to us after the lesion recurred for the third time. The referral indicated that the diagnosis of the lesion was a "benign hemorrhagic lympho-epithelial cyst" of salivary gland and the patient had undergone partial removal of the right submandibular gland. However, the referral report did not provide justification for this diagnosis nor reasons for performing this surgical procedure. The swelling appeared clinically as a soft, fluctuant, and not tender. It occupied the submental, submandibular, the anterior triangle region on the right side of the neck, extended inferiorly to the right clavicle and suprasternal notch region and cross the midline of the neck into the left supraclavicular region. The boundaries of the

lesion were ill defined (**Figure 1**). The floor of the mouth was not raised and appeared normal in texture. Saliva was expressed from all of the major salivary glands. The sialogram did not identify the sialorrhea from the lower right submandibular gland (**Figure 2**). The aspirated fluid from the swelling appeared as a viscous-blood tinged straw-colored fluid with positive value for amylase.

Based on these findings, the concluded diagnosis was a ranula from the right sublingual gland accumulated from continuous extravasation of saliva along the facial planes. Under general anesthesia, the right sublingual salivary gland was excised through an intra-oral approach. The cystic fluid was completely drained extraorally and a vacuum drain was placed in the swelling site at the neck region for 2 postoperative days. The partially resected submandibular gland was

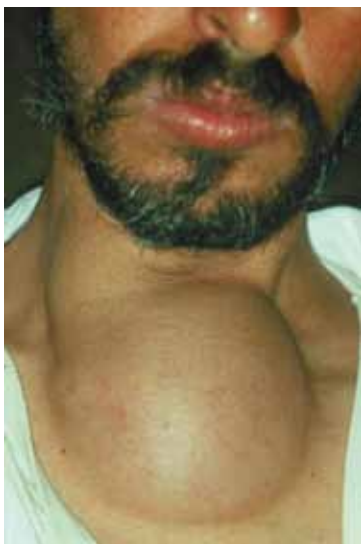

Figure 1 - View of the plunging ranula extended from the right submental and submandibular regions, occupies a large portion of the neck and extended inferiorly to the clavicle and suprasternal notch regions.

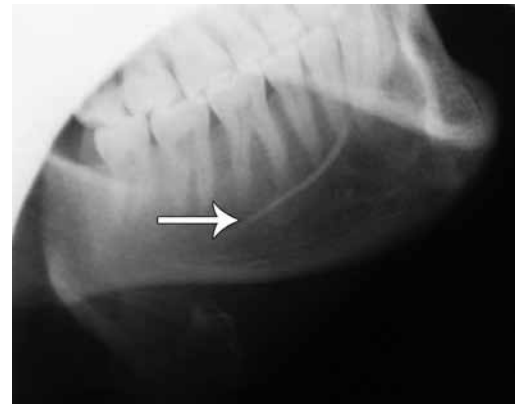

Figure 2 - Sialogram view of the right submandibular gland shows dead end of the submandibular gland duct (arrowed).

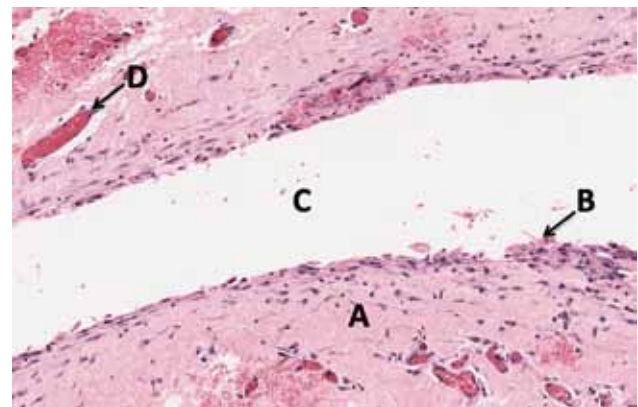


Figure 3 - The wall of the lesion devoid of epithelium, consisting of fibroblastic connective tissue A) lined by condensed granulation tissue, B) surrounding a cyst-like space and C) Inflammatory cells and dilated vessels, and D) are evident. (200× Hematoxylin and eosin).

excised completely at the same surgery through the previous submandibular scar to avoid post-surgical complications. Part of the ranula lining adjacent to the surgical site was excised and sent for histopathologic study. The histopathologic finding of the cystic lining showed zone of condensed fibrous tissue lining surrounding the ranula space (Figure 3). The sublingual salivary gland showed minimal inflammation while the excised submandibular gland presented normal gland lobules. The patient recovered well postoperatively without complications and all signs and symptoms of this entity disappeared.

Discussion. It is generally accepted that the cause of the plunging ranula is extravasation of saliva arising from the sublingual gland.¹ The lower position of the sublingual gland below the mylohyoid muscle was reported. Engel et al⁶ evaluated mylohyoid herniation in 100 cadavers and found 48% of these cases had mylohyoid herniation. Hopp et al⁷ pointed out with MRI, the anatomical anomalies in the mylohyoid muscle and herniation of the sublingual gland toward the congenital origin. Diagnostic sialogram of the submandibular gland of the affected side helps in rolling out the origin of the sialorrhea from the submandibular gland and determine the surgical approach and management of the cause.^{2,3} In the reported case, the origin of the ranula from the submandibular gland was excluded. The biochemical data of the aspirated cystic fluid differentiate the content of the lesion from other entities.⁸ The presence of amylase in the ranula mucinous fluids suggest active secretory source from the sublingual gland and this avoid extensive radiologic investigations. The recurrence rate of the ranula is not related to its swelling pattern, but intimately depends on the initial diagnosis of origin of the cause and the selected surgical procedure. These fundamentals have been missed in the initial treatment of our case. Different methods of treatment for ranulas have been reported in the literature with varying results. These include marsupialization, incision of the ranula and drainage, excision of the ranula and excision of the sublingual gland with drainage of ranula fluids.^{1,3,4,8-10} Zhao et al⁹ reviewed 580 treated ranula and found a recurrence of 66.7% with marsupialization, 57.7% with excision of the ranula alone, and 0% in case of excision

of sublingual gland and its ranula. Harrison¹⁰ reviewed the published treatment procedures for plunging ranula and concluded similar findings with high recurrence rate for marsupialization and excision of the ranula alone and the cure rate with excision of the sublingual gland. Samant et al⁸ reported their experience in series of 81 patients and supported the aspiration of the mucoid for identification of presence of amylase and hence reduce radiologic investigations. They recommended simple trans-oral sublingual gland excision with evacuation, but not excision of the ranula. However, there is a general agreement to avoid an extensive neck dissection of the cervical extended lobe of the ranula; hence, no need for an extra-oral approach to remove it.^{1,4,9}

In conclusion, the successful treatment for the plunging ranula includes excision of the affected sublingual salivary gland and evacuation of the contents of the extended ranula without a need for excision of the ranula.

References

1. Patel MR, Deal AM, Shockley WW. Oral and plunging ranulas: What is the most effective treatment? *Laryngoscope* 2009; 119: 1501-1509.
2. de Visscher JG, van der Wal KG, de Vogel PL. The plunging ranula. Pathogenesis, diagnosis and management. *J Craniomaxillofac Surg* 1989; 17: 182-185.
3. Shelley MJ, Yeung KH, Bowley NG, Sneddon KJ. A rare case of an extensive plunging ranula: discussion of imaging, diagnosis and management. *Oral Surg Oral Med Oral Pathol Oral Radiol Endod* 2002; 93: 743.
4. Chidzonga MM, Mahomva L. Ranula: experience with 83 cases in Zimbabwe. *J Oral Maxillofac Surg* 2007; 65: 79-82.
5. Morton RP, Ahmad Z, Jain P. Plunging ranula: Congenital or acquired? *Otolaryngol Head Neck Surg* 2010; 142: 104-107.
6. Engel JD, Harn SD, Cohen DM. Mylohyoid herniation: gross and histologic evaluation with clinical correlation. *Oral Surg* 1987; 63: 55-59.
7. Hopp E, Mortensen B, Kolbenstvedt A. Mylohyoid herniation of the sublingual gland diagnosed by magnetic resonance imaging. *Dentomaxillofac Radiol* 2004; 33: 351-353.
8. Samant S, Morton RP, Ahmad Z. Surgery for plunging ranula: the lesson not yet learned? *Eur Arch Otorhinolaryngol* 2001; 268: 1513-1518.
9. Zhao YF, Jia Y, Chen XM, Zhang WF. Clinical review of 580 ranulas. *Oral Surg Oral Med Oral Pathol Oral Radiol Endod* 2004; 98: 281-287.
10. Harrison JD. Modern management and pathophysiology of ranula: literature review. *Head Neck* 2010; 32: 1310-1320.