

Molluscum contagiosum in multiple epidermal cysts in an immunocompetent patient

Kayhan Basak, MD,
Pinar Y. Basak, MD, Nimet Karadayi, MD.

Molluscum contagiosum virus (MCV) infection occurring in an epidermal cyst (EC) is a very rare condition and only a few cases were reported in children and adults.¹⁻³ However, MCV in multiple small epidermal cysts (ECs) was not previously described. Therefore, this unusual case of molluscum infestation occurring in multiple ECs was presented. A 20-year-old female was evaluated with an asymptomatic, firm, flesh-coloured nodular lesion on temporal region of 6 months' duration. On dermatological examination, neither scale, punctum, or erosion on the surface of the lesion, nor similar lesions elsewhere were observed. She gave no history of previous medication, trauma or illness. A total excisional biopsy of the lesion was performed. Histopathological examination revealed hyperplastic inverted squamous epithelium forming cup shape (Figure 1A right) and 3 small cysts lining epithelium filled with lamellar keratinous material (Figures 1A left, & 1B). Cytoplasmic granular eosinophilic inclusions and molluscum bodies in keratinous surface were observed (Figure 1C). The wall of the cyst was lined by squamous epithelium, including a granular layer with keratohyaline granules. Numerous molluscum bodies were seen in the spinous, granular, and horny layers of the cyst wall (Figures 1D & 1E). The diagnosis of molluscum contagiosum was confirmed with clinical and histopathological findings. Results of the basic metabolic profile, complete blood count and anti-human immunodeficiency virus (HIV) antibody were within normal ranges. No recurrence of the lesion was noted during follow up.

Molluscum contagiosum is a common skin infection produced by a double-stranded deoxyribonucleic acid (DNA) virus of poxvirus family. Four major subtypes of MCV were defined from MCV-1 to MCV-4. Lesions of MCV are characterized by multiple, umbilicated papules in children, sexually active adults, and in some

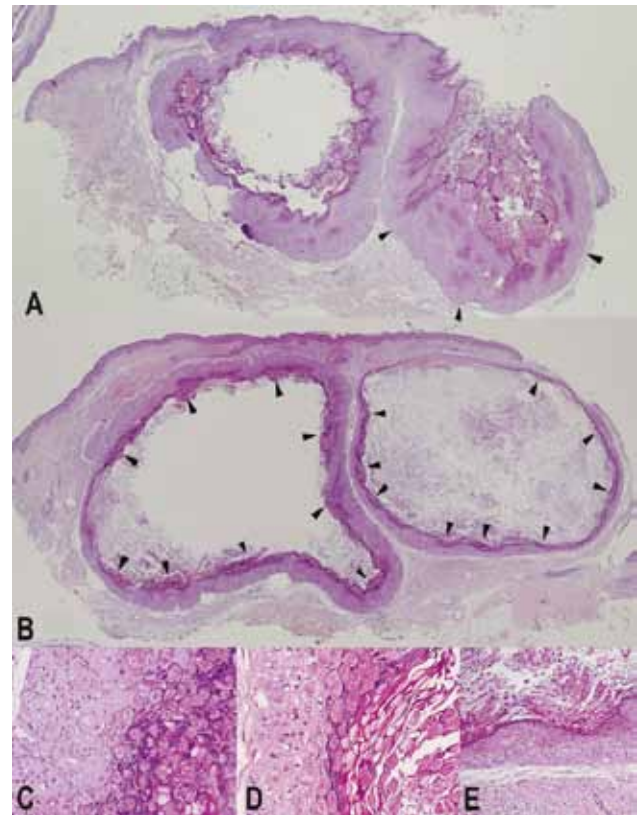


Figure 1 - Whole sections and microscopic features of the lesions A) Classical cup shape lesion of molluscum contagiosum virus (MCV) (right side, arrowheads) and cyst lined by squamous epithelium close to lesion of MCV. Note that the cysts had no ostium (left side) (Hematoxylin and eosin [H&E] stain x40, original magnification); B) Two other cysts contained eosinophilic inclusions and molluscum bodies (arrowheads) on most parts of the wall (H&E x40, original magnification); C-E) Molluscum bodies in molluscum contagiosum, cyst close to molluscum contagiosum and cyst in figure (H&E x200, x200, x100, original magnification).

immunosuppressed patients. Even though the disease is self-limiting, it may take several years for lesions to disappear.⁴ While various benign or malign conditions arising in cutaneous ECs were rarely observed, histopathological evaluation of all lesions clinically diagnosed as EC was suggested, especially in patients under local or systemic immunosuppressive treatment.³ Moreover, patients with advanced HIV disease were reported to have an increased incidence of MCV infection and a few cases of MCV in an EC in a HIV patient were described.² Nevertheless, anti-HIV antibody was negative, and there was not any sign of immunosuppression in the presented case.

The MCV infection might be suggested to play a role in the development of some of the benign epithelial cystic lesions, in which the cytopathic features of this virus were identified.⁵ The reason for the presence of MCV in EC was

Disclosure. The authors have no conflict of interests, and the work was not supported or funded by any drug company.

not definitely known. Whether this was an invasion of a pre-existing EC by MCV from the ostium that connected EC with epidermis, or co-inoculation of MCV infection at the time of the formation of the cyst has still been a debate. Co-existence of typical MCV lesions in the same patient was described, and superficial MCV lesions on the skin have subsequently appeared adjacent to a site of an MCV-infected EC.^{1,3} Physical manipulation was proposed to implant MCV into the EC in a few cases,² while downward extension and cystic change in a preexisting MCV lesion was also reported to be a possibility by Phelps et al⁵ who recently demonstrated large multi-loculated cyst with close approximation of MCV infection throughout the entire cyst wall.

Most of the ECs were known to have small ostium opening to the skin surface so that MCV might be transmitted from the surface of skin into EC, or from infected EC to the neighboring skin.¹⁻³ Due to close relationship of MCV lesion and EC as shown in Figure 1A, and also neighboring of 2 other cysts with MCV lesion, direct continuity with components of the hair follicle could not be ruled out in this case. However, the common feature of all 3 cysts in the presented case was that they did not have any ostium although searched in serial histological sections. Physical manipulation could be the possible reason for spreading of MCV to other parts of the cyst wall. Nevertheless, history of trauma was absent, and histopathology was not supportive of a preceding physical manipulation.

In conclusion, abundance of MCV-infected cyst wall in all of the 3 ECs might be more likely postulated that ECs were derived from an infected epithelium. Moreover, differing from the previous cases, co-existence of MCV infection with multiple small ECs was the striking feature of the presented case.

Received 17th December 2012. Accepted 16th February 2013.

From the Department of Pathology (Basak K, Karadayi), Dr. Lutfi Kirdar Kartal Educational and Research Hospital, Istanbul, and the Department of Dermatology (Basak P), Faculty of Medicine, Suleyman Demirel University, Isparta, Turkey. Address correspondence and reprints request to: Prof. Pinar Y. Başak P, Faculty of Medicine, Suleyman Demirel University, Isparta, Turkey. Tel. +90 (246) 2119313. Fax. +90 (246) 2371165. E-mail: pinarbasak@hotmail.com

References

1. Chiu HH, Wu CS, Chen GS, Hu SC, Hung CH, Lan CC. Molluscum contagiosum infestation in an epidermal cyst: still infectious? *J Eur Acad Dermatol Venereol* 2010; 24: 81-83.
2. Aldabagh B, Ly MN, Hessel AB, Usmani AS. Molluscum contagiosum involving an epidermoid cyst with xanthogranuloma-like reaction in an HIV-infected patient. *J Cutan Patol* 2010; 37: 282-286.
3. Kanitakis J. Molluscum contagiosum in an epidermoid cyst. *Am J Dermatopathol* 2011; 33: 638-640.
4. Hanson D, Diven DG. Molluscum contagiosum. *Dermatol Online J* 2003; 9: 2.
5. Phelps A, Murphy M, Elaba Z, Hoss D. Molluscum contagiosum virus infection in benign cutaneous epithelial cystic lesions-report of 2 cases with different pathogenesis? *Am J Dermatopathol* 2010; 32: 740-742.

Case Reports

Case reports will only be considered for unusual topics that add something new to the literature. All Case Reports should include at least one figure. Written informed consent for publication must accompany any photograph in which the subject can be identified. Figures should be submitted with a 300 dpi resolution when submitting electronically or printed on high-contrast glossy paper when submitting print copies. The abstract should be unstructured, and the introductory section should always include the objective and reason why the author is presenting this particular case. References should be up to date, preferably not exceeding 15.