

# New method for evaluation of cervical vertebral maturation based on angular measurements

Adel M. Alhadlaq, MS, PhD, Eman I. Al-Shayea, BDS, MS.

## ABSTRACT

**الأهداف:** دراسة مدى فاعلية طريقة جديدة لتحديد نضج الفقرات العنقية بناءً على قياس زوايا التقعر للحدود السفلية للفقرات العنقية.

**الطريقة:** تم استخدام أفلام الأشعة السينية لكف ورسغ اليد والأشعة السينية السيفالوميترية لعدد 197 طفل ذكر سعودي تتراوح أعمارهم بين 10-15 عام يراجعون قسم التقويم، جامعة الملك سعود، الرياض، المملكة العربية السعودية. بعد ذلك تم تحديد العمر الهيكلي لكل فرد من العينة باستخدام طريقة جروليتش وبايل وتحديد مرحلة النضج الهيكلي لكف اليد باستخدام مؤشرات فيشمان. وقد تم وصف طريقة جديدة لتحديد نضج الفقرات العنقية استناداً إلى قياسات زاوية لتقعر الحدود السفلية للفقرات العنقية الثانية والثالثة والرابعة واستخدام هذه الطريقة في تحديد مدى النضج الهيكلي للفقرات العنقية لدى عينة البحث. بعد ذلك تمت مقارنة مراحل النضج الهيكلية المحددة بالطريقة الجديدة مع مراحل النضج الهيكلي لعينة الدراسة المحددة باستخدام الطرق التقليدية المعتمدة على الأشعة السينية لكف ورسغ اليد.

**النتائج:** أظهرت الدراسة ارتباطاً إحصائياً مهماً ( $r=0.94$ ) بين مراحل النضج الهيكلي المحددة بالطريقة الجديدة والعمر الهيكلي لعينة الدراسة المحددة بطريقة جروليتش وبايل. كذلك أوضحت الدراسة وجود ارتباطاً إحصائياً مهم ( $r=0.94$ ) بين مراحل النضج الهيكلي المحددة بالطريقة الجديدة ومؤشرات فيشمان للنضج الهيكلي المحددة من أفلام الأشعة لكف ورسغ اليد لعينة الدراسة.

**خاتمة:** إن الطريقة الجديدة لتحديد نضج الفقرات العنقية بناءً على قياس زوايا التقعر للحدود السفلية للفقرات العنقية فاعلة وقابلة للتطبيق لتحديد مدى النضج الهيكلي عند الأطفال الذكور في مرحلة النمو.

**Objectives:** To investigate the validity of a new approach to assess the cervical vertebral maturation based on angular measurements of the lower border concavity of cervical vertebral bodies.

**Methods:** Hand-wrist and lateral cephalometric radiographs of 197 male subjects with age range of 10-15 years attending the orthodontic clinic at King Saud

University, Riyadh, Kingdom of Saudi Arabia were utilized. The study was carried out between September 2009 and May 2011. The study sample was divided into 6 groups (group 1: 10 years to group 6: 15 years) based on the chronological age of the subject. The skeletal age of the subjects was determined using Greulich and Pyle's standard radiographic atlas, and skeletal maturation was assessed by Fishman's skeletal maturity indicators. The cervical vertebral maturation (CVM) of subjects was determined using angular measurements of the second, third, and fourth cervical vertebral bodies. The validity of the newly developed method was assessed by examining the correlation between CVM stages determined by the angular measurements and the skeletal maturation level as determined by the standard hand-wrist methods.

**Results:** A significant correlation ( $r=0.94$ ) was found between the angular CVM stages and the skeletal age determined by Greulich and Pyle's atlas from hand-wrist radiographs. Also, a high correlation ( $r=0.94$ ) was found between the angular CVM stages and the Fishman's hand-wrist skeletal maturity indicators.

**Conclusion:** The new angular measurement approach to determine CVM is valid and has the potential to be applied in assessing skeletal maturity level in growing male children.

*Saudi Med J 2013; Vol. 34 (4): 388-394*

*From the Division of Orthodontics, Department of Pediatric Dentistry and Orthodontics, College of Dentistry, King Saud University, Riyadh, Kingdom of Saudi Arabia.*

*Received 9th February 2013. Accepted 5th March 2013.*

*Address correspondence and reprint request to: Dr. Adel M. Alhadlaq, Division of Orthodontics, Department of Pediatric Dentistry and Orthodontics, College of Dentistry, King Saud University, PO Box 60169, Riyadh 11545, Kingdom of Saudi Arabia. Tel. +966 (1) 4677393. Fax. +966 (1) 4677326. E-mail: aalhadlaq@hotmail.com*

Assessment of individual physical maturation is a routine clinical practice among multiple health disciplines.<sup>1</sup> In orthodontics, assessment of skeletal maturation is considered an integral part of clinical practice to determine the appropriate timing of growth modification therapy, and to plan for orthognathic surgery.<sup>2</sup> Chronological age is generally regarded as a poor indicator of the individual's growth status due to significant individual growth variation.<sup>3</sup> Although some other biological indicators, such as morphological age and sexual age, can be suitable indicators of the skeletal maturity, they cannot be used to predict the timing of maximum growth due to their retrospective nature.<sup>4,5</sup> On the other hand, skeletal age is frequently determined by assessing the maturational status of specific bony markers within the skeletal system and is considered the most reliable to correlate with the general biologic and physiological body maturation.<sup>6,7</sup>

Conventionally, hand-wrist radiographs were used to indicate the stage of an individual's skeletal maturity and to forecast the onset of pubertal growth spurt.<sup>2,8,9</sup> The assessment of hand-wrist radiograph can be performed either by estimating the skeletal age from a reference atlas of hand-wrist radiographic images,<sup>10,11</sup> or by relating specific bone maturation indicators in the hand-wrist region to the pubertal growth curve.<sup>8,12-14</sup> More recently, the evaluation of skeletal maturation from lateral cephalometric radiographs through the assessment of cervical vertebral maturation (CVM) is increasingly becoming the standard procedure.<sup>4,6,15,16</sup> The ability to estimate skeletal maturity level from lateral cephalometric radiographs can eliminate the need for hand-wrist radiographs; and thus, saving the patient the additional cost and exposure to radiation. All described CVM assessment methods, however, imply either simple description of the geometric shape of cervical vertebral body or the use of linear dimensional measurements of the vertebral body and the lower border concavity.<sup>4,6</sup> High subjectivity, and individual variability are expected when the geometric shape description is utilized and the linear measurements are generally affected by variations in the radiographic technique and magnification.<sup>17</sup>

The purpose of the present study was to describe and assess the validity of a novel approach for the assessment

of CVM from lateral cephalometric radiographs based on angular measurements of the lower border concavity of the cervical vertebral bodies.

**Methods.** Lateral cephalometric radiographs and the hand-wrist radiographs of 197 Saudi boys obtained from the initial records of patients attending the Orthodontic Clinic at the College of Dentistry, King Saud University, Riyadh, Kingdom Saudi Arabia, were utilized in this retrospective cross-sectional study. All subjects were between the ages of 10-15 years. Appropriate approval from the institutional ethical committee was obtained prior to the commencement of this study. The sample was segregated into 6 groups based on chronological age of the subjects (10 years, n=30; 11 years, n=31; 12 years, n=40; 13 years, n=32; 14 years, n=33; 15 years, n=31). The chronological age was calculated from the birth date documented in the orthodontic chart of each subject. Only subjects with a maximum of  $\pm 3$  months than the absolute value of each chronological age group were included in the study. All subjects included in the study fulfilled the following criteria: Documented date of birth in the patient's chart. Availability of standardized and high quality hand-wrist radiograph of the left hand, and a lateral cephalometric radiograph. The exclusion criteria of subjects for this study were: Any serious illness that may affect normal growth and development. Any previous orthodontic treatment. Any previous trauma or injury to the face or hand-wrist region. Any congenital or acquired malformation of the cervical vertebrae or hand-wrist area. Any developmental abnormalities due to the presence of syndromes or hormonal disorders.

The skeletal age for each subject was determined by comparing the hand-wrist radiograph with the hand-wrist radiographic images in the Greulich and Pyle's hand-wrist radiographic atlas.<sup>11</sup> The assessment of the skeletal maturity stage from the hand-wrist radiograph was based on Fishman's skeletal maturity indicators (SMI).<sup>13</sup> The ossification stages identified were SMI 1 (PP3 =) to SMI 11 (R). The SMI 1 is when the epiphysis and diaphysis of the proximal phalanx of the third finger are equally wide. The SMI 2 (MP3 =) occurs when the epiphysis and diaphysis of the middle phalanx of the third finger are equally wide. The SMI 3 (MP5 =) is identified when the epiphysis and diaphysis of the middle phalanx of the fifth finger are equally wide. The SMI 4 (S) marks the ossification of the ulnar-metacarpophalangeal sesamoid on the first finger. The SMI 5 (DP3cap) is recognized when the epiphysis forms a cap around the diaphysis on the distal phalanx of the third finger. When the epiphysis forms a cap around the diaphysis on the middle phalanx of the

**Disclosure.** This work has been partly funded by the College of Dentistry Research Center at King Saud University, Riyadh, Kingdom of Saudi Arabia. The authors declare no conflicts of interest, and that this study has not been sponsored by any company.

third finger it is known as SMI 6 (MP3cap), while if the same capping occurs on the middle phalanx of the fifth finger it becomes SMI 7 (MP5cap). The SMI 8 (DP3u) reflects the fusion of the epiphysis and diaphysis of the distal phalanx on the third finger, and the SMI 9 (PP3u) designates the fusion of the epiphysis and diaphysis of the proximal phalanx on the third finger. The SMI 10 (MP3u) means the fusion of the epiphysis and diaphysis of the middle phalanx on third finger. Lastly, the SMI 11 (R) reveals complete union of the epiphysis and diaphysis of the radius.<sup>13</sup>

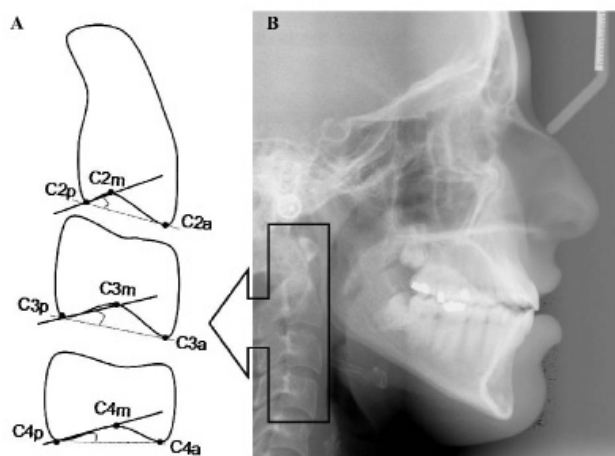
All lateral cephalometric evaluations were performed manually by the same examiner using a standard setting with a radiographic illuminated viewing box in a darkened room. All angular measurements performed were evaluated within an accuracy range of 0.5 degrees. The standard cervical vertebral analysis was performed using the Baccetti et al<sup>6</sup> method, which is composed of 5 stages. The CVMS I stage is described when the lower borders of the second (C2), third (C3), and fourth (C4) cervical vertebrae are flat, with possible exception of a

concavity at the lower border of C2. The bodies of both C3 and C4 are trapezoidal in shape. When a concavity at the lower border of both C2 and C3 appears, this marks the transition to CVMS II stage. The bodies of both C3 and C4 may be either trapezoidal or rectangular horizontal in shape at CVMS II stage. However, when the bodies of both C3 and C4 are rectangular horizontal in shape with a concavity present at the lower border of C2, C3, and C4 this indicates that CVMS III stage is reached. The transition to CVMS IV stage is marked by the bodies of both C3 and C4 being square in shape with a concavity present at the lower border of C2, C3, and C4. Finally, CVMS V stage is identified by the bodies of both C3 and/or C4 being rectangular vertical in shape with a concavity present at the lower border of C2, C3, and C4.

A new approach to CVM evaluation based on angular measurements of the concavity of the lower border of the cervical vertebral bodies of C2, C3, and C4 cervical vertebrae were performed. Landmarks modified from the method of Baccetti et al<sup>6</sup> were labeled C2p, C2m, and C2a to represent the most posterior, deepest, and anterior points on the inferior border of the body of C2. Similarly, C3p, C3m, and C3a represent the most posterior, deepest, and anterior points on the inferior border of the body of C3. Also, C4p, C4m, and C4a represent the most posterior, deepest, and anterior points on the inferior border of the body of C4 (Figure 1).

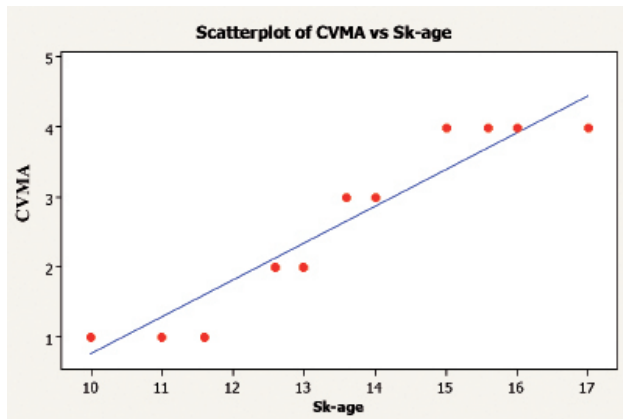
Based on the defined landmarks, angular measurements were performed to identify the C2, C3, and C4 angles (Figure 2). The C2 angle represents the angular measurement value between a line connecting C2p to C2a and a line connecting C2p to C2m. Likewise, the C3 angle represents the angular measurement value between a line connecting C3p to C3a and a line connecting C3p to C3m. Lastly, the C4 angle represents the angular measurement value between a line connecting C4p to C4a and a line connecting C4p to C4m (Figure 1).

Subsequently, the average value of the 3 angular measurements (C2, C3, and C4 angles) was calculated for each subject (C2-C3-C4 average) and was matched to the CVMS classification of each subject. Based on the minimum and maximum value of C2-C3-C4 angle average at each CVMS group (Table 1), the study sample was categorized into 5 distinct cervical vertebral maturity stages based on the angular measurements. These newly developed stages were categorized to formulate a new cervical vertebral maturation-angular (CVMA) classification. The first CVMA stage (CVMA 1) is identified when the average C2-C3-C4 angular



**Figure 1** - Description of cervical vertebral angular method : A) Lateral cephalometric radiograph showing the cervical vertebrae. B) Schematic representation of cephalometric landmarks identified on the inferior border of 2nd, 3rd, and 4th cervical vertebrae and the angular measurement performed at each vertebral body. C2p, C3p, C4p: The most posterior point on the inferior border of the body of 2nd, 3rd, and 4th cervical vertebrae. C2m, C3m, C4m: The deepest point on the concavity of the inferior border of the body of 2nd, 3rd, and 4th cervical vertebrae. C2a, C3a, C4a: The most anterior point on the inferior border of the body of 2nd, 3rd, and 4th cervical vertebrae. This figure is reproduced with special permission from the King Saud University Journal of Dental Sciences. Original source: Alhadlaq AM. Prediction of Mandibular Growth Potential using Cervical Vertebral Bone Age in Saudi Subjects. King Saud University Journal of Dental Sciences 2010; 22: 1-7.





**Figure 2** - Scatterplot between cervical vertebral maturation angular stages (CVMA) and skeletal age (SK-age) groups.  $r=0.94$ ,  $p=0.000$ , where  $p<0.05$ .

**Table 1** - The distribution of subjects and the descriptive values of average C2+C3+C4 angular measurements (C-Ave) at each CVMS.

CVMS	No.	C-Ave (°)		
		Min	Max	X
I	101	0	0	0
II	37	2	6	4.03
III	30	7	10.3	8.44
IV	29	11.3	17	14.29
V	-	-	-	-

C2 - second cervical vertebra, C3 - third cervical vertebra,  
 C4 - fourth cervical vertebra, CVMS - cervical vertebral maturation stage, X - mean value, Min - minimum value,  
 Max - maximum value

measurement equals to 0°. When the average angular measurement of C2-C3-C4 is larger than 0° but less than or equal to 6°, the CVMA stage is known as CVMA 2. The CVMA 3 stage is reached when the average C2-C3-C4 angular measurement is larger than 6° but less than or equal to 10.3°. If the average C2-C3-C4 angular measurement is larger than 10.3° but less than or equal to 17°, the CVMA 4 stage is identified. Lastly, the CVMA 5 stage is recognized when the average C2-C3-C4 angular measurement is larger than 17°.

All cephalometric and hand-wrist radiographs were obtained using Planmeca-Intra Cephalometer (PM 2002 EC Proline, Helsinki, Finland) with a focal-film distance of 170 cm on intensifying screen-film (no grid; 60 kV).

Descriptive statistics were performed among various experimental groups. Nonparametric Spearman's correlation test was used to correlate the CVMA stages

with the skeletal age and SMI stages as determined by the hand-wrist method. In addition, the correlation between different CVMA stages and chronological age groups was established. All data were analyzed using the Statistical Package for Social Sciences version 13 (SPSS Inc., Chicago, IL, USA). Dahlberg's double determination method error, correlation coefficient, and the student's t-test were used to determine the intra-examiner reliability of readings when they were performed by the same examiner 3 weeks later for 20 randomly selected hand-wrist and lateral cephalometric radiographs. The intra-examiner correlations showed significant reliability and minimum method errors of all readings as demonstrated by high coefficient values ranging from 0.97 to 0.99 ( $p<0.001$ ). In addition, weighted kappa test was determined to assess agreement between the 2 measurements based on categorical variables and was found to be 0.75-1.00. Multiple regression analysis was performed to predict the CVMA stages from the chronological age, skeletal age, and the SMI stages. The stepwise method was used to exclude the non-significant predictor variables. The model has only SMI as significant predictor variable and this model explained 93.3% of the total variation. The adjusted determinant coefficient (adj. R2) of this model was 0.933 with F  $p$ -value = 0.000. The statistical model used was:  $CVMA = 0.498 + 0.418 (SMI)$ . In all statistical assessments performed, the level of significance was recognized at 95% level of confidence ( $p<0.05$ ) to indicate the statistical significance between the studied variables.

**Results.** Descriptive statistics for all study groups are presented in Table 2. The trend of association between CVMA stages and skeletal age groups is shown in Figure 2. The results of the regression analysis are presented in Table 3. Spearman's rank-correlation coefficient test between CVMA stages and skeletal age groups revealed a high correlation value ( $r=0.94$ ,  $p=0.000$  where  $p<0.05$ ). Similarly, a high correlation value was observed when CVMA stages were plotted against different SMI stage groups ( $r=0.94$ ,  $p=0.000$  where  $p<0.05$ ) (Figure 3). In addition, a significant correlation was present between CVMA stages and chronological age groups ( $r=0.75$ ,  $p=0.001$  where  $p<0.05$ ) (Figure 4).

**Discussion.** Chronological age is not a valid predictor of the individual's growth velocity and skeletal maturity level.<sup>3,18</sup> The validity of the hand-wrist method in the assessment of skeletal maturity level has been well established for multiple racial groups.<sup>2,7-9,13,19</sup> Recently, the use of the CVM method for skeletal

**Table 2** - Descriptive statistics of all study groups.

Variable	X (SD)	Min	Max	Sig. (p-value) between CA & SA
CA (yrs)	12.51 (1.67)	10	15	0.013
SA (yrs)	12.23 (2.01)	10	17	
SMI	-	1	10	
CVMS	-	I	IV	
C-Ave (°)	4.15 (5.27)	0	17	
CVMA	-	1	4	

X - mean value, SD - standard deviation, Min - minimum value, Max - maximum value, CA - chronological age, SA - skeletal age, SMI - skeletal maturity indicators, CVMS - cervical vertebral maturation stage, C-Ave - average of C2+C3+C4 angular measurements, CVMA - cervical vertebral maturation stage-angular method, Sig - approximate significance

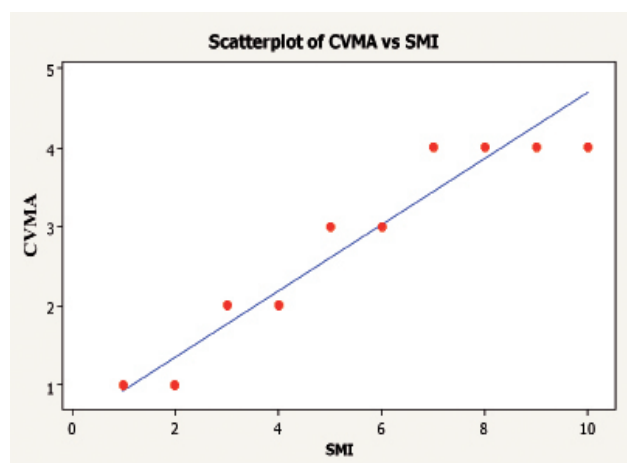
**Table 3** - Regression analysis results.

Variable	B	t	P-value	95% confidence interval		Adjusted R <sup>2</sup>
				lower bound	upper bound	
Constant (b <sub>0</sub> )	0.498	14.377	0.000*	0.429	0.566	0.932
SMI (b <sub>1</sub> )	0.419	51.901	0.000*	0.403	0.435	

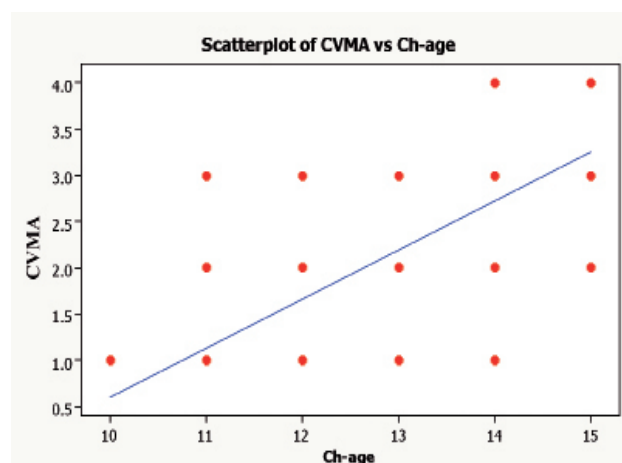
There were high correlation between skeletal age and SMI. The same model was produced by stepwise method where the skeletal age's effect was controlled. SMI - skeletal maturity indicators, CVMA dependent variable, \*p<0.05

maturity assessment has been recommended to replace the traditional hand-wrist radiographic method.<sup>4,6,15,20,21</sup> By enabling the clinician to evaluate skeletal maturation directly from routinely obtained lateral cephalograms, the patient will be guarded against additional cost and radiation.

The present study was carried out to assess the validity of a new CVM assessment approach to determine the skeletal maturity level against the standard hand-wrist methods. In this study, only male subjects were included to rule out any gender-dependent variability in the sample. Some differences in the timing of morphological changes in cervical vertebral bodies and growth pattern between boys and girls have been reported.<sup>20</sup> The circum pubertal age range (10-15 years) was selected to ensure proximity of the subjects to the pubertal growth peak when maturational changes in cervical vertebral bodies are more intense and noticeable.<sup>5,15</sup> Also, this circum pubertal age range is the most common age range for individuals to receive their orthodontic treatment because of the appropriateness to perform growth modification therapy and the coincidence with the full eruption of permanent dentition.<sup>5,6,22</sup> In addition, the availability of hand-wrist radiographs for patients younger or older than this age range is unlikely. The number of subjects per each chronological age group was selected based on the availability of records to ensure fair distribution of subjects among different chronological age groups. The assessment of skeletal maturity stage by the hand-wrist method in this study was performed using the skeletal maturation indicators introduced by Fishman.<sup>13</sup> This system is relatively simple



**Figure 3** - Scatterplot between cervical vertebral maturation angular stages (CVMA) and skeletal maturity indicator (SMI) groups.  $r = 0.94$ ,  $p=0.000$ , where  $p<0.05$



**Figure 4** - Scatterplot between cervical vertebral maturation angular stages (CVMA) and chronological age (ch-age) groups.  $r=0.75$ ,  $p=0.001$  where  $p<0.05$

and predictable to evaluate skeletal maturity level from the hand-wrist radiograph.<sup>8,13,23,24</sup> The SMI method has been regarded as one of the most appropriate methods for skeletal maturity evaluation that can be easily and accurately associated with the growth curve to predict the timing of the pubertal growth spurt.<sup>8</sup>

The CVM assessment in the present study was performed using the CVMS method established by Baccetti and co-workers.<sup>6</sup> The simplified approach and high correlation with the hand-wrist method in estimating the skeletal maturity level have contributed to its wide popularity.<sup>5,15,16,19,21,23</sup> The newly introduced approach to evaluate CVM was developed to establish the CVM based on an objective angular measurement of the concavity of the lower border of the second, third, and fourth cervical vertebrae and to take into account the limitations of the previously described CVM methods.<sup>17</sup>

The mean skeletal age of the whole sample was found to be significantly different from the mean chronological age of the sample (Table 2). A similar finding has been reported for other racial groups.<sup>2,21-23</sup> The tendency for late skeletal maturity has been previously reported in Saudi male subjects.<sup>19</sup> On the other hand, Thai individuals have been reported to show early skeletal maturation.<sup>25</sup> The discrepancy in this finding among the different studies can be potentially related to the different ethnic background of the subjects, and the different environmental factors affecting the pace of skeletal maturation. Also, it should be noted that the correlation between skeletal maturation level as assessed by the CVMA method and the chronological age, though significant in this study, was considerably smaller than between the CVMA and the hand-wrist assessment methods. These findings show, once again, that chronologic age is not a first-choice parameter to evaluate skeletal maturation in a growing subject.<sup>3</sup>

The correlation obtained in this study between the newly introduced CVMA stages and the SMI stages is comparable with the correlation values reported in the literature between the CVM and hand-wrist methods. A similar high correlation value has been reported by Alkhal and co-workers.<sup>23</sup> In general, previous investigations have demonstrated quite variable correlation values between hand-wrist and CVM methods ranging from 0.45-0.97.<sup>19,22-24,26-28</sup> Such inconsistency can potentially be attributed to multiple factors including differences in sample size, gender, ethnic background, and/or subjectivity of the utilized methods.

The CVM-angular approach proved to be a valid method to assess skeletal maturation as demonstrated by its high correlation with the standard hand-wrist

assessment methods using the skeletal age atlas and Fishman's SMI standards.<sup>11,13</sup> Moreover, the CVM-angular method has the potential to overcome the shortcomings of current CVM assessment methods such as the subjectivity in assessment, the individual variability between examiners, and the radiographic magnification effect associated with linear measurements. If the CVM-angular method is incorporated into cephalometric analysis software, it will provide the clinician with a quick and reliable technique to evaluate skeletal maturation of growing children simply by locating few landmarks on the cervical vertebrae.

In conclusion, the described CVM-angular approach is valid for the assessment of skeletal maturation level in growing boys. This method can be considered as an objective means to identify the level of individual skeletal maturity and estimate the pubertal growth peak without the need for an additional hand-wrist radiograph. Limitations of the study include the sample size, distribution of the sample to be representative of Saudi Arabia, and the gender limitation to male subjects only. Further studies are required to increase the sample size, include female sample, and improve sample distribution over other regions of Saudi Arabia to establish the norms of the new CVM-angular approach for the Saudi population.

**Acknowledgment.** *The authors are indebted to Mr. Nasr Al-Maftehi for his help and advice with the statistical work. Also, the authors would like to acknowledge the Research Center at the College of Dentistry, King Saud University, for partly funding this study.*

## References

1. Beker L. Principles of growth assessment. *Pediatr Rev* 2006; 27: 196-197.
2. Gandini P, Mancini M, Andreani F. A comparison of hand-wrist bone and cervical vertebral analyses in measuring skeletal maturation. *Angle Orthod* 2006; 76: 984-989.
3. Bala M, Pathak A, Jain RL. Assessment of skeletal age using MP3 and hand-wrist radiographs and its correlation with dental and chronological ages in children. *J Indian Soc Pedod Prev Dent* 2010; 28: 95-99.
4. Baccetti T, Franchi L, McNamara JA Jr. The cervical vertebral maturation method: some need for clarification. *Am J Orthod Dentofacial Orthop* 2003; 123: 19A-20A.
5. Santos EC, Bertoz FA, Arantes Fde M, Reis PM, de Bertoz AP. Skeletal maturation analysis by morphological evaluation of the cervical vertebrae. *J Clin Pediatr Dent* 2006; 30: 265-271.
6. Baccetti T, Franchi L, McNamara JA Jr. The cervical vertebral maturation (CVM) method for the assessment of optimal treatment timing in dentofacial orthopedics. *Semin Orthod* 2005; 11: 119-129.
7. Suma GN, Rao BB, Annigeri RG, Rao DJK, Goel S. Radiographic correlation of dental and skeletal age: Third molar, an age indicator. *J Forensic Dent Sci* 2011; 3: 14-18.

8. Flores-Mir C, Nebbe B, Major PW. Use of skeletal maturation based on hand-wrist radiographic analysis as a predictor of facial growth: a systematic review. *Angle Orthod* 2004; 74: 118-124.
9. Mahajan S. Evaluation of skeletal maturation by comparing the hand wrist radiograph and cervical vertebrae as seen in lateral cephalogram. *Indian J Dent Res* 2011; 22: 309-316.
10. Tanner JM, Whitehouse RH, Cameron N, Marshall WA, Healy MJR, Goldstein NH. Assessment of Skeletal Maturity and Prediction of Adult Height (TW2 Method). London (UK): Academic Press; 1983.
11. Greulich WW, Pyle SI. Radiographic Atlas of Skeletal Development of Hand and Wrist. Stanford (CA): Stanford University Press; 1959.
12. Ruf S, Pancherz H. When is the ideal period for Herbst therapy - early or late? *Semin Orthod* 2003; 9: 47-56.
13. Fishman LS. Radiographic evaluation of skeletal maturation. A clinically oriented method based on hand-wrist films. *Angle Orthod* 1982; 52: 88-112.
14. Growth Tek – useful interpretations of facial growth. [Updated: 2001; Accessed 2012 Feb 10]. Available from: [www.growthtek.com](http://www.growthtek.com)
15. Grave KC, Townsend G. Cervical vertebral maturation as a predictor of the adolescent growth spurt. *Aust Orthod J* 2003; 19: 25-32.
16. Chen F, Terada K, Hanada K. A new method of predicting mandibular length increment on the basis of cervical vertebrae. *Angle Orthod* 2004; 74: 630-634.
17. Nestman TS, Marshall SD, Qian F, Holton N, Franciscus RG, Southard TE. Cervical vertebrae maturation method morphologic criteria: Poor reproducibility. *Am J Orthod Dentofacial Orthop* 2011; 140: 182-188.
18. Calfee RP, Sutter M, Steffen JA, Goldfarb CA. Skeletal and chronological ages in American adolescents: current findings in skeletal maturation. *J Child Orthop* 2010; 4: 467-470.
19. Alhadlaq A, Al-Qarni M, Al-Kahtani A, Al-Obaid A. Comparative study between hand-wrist method and cervical vertebral maturation method for evaluation of skeletal maturity in Saudi boys. *Pak Oral Dent J* 2007; 27: 187-192.
20. Mito T, Sato K, Mitani H. Predicting mandibular growth potential with cervical vertebral bone age. *Am J Orthod Dentofacial Orthop* 2003; 124: 173-177.
21. Soegiharto BM, Cunningham SJ, Moles DR. Skeletal maturation in Indonesian and white children assessed with hand-wrist and cervical vertebrae methods. *Am J Orthod Dentofacial Orthop* 2008; 134: 217-226.
22. Uysal T, Ramoglu SI, Basciftci FA, Sari Z. Chronologic age and skeletal maturation of the cervical vertebrae and hand-wrist: Is there a relationship?. *Am J Orthod Dentofacial Orthop* 2006; 130: 622-628.
23. Alkhal HA, Wong RWK, Rabie ABM. Correlation between chronological age, cervical vertebral maturation and Fishman's skeletal maturity indicators in Southern Chinese. *Angle Orthod* 2008; 78: 591-596.
24. Flores-Mir C, Burgess CA, Champney M, Jensen RJ, Pitcher MR, Major PW. Correlation of skeletal maturation stages determined by cervical vertebrae and hand-wrist evaluations. *Angle Orthod* 2006; 76: 1-5.
25. Krailassiri S, Anuwongnukroh N, Dechkunakorn S. Relationships between dental calcification stages and skeletal maturity indicators in Thai individuals. *Angle Orthod* 2002; 72: 155-166.
26. Grave KC, Townsend G. Hand-wrist and cervical vertebral maturation indicators: how can these events be used to time Class II treatments? *Aust Orthod J* 2003; 19: 33-45.
27. Ozer T, Kama JD, Ozer SY. A practical method for determining pubertal growth spurt. *Am J Orthod Dentofacial Orthop* 2006; 130: 131.e1-131.e6.
28. Grippaudo CC, Garcovich DD, Volpe GG, Lajolo CC. Comparative evaluation between cervical vertebral morphology and hand-wrist morphology for skeletal maturation assessment. *Minerva Stomatologica* 2006; 55: 271-276.

## Copyright

Whenever a manuscript contains material (tables, figures, etc.) which is protected by copyright (previously published), it is the obligation of the author to obtain written permission from the holder of the copyright (usually the publisher) to reproduce the material in Saudi Medical Journal. This also applies if the material is the authors own work. Please submit copies of the material from the source in which it was first published.