

# Cytologically diagnosed metastatic small cell lung carcinoma in the mandibular soft tissue

Zafer O. Pektas, DDS, PhD, Omer Gunhan, DDS, PhD.

## ABSTRACT

يعد الورم النقيلي في منطقة الفك العلوي نادر ويشكل نسبة 1% من الأورام الخبيثة. نسلط الضوء هنا على تقييم فعالية الأبرة الشاطفة الدقيقة في تشخيص الورم الرئوي للخلية الصغيرة النقيلية. نستعرض في هذا التقرير حالة مريضة تبلغ من العمر 50 عاماً تعاني من ورم 4x5 سم. تم تقييم النزيف وتورم الضواحك في الجزء الأيسر من اللثة. وقد تم تشخيصها في السابق بورم 8x5 سم في منطقة النقيير الأيسر الرئوي مع انصباب جيبي والذي تم تشخيصه بورم رئوي صغير الخلية. تم استخدام الأبرة الدقيقة الشاطفة في انتفاخ الغشاء المخاطي وظهر الفحص النسيجي ورم رئوي صغير الخلية. كانت الفترة مابين تشخيص الرئة وتطور الورم 6 أشهر. تعد الأبرة الدقيقة الشاطفة فعالة وآمنة في التشخيص عند استخدام الطريقة المناسبة وملائمة لأنسجة الوجه واللثة.

Metastatic tumors to the oral and maxillofacial region are relatively rare, they constitute 1% of all malignant tumors of the oral cavity. The purpose of this case report is to evaluate the efficiency of fine needle aspiration cytology (FNAC) in the diagnosis of metastatic small cell lung carcinoma. A 50-year-old female patient presenting with a 4x5 cm firm, hemorrhagic, tender swelling on the left mandibular bicuspid gingiva was evaluated. Her past medical history revealed a mass measuring 8x5 cm in the left pulmonary hilar area with pleural effusion, which was diagnosed as small cell lung carcinoma. A FNAC was performed to the oral mucosal swelling, and cytological examination revealed metastatic small cell lung carcinoma. The duration between diagnosis of the primary lung and development of metastasis was 6 months. The FNAC is a rapid, non-invasive, and safe diagnostic method when carried out with a proper technique, and proved to be a valuable adjunct to a careful physical and radiological examination of the oromaxillofacial lesions.

*Saudi Med J 2013; Vol. 34 (5): 539-541*

*From the Department of Oral and Maxillofacial Surgery (Pektas), Faculty of Dentistry, Baskent University, and the Department of Pathology (Gunhan), Gulhane Military Medical Academy, Ankara, Turkey.*

*Received 21st January 2013. Accepted 17th March 2013.*

*Address correspondence and reprint request to: Associate Professor Zafer O. Pektas, Baskent University, Adana Medical and Research Center, Kazim Karabekir mah. 37/A, Yuregir 01120, Adana, Turkey. Tel. +90 (322) 32282 82 Ext. 1081. Fax. +90 (322) 3227979. E-mail: opektas@baskent-adn.edu.tr*

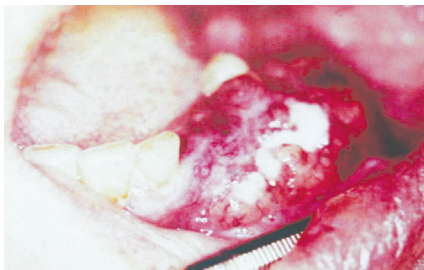
Metastasis of malignant tumors to the oral and maxillofacial region is relatively rare. They constitute approximately 1% of all malignant tumors affecting the oral cavity.<sup>1</sup> These metastases mostly originate from primary cancers of breast in women and from primary cancers of lungs in men.<sup>2</sup> When a malignancy originating from these primary sites metastasizes to the oral and perioral tissues, the disease is usually advanced, and the prognosis is generally poor.<sup>1</sup> Metastatic lesions may rarely be the first manifestation of a malignant tumor. Among several biopsy techniques, fine needle aspiration cytology (FNAC) is gaining popularity in the diagnostic evaluation of neoplastic and non-neoplastic lesions of the oral cavity. Fine needle aspiration cytology has several advantages as a diagnostic modality, as it is a quick, safe, and reliable technique that saves time and money. The present case report describes a metastatic small cell lung carcinoma to the mandible and evaluates the efficiency of FNAC as a diagnostic approach.

**Case Report.** A 50-year-old female patient was referred to the Department of Oral and Maxillofacial Surgery of University of Ankara, School of Dentistry, Ankara, Turkey due to a 4x5 cm firm, hemorrhagic, tender swelling on the left mandibular bicuspid gingiva (Figure 1). Clinical and radiographical examinations did not reveal any serious odontogenic infection apart from periodontitis. The trabecular structure of the maxillofacial region was within normal limits on cranial CT imaging, and a bone scintigraphy with Tc-99m MDP revealed focal accumulation in the right cranial frontal bone and right 7th costal region besides

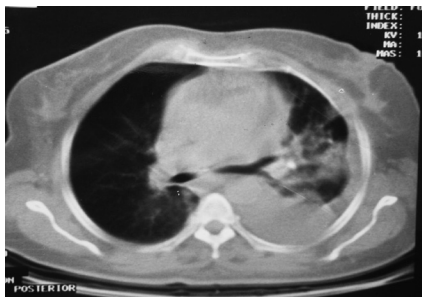
a diffuse accumulation in the mandible. Her past medical history revealed that she had a mass measuring 8x5 cm in the left pulmonary hilar area with pleural effusion 6 months ago (Figure 2). Bronchoscopic biopsy revealed a diagnosis of small cell lung carcinoma. The patient received chemotherapy with a combination of Cisplatin and Etoposide, and later 5000 cGy external radiotherapy. Concerning her medical history, a FNAC was performed on the oral mucosal swelling.

The cytological examination revealed, atypical small epithelial cells showing nuclear molding with reduced

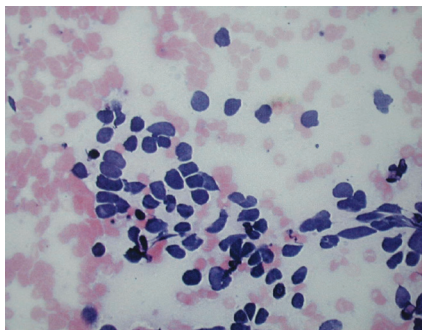
cytoplasm and hyperchromatic nuclei. The tumor was cellular and consisted of spindle-shaped cells. Mitotic configurations were observed in the tumor cells. Also, the spindle-shaped mesenchymal cells were seen on a myxoid base in the hypocellular tumor (Figure 3). The result of FNAC was consistent with metastatic small cell lung carcinoma, similar to the result of the initial bronchoscopic biopsy. Patient was administered chemotherapy again, with the same regimen because of the pulmonary recurrence in one month's time. After a temporary remission, she received 3 sessions of chemotherapy due to a second recurrence. Afterwards, she requested discharge, and unfortunately was lost to follow-up 3 weeks later.



**Figure 1** - Erythematous, hemorrhagic soft tissue mass on the left mandibular bicuspid gingiva.



**Figure 2** - Thoracic CT imaging demonstrating pleural effusion and a 8x5 cm. solid lesion invading the mediastinal vascular structures and left hilar region in left upper pulmonary lobe.



**Figure 3** - Cellular aspirate of the tumor with prominent crush artefact. Atypical, small, epithelial cells showing nuclear molding, with hyperchromatic nuclei and without discernible cytoplasm.

**Discussion.** Metastatic tumors to the jaw bones and oral soft tissues are rarely encountered and represent 1-3% of all malignant tumors affecting the mouth.<sup>1,3</sup> Despite this relatively low incidence, a number of metastatic tumors to oral and maxillofacial tissues from various primary sites have been reported recently by many authors.<sup>4,5</sup> Hirshberg et al<sup>6</sup> reviewed 673 metastatic lesions in the oral cavity, and it was reported that the most common primary sites for oral metastases were the lung, kidney, liver and prostate for men, and breast, female genital organs, kidney, and colo-rectum for women. The distribution of metastases to the oral soft tissues is attached gingiva (54%), tongue (22.5%) and with much less frequency the remaining oral soft tissues.<sup>6</sup> Entrapment of the cells in the rich capillary network of chronically inflamed attached gingiva and fragmented basement membranes of proliferating new capillaries in the inflamed gingiva are considered to be etiological factors for this predisposition.<sup>6</sup> Diagnostic features of metastatic bone disease may not be present in all cases. Thirty-three percent of the patients presents with radiographic findings. Absence of any radiographic change on plain films should not exclude a malignant change and bony involvement of tumors metastatic to the jaws. Bone scintigraphy was proven to be a sensitive method for the detection of lung cancer and its metastases.<sup>7</sup>

Lung carcinomas are characterised by insidious onset (for example, squamous cell carcinoma), difficulty in detection, early metastatic spread (for example; small cell carcinoma) and poor prognosis. They are subdivided into 4 main categories: squamous cell carcinoma; adenocarcinoma; large cell carcinoma; and small cell carcinoma. Small cell carcinomas account for 20-25% of all lung carcinomas, and is defined by its extremely aggressive nature in comparison to the other carcinoma types with a propensity for widespread dissemination

that may account for the metastases found in the head and neck region.<sup>8</sup> The early clinical manifestations of a metastatic lesion may resemble a reactive proliferative lesion such as a pyogenic granuloma, peripheral giant cell granuloma, or a fibrous epulis. Inflammatory processes and metastatic lesions may be both defined by symptoms including pain, localized swelling, periodontitis, hemorrhage, and tooth mobility so the accurate diagnosis often becomes difficult and challenging. Definitive diagnosis of such lesions is mandatory especially in cases of malignancy where it is desirable to begin treatment as early as possible.

From this point of view, the role of FNAC in the diagnostic evaluation of neoplastic and non-neoplastic lesions has increased dramatically as a safe, reliable, cost-effective, and rapid procedure, which can be carried out on an outpatient basis. Elimination of tissue embedding or sectioning with this technique allows a more rapid diagnosis than with surgical biopsy. A conventional surgical biopsy stained with Hematoxylin and Eosin may take one to 7 days for diagnosis, while rapid staining of the slides of the FNAC allows a preliminary diagnosis within a few minutes based on the cytological evaluation of the samples. Apart from the past medical history of the present case and non-specific radiological findings, the unusual clinical appearance of the lesion as an erythematous, ulcerative soft tissue mass, signified a high probability for malignancy. For this reason, FNAC was preferred as a rapid, non-invasive, and safe diagnostic method. Also, definitive cytopathological

diagnosis of present metastatic lesion without a detailed information of the subtype of bronchogenic carcinoma, emphasizes the significance and accuracy of FNAC. As a result, FNAC procedure carried out using a proper technique is a valuable adjunct to a careful physical and radiological examination.

## References

1. Curien R, Moizan H, Gerard E. Gingival metastasis of a bronchogenic adenocarcinoma: report of a case. *Oral Surg Oral Med Oral Pathol Oral Radiol Endod* 2007; 104: e25.
2. van der Waal RI, Buter J, van der Waal I. Oral metastases: review of 24 cases. *Br J Oral Maxillofac Surg* 2003; 41: 3.
3. Thiele OC, Freier K, Bacon C, Flechtenmacher C, Scherfler S, Seeberger R. Craniofacial metastases: a 20-year survey. *J Craniomaxillofac Surg* 2011; 39: 135.
4. Colombo P, Tondulli L, Masci G, Muzza A, Rimassa L, Petrella D, et al. Oral ulcer as an exclusive sign of gastric cancer: report of a rare case. *BMC Cancer* 2005; 19: 117.
5. Sauerborn D, Vidakovic B, Baranovic M, Mahovne I, Danic P, Danic D. Gastric adenocarcinoma metastases to the alveolar mucosa of the mandible: a case report and review of the literature. *J Craniomaxillofac Surg* 2011; 39: 645.
6. Hirshberg A, Shnaiderman-Shapiro A, Kaplan I, Berger R. Metastatic tumours to the oral cavity - pathogenesis and analysis of 673 cases. *Oral Oncol* 2008; 44: 743.
7. Ergün EL, Kara PO, Gedik GK, Kars A, Türker A, Caner B. The role of Tc-99m (V) DMSA scintigraphy in the diagnosis and follow-up of lung cancer lesions. *Ann Nucl Med* 2007; 21: 275.
8. Zachariades N, Koumoura F, Sklavounou-Andrikopoulou A, Papadakis D. Small cell carcinoma metastatic to the mandible. Report of a case. *Int J Oral Maxillofac Surg* 2004; 33: 307.

## Related Articles

Cai JB, Zhang CX, Luo JW, Wang D. A study of <sup>31</sup>Iodine labeling of indomethacin, its in vivo biological distribution in Lewis-bearing lung cancer, and its induction of apoptosis in lung cancer. *Saudi Med J* 2011; 32: 15-22.

Wang YH, Chen DJ, Yi TN, Liu XH. The relationship among human papilloma virus infection, survivin, and p53 gene in lung squamous carcinoma tissue. *Saudi Med J* 2010; 31: 1331-1336.

Xu YH, Zhang GB, Wang JM, Hu HC. B7-H3 and CD133 expression in non-small cell lung cancer and correlation with clinicopathologic factors and prognosis. *Saudi Med J* 2010; 31: 980-986.