

Transpedicular intracorporeal grafting for patients with thoracolumbar burst fractures

Da-Peng Li, MD, PhD, Hui-Lin Yang, MD, PhD, Yong-Hui Huang, MD, PhD, Xiao-Feng Xu, MD, PhD, Tai-Cun Sun, MD, PhD, Lang Hu, MS.

ABSTRACT

الأهداف: تقييم فعالية تعزيز تثبيت قطعة صغيرة مع طعم العظم داخل الجسم في طول الجسم الفقري ومنع فقدان التصحيح في مرضى الكسر العنقودي الصدري القطني.

الطريقة: أجريت دراسة استعادية في المستشفى التابع لجامعة جينغسو، جنغسو، الصين تم علاج 46 مريض الكسر العنقودي الصدري القطني لم يعاني من أي تشوهات عصبية خلال الفترة من يوليو 2008م حتى يونيو 2011م. تم علاج المرضى في المجموعة الأولى بقطعة صغيرة مثبتة للطعم الفقري داخل الجسم بينما المجموعة الثانية تم علاجها بقطعة مثبتة بدون الطعم العظمي. تم تقييم صور الأشعة قبل، وبعد، وفي المتابعة (الأمامية، والمتوسطة، وطول الفقرات الخلفية، وزاوية الحدب الموضعية).

النتائج: انخفضت الفقرات المتكسرة بشكل ملحوظ في جميع المجموعتين، عدد المرضى 46. لم تظهر أي اختلافات إحصائية بين المجموعتين من حيث تحسن طول الجسم وزاوية الحدب الموضعية. لكن، تم ملاحظة فقدان التصحيح في كلا المجموعتين. انخفضت الخسارة في الجسم الأمامي، وطول الجسم المتوسط، وزاوية الحدب الموضعية في المجموعة الأولى بشكل أكثر من المجموعة الثانية. كان معدل الخسارة في المجموعة الأولى أقل بشكل إحصائي من المجموعة الثانية.

خاتمة: أن تعزيز تثبيت قطعة صغيرة مع الطعم الفقري داخل الجسم يعيد طول الجسم الفقري ومنع من فقدان التصحيح لمرضى الكسر العنقودي الصدري القطني.

Objectives: To evaluate the efficacy of reinforcing short-segment fixation with transpedicular intracorporeal grafting in restoring vertebral body height and preventing loss of correction in patients with thoracolumbar burst fractures.

Methods: This retrospective study was carried out from the Affiliated Hospital of Jiangsu University,

Jiangsu, China. Forty-six patients with thoracolumbar burst fractures without neurological deficit were operatively treated between July 2008 and June 2011. Patients in group A (n=21) were treated by short-segment fixation with transpedicular intracorporeal grafting, whereas patients in group B (n=25) were treated by short-segment fixation without bone grafting. The preoperative, postoperative, and follow-up radiographs (anterior, middle, posterior vertebral height, and local kyphosis angle) were evaluated.

Results: All 46 patients in both groups obtained satisfactory reduction of fractured vertebrae. There were no significant differences between the 2 groups according to the improvement of body height and local kyphosis angle. However, correction losses were observed in both groups. Less losses of anterior body height ($p=0.0007$), middle body height ($p<0.0001$), and local kyphosis angle ($p=0.0447$) were detected in group A than group B. The rate of failure in group A (4.8%) was significantly lower than that in group B (28.0%) ($p=0.0383$).

Conclusion: Reinforcement of short-segment fixation with transpedicular intracorporeal grafting can effectively restore vertebral body height and prevent loss of correction for patients with thoracolumbar burst fractures.

Saudi Med J 2014; Vol. 35 (1): 50-55

From the Department of Orthopedic Surgery (Li, Yang, Huang), First Affiliated Hospital of Soochow University, and the Department of Orthopedic Surgery (Li, Huang, Xu, Sun, Hu), Affiliated Hospital of Jiangsu University, Jiangsu Province, China.

Received 4th September 2013. Accepted 25th November 2013.

Address correspondence and reprint request to: Dr. Yong-Hui Huang, Department of Orthopedic Surgery, First Affiliated Hospital of Soochow University, No. 188 Shizi Street, Suzhou 215006, Jiangsu Province, China. Tel. +86 (512) 67899616. Fax. +86 (512) 65113556. E-mail: jbspine123@163.com

Thoracolumbar burst fractures are common spinal injuries in clinical practice. Almost 90% of spinal fractures involve the thoracolumbar region, and approximately 10-20% of such injuries are burst fractures.¹⁻³ Surgical intervention is a more appropriate choice of treatment for thoracolumbar burst fractures, because it can effectively correct kyphotic deformity, provide initial stability, allow early mobilization, and be associated with minimal risk of complications.⁴ Short-segment transpedicular fixation has been a popular method for thoracolumbar fractures since the introduction of pedicle screws.⁵ It provides powerful reduction of vertebral body height and local lordosis, as well as indirect reduction of the intracanal fragment.⁶ Nevertheless, several studies reported unacceptable failure rates of short-segment transpedicular fixation of thoracolumbar burst fractures.^{7,8} Loss of correction and instrumentation breakage is due to failure to support the anterior spinal column.⁹ In 1986, Daniaux¹⁰ first developed the transpedicular bone grafting technique to achieve intrabody fusion. Transpedicular intracorporeal grafting in addition to short-segment fixation maybe a possible solution to prevent failure. However, there is considerable controversy regarding the transpedicular intracorporeal grafting.

In this study, we applied short-segment fixation with/without transpedicular intracorporeal grafting to treat thoracolumbar burst fractures without neurological deficit, and compared the 2 methods to evaluate the efficiency of transpedicular intracorporeal grafting in restoring vertebral height and preventing loss of correction.

Methods. This retrospective case-control study was carried out from the Affiliated Hospital of Jiangsu University, Jiangsu, China. Between July 2008 and June 2011, 79 consecutive patients with thoracolumbar burst fractures were operatively treated in our department. Of these 79 patients, 46 cases were enrolled in our study. Study inclusion was limited to neurologically intact patients in the T11-L2 (AO Type: A3-B2). The other 33 patients were excluded for the following reasons: neurological deficit, 2 or more vertebral fractures, pathological fractures, osteoporotic vertebral fractures, previous lower limb dysfunction, lost to follow-up,

medical disease could not tolerate surgery, and a decision by the surgeon responsible for the patient's care not to include the patients in this study. Loss of anterior vertebral body height exceeding 50%, or sagittal index exceeding 15° was an indication for surgery.

Group A (21 patients) were treated by short-segment pedicle fixation and transpedicular intracorporeal grafting, and group B (25 patients) were treated by short-segment instrumentation without transpedicular grafting. Short-segment pedicle screw (Kanghui Medical Instrument, Changzhou, China) fixation was performed in all 46 patients. Transpedicular intracorporeal grafting was performed similar to that described in our previous study¹¹ for patients in group A. Briefly, the pedicle screws were inserted into the vertebrae above and below the fractured vertebra, then the rods with appropriate length were contoured and connected with the screws. The fractured vertebra was reduced by interbody distractor or compressor. One rod was removed, and the Jack vertebral dilator (Xinrong Best Medical Instrument, Suzhou, China) was placed in the anterior half of the fractured vertebra through the pedicle, then the fractured vertebra was dilated gradually and a cavity was formed (Figure 1). The calcium sulfate pellets (OSTEOSET®PELLET INJECTOR, Wright Medical Technology, Arlington, VA, USA) were injected into the cavity. Then, the rod was reinstalled. Intracorporeal grafting for the other side was carried out in the same fashion. Decompression of the dural sac was not performed in all 46 patients because they all were neurologically intact. All patients were encouraged to walk under the protection of the brace after 6-8 weeks bedrest postoperatively. The fixation was routinely removed in all 46 cases within 12 months after surgery. The preoperative, postoperative, and follow-up radiographs were evaluated. The anterior body height, middle body height, posterior body height, and local kyphosis angle (LKA) were measured according to the methods by several other authors¹²⁻¹⁴ at pre-, postoperatively, and final follow-up. The measurement methods of body height and LKA are shown in Figure 2. The data were compared between the 2 groups. Failure was defined as an increase of $\geq 10^\circ$ in LKA in final follow-up radiographs compared with the measurement in the immediately postoperative radiographs, or implant failure.

The Ethics Committee of the Affiliated Hospital of Jiangsu University approved our study. The protocol of the study adhered to the tenets of the Declaration of Helsinki, and all study participants provided both written and verbal informed consent.

Disclosure. Authors have no conflict of interests, and the work was not supported or funded by any drug company.

Statistical analyses were carried out using the Statistical Package for Social Sciences System Version 16.0 (SPSS Inc., Chicago, IL, USA). Quantitative variables (age, follow-up period, vertebral body height, and LKA) were analyzed using Student's t-test, and categorical variables (gender, fracture level, and failure rate) were analyzed by the χ^2 test. A p -value of <0.05 was considered to indicate statistical significance.

Results. All 46 patients of both groups were followed up. The average age of group A was 38.3 ± 16.2 , and of group B was 37.1 ± 12.0 years. There were 7 males and 14 females in group A, and 12 males and 13 females in group B. The average follow-up of group A was 27.3 ± 11.1 months, and 28.5 ± 10.9 months in group B. In group A, there were 5 fractures in T12, 15 fractures in L1, and one fracture in L2. In group B, there were 2 fractures in T11, 9 fractures in T12, 13 fractures in L1, and one fracture in L2. There were no significant differences between the 2 groups according to age ($p=0.7735$), gender ($p=0.3143$), follow-up period ($p=0.7078$), and distribution of the level of the fractures ($p=0.3978$).

In group A, the average preoperative/postoperative/final follow-up anterior body height was $54.5\%/100\%/97.2\%$, the preoperative/postoperative/final follow-up middle body height was $62.7\%/96.4\%/94.2\%$, and the preoperative/

postoperative/final follow-up posterior body height was $84.9\%/99.9\%/99.9\%$. The average preoperative/postoperative/final follow-up LKA were $20.8^\circ/7.0^\circ/11.4^\circ$. At the final follow-up, the loss of anterior body height was $2.8 \pm 1.3\%$ ($p=0.0365$), and the loss of correction of LKA was $4.4 \pm 0.8^\circ$ ($p<0.0001$). There was no significant loss of middle ($p=0.1096$) and posterior body height ($p=0.9759$) at the final follow-up. In the group B, the average preoperative/postoperative/final follow-up anterior body height was $52.4\%/96.9\%/83.3\%$, the preoperative/postoperative/final follow-up middle body height was $65.6\%/94.6\%/81.6\%$, and the preoperative/postoperative/final follow-up posterior body height was $85.2\%/97.5\%/95.2\%$. The average preoperative/postoperative/final follow-up LKA were $24.6^\circ/10.0^\circ/17.6^\circ$. At the final follow-up, the loss of anterior body height was $13.6 \pm 2.6\%$ ($p<0.0001$), of middle body height was $13.0 \pm 2.0\%$ ($p<0.0001$), and posterior body height was $2.3 \pm 0.9\%$ ($p=0.0183$). The loss of correction of LKA was $7.6 \pm 1.4^\circ$ ($p<0.0001$).

There were no significant differences between the 2 groups according to the preoperative anterior body height ($p=0.4472$), middle body height ($p=0.2528$), posterior body height ($p=0.9140$), and LKA ($p=0.0631$) (Table 1). There were no significant differences between the 2 groups according to the improvement of anterior body height ($p=0.7560$), middle body height

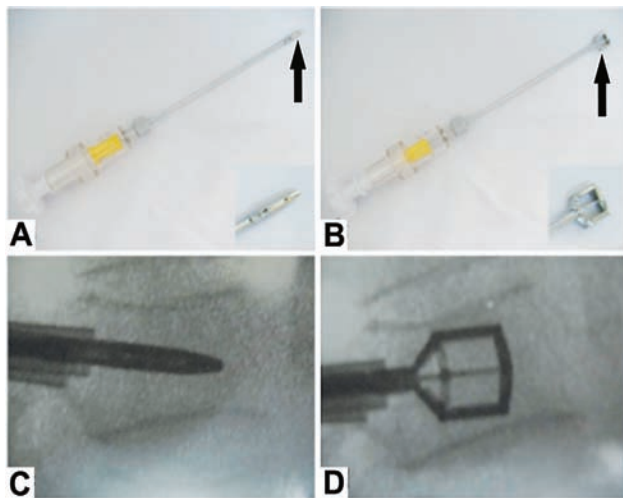


Figure 1 - An image showing: A) closed head (arrow), and B) opened head (arrow) of the Jack vertebral dilator; C) intra-operative image showing that the Jack vertebral dilator was inserted into the fractured vertebra through the pedicle; D) the collapsed upper endplate was reduced and the cavity for bone grafting was performed.

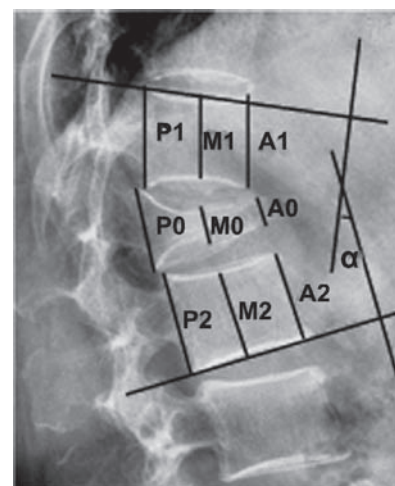


Figure 2 - An image showing the measurement of the vertebral body height and local kyphosis angle. A - anterior body height = $2 \times A0 / (A1 + A2) \times 100\%$, M - middle body height = $2 \times M0 / (M1 + M2) \times 100\%$, P - posterior body height = $2 \times P0 / (P1 + P2) \times 100\%$, α - local kyphosis angle

($p=0.0826$), posterior body height ($p=0.3603$), and LKA ($p=0.6640$). There were no significant differences between the 2 groups according to the loss of posterior body height ($p=0.0708$), whereas there were significant

differences between the 2 groups according to loss of anterior body height ($p=0.0007$), middle body height ($p<0.0001$), and LKA ($p=0.0447$). More details were shown in Table 2 and Figure 3.

Table 1 - Preoperative radiographic parameters in the 2 groups of patients with thoracolumbar burst fractures.

Group	Body height (%)			Local kyphosis angle (°)
	Anterior	Middle	Posterior	
A, n=21	54.5 ± 11.2	62.7 ± 8.2	84.9 ± 10.7	20.8 ± 5.4
B, n=25	52.4 ± 6.2	65.6 ± 8.9	85.2 ± 8.1	24.6 ± 7.5
<i>P</i> -value	0.4472	0.2528	0.9140	0.0631

There were no significant differences between the 2 groups according to the preoperative anterior body height, middle body height, posterior body height, and local kyphosis angle

One patient had a correction loss of $>10^\circ$ (LKA) in group A, with a 4.8% failure rate, whereas 7 patients had a correction loss of $>10^\circ$ (LKA) in group B with a 28% failure rate. One patient had a screw dislodgement accompanied with the biggest correction loss of 31° (LKA) in group B. The difference between the 2 groups according to failure rate was statistically significant ($p=0.0383$). In addition, a bone defect was observed in almost all cases of group B and instant pain disturbed one patient whose MRI indicated the nonunion of fracture after implant removal.

Table 2 - Postoperative and final follow-up radiographic parameters in the 2 groups of patients with thoracolumbar burst fractures.

Group	Anterior body height (%)		Middle body height (%)		Posterior body height (%)		Local kyphosis angle (°)									
	Improved	Lost	Improved	Lost	Improved	Lost	Improved	Lost								
A, n=21	45.5 ± 2.7	<0.0001	2.8 ± 1.3	0.0365	33.8 ± 1.6	<0.0001	2.2 ± 1.3	0.1096	15.0 ± 2.5	<0.0001	0.02 ± 1.3	0.9759	13.8 ± 1.1	<0.0001	4.4 ± 0.8	<0.0001
B, n=25	44.5 ± 2.1	<0.0001	13.6 ± 2.6	<0.0001	29.0 ± 2.1	<0.0001	13.0 ± 2.0	<0.0001	12.2 ± 1.8	<0.0001	2.3 ± 0.9	0.0183	14.6 ± 1.4	<0.0001	7.6 ± 1.4	<0.0001
<i>P</i> -value ^c	0.7560		0.0007		0.0826		<0.0001		0.3603		0.0708		0.6640		0.0447	

P^a - postoperative versus preoperative, *P*^b - final follow-up versus postoperative, *P*^c - group A versus group B

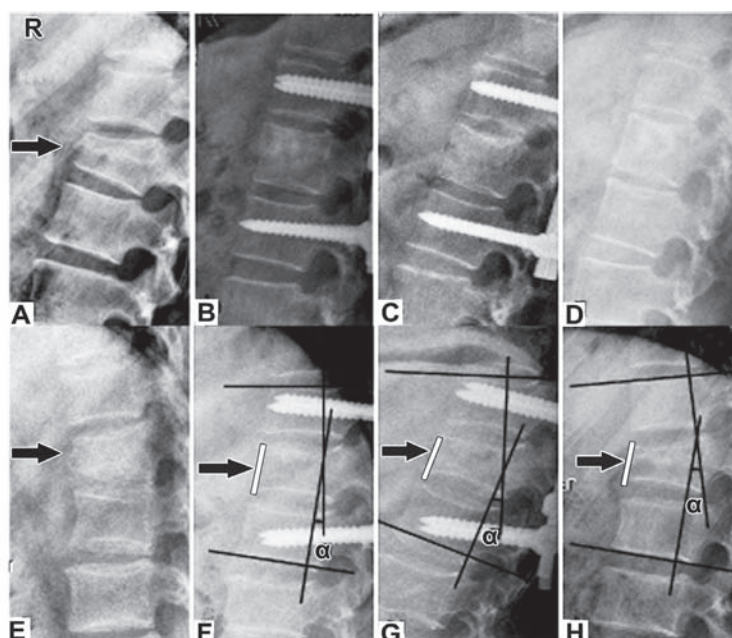


Figure 3 - An image from a 35-year-old male showing: A) preoperative lateral radiograph indicated a burst fracture of L1 (arrow); B) immediate postoperative lateral radiograph demonstrated excellent height restoration; C) lateral radiograph 3 months after surgery; and D) lateral radiograph at final follow-up indicated no loss of correction. An image from a 36-year-old-female showing: E) preoperative lateral radiograph indicated a burst fracture of T11 (arrow); F) immediate postoperative lateral radiograph indicated an excellent restoration of height (white line) and correction of local kyphosis angle (LKA [α]), however, lateral radiograph 3 months after surgery (G) (arrow, white line), and lateral radiograph at final follow-up (H) demonstrated a collapse of fractured vertebra (arrow, white line) and a correction loss of LKA [α].

Discussion. In this study, we compared 2 treatments for thoracolumbar burst fractures without neurological deficit: short-segment pedicle fixation with transpedicular intracorporeal grafting, and short-segment pedicle fixation individually. The findings demonstrated the corrections of fractured vertebrae were satisfactory in both groups, and reinforcement of short-segment fixation with transpedicular intracorporeal grafting can effectively prevent loss of correction for patients with thoracolumbar burst fractures, indicated that transpedicular intracorporeal grafting was a safe and useful spinal surgical technique.

In group B, the failure rate was 28%, which was consistent with several previous reports.^{5,15,16} The losses of anterior body height ($13.6 \pm 2.6\%$), middle body height ($13.0 \pm 2.0\%$), and LKA ($7.6 \pm 1.4^\circ$) were significant. It has been speculated that the large bone defect created inside the fractured vertebra after height restoration was the most important cause of failure.^{16,17} The loss of correction usually occurred within 3 months after surgery. It may be related to increased activity on standing after 6-8 weeks of bedrest. In addition, the intravertebral vacuum located below the upper endplate was observed in almost all patients in group B at final follow-up. So, we predicted that re-fracture, further collapse, and kyphotic deformity would occur due to lack of support to the anterior column of fractured vertebrae.

In group A, there were no losses of correction, but a minimal loss of anterior body height ($2.8 \pm 1.3\%$), and the failure rate was as low as 4.8%. Inconsistent with a previous report,¹⁶ our results suggested that transpedicular intracorporeal grafting could effectively prevent loss of correction and failure of fixation. The possible reasons might be 6-8 weeks bedrest postoperatively, brace protection, and enough support in the anterior column due to sufficient bone grafted into the cavity created by the Jack vertebral dilator. In our series, almost all 46 affected vertebrae could usually be satisfactorily reduced with the posterior pedicle screws fixation. The Jack vertebral dilator we used in the transpedicular intracorporeal grafting procedure in the group A not only plays a role in better fracture reduction, but also creates a cavity of around 4.0-5.0 cc. The cavity enabled the insertion of sufficient grafted bone to ensure anterior column support and fracture healing. The Jack vertebral dilator has such advantages as follows: first, the shape of cavity created by the Jack vertebral dilator is regular so sufficient grafted bone can easily be injected into it.¹⁸ Second, the Jack vertebral dilator can reduce the isolated fracture fragments of

the upper endplate, which usually cannot be reduced by distraction of the transpedicular screws. Therefore, correction of middle body height is 33.8% in group A, whereas it is 29% in group B, though there was no difference ($p=0.0826$) between the 2 groups.

Several other methods were applied to prevent the loss of correction. Cho et al¹⁹ considered that reinforcing short-segment fixation with polymethyl methacrylate vertebroplasty could achieve and maintain kyphosis correction, but incomplete posterior wall of burst fractured vertebra may increase the risk of bone cement leakage. Knop et al²⁰ performed a retrospective study to evaluate the efficiency of posterior short-segment instrumentation combined with intervertebral fusion via transpedicular intervertebral grafting. They considered that the addition of transpedicular intercorporeal grafting did not decrease the loss of correction, and the intervertebral fusion rate was too low (34%) to accept. They thought the unacceptable low fusion rate was related to relatively poor osteogenic potential in the vicinity of the incompletely evacuated intervertebral disc space. The transpedicular intracorporeal bone grafting we applied not only had a good osteogenic environment, but also retained the motion segments. Other authors reconstructed the anterior column through an anterior approach and reported minimal loss of sagittal alignment.²¹⁻²³ However, the anterior approach is technically challenging and interbody fusion reduces the motion segment, though the fractured vertebral body can be exposed clearly for fracture reduction and bone grafting through an anterior approach. In addition, Tezeren et al⁵ thought the long-segment instrumentation was a more effective management than short-segment, whereas the long-segment fixation had prolonged operative time and increased blood loss.

Our study has certain limitations: (1) the small number of patients and short-term follow-up; (2) the lack of measurement of intervertebral disc space; (3) not randomized controlled trials; (4) the lack of comparison with other operative methods; (5) the lack of investigation of clinical outcomes. Talking into account these limitations, we plan to conduct strict research in the future for further elucidation.

In conclusion, on the basis of the current study outcomes, we propose that our approach can be safely applied, and transpedicular intracorporeal bone grafting can effectively prevent loss of correction and failure of short-segment fixation despite the study not being prospective, randomized, or double-blind. We believe that the indication and benefits of this operative method deserve further investigation.

Acknowledgment. The authors gratefully acknowledge Liang-Ju Sheng and Yong Li (Radiologist, Radiology Department, Affiliated Hospital of Jiangsu University, Jiangsu Province, China) for their help during radiograph collection and evaluation. We also thank Tamrakar B. Bhusan (Doctor of Spine Surgery, Institute of Clinical Medicine, Jiangsu University, Jiangsu Province, China) for help in editing this paper.

References

- Dai LY, Jiang SD, Wang XY, Jiang LS. A review of the management of thoracolumbar burst fractures. *Surg Neurol* 2007; 67: 221-231.
- Alpantaki K, Bano A, Pasku D, Mavrogenis AF, Papagelopoulos PJ, Sapkas GS, et al. Thoracolumbar burst fractures: a systematic review of management. *Orthopedics* 2010; 33: 422-429.
- Gnanenthiran SR, Adie S, Harris IA. Nonoperative versus operative treatment for thoracolumbar burst fractures without neurologic deficit: a meta-analysis. *Clin Orthop Relat Res* 2012; 470: 567-577.
- Siebenga J, Lefterink VJ, Segers MJ, Elzinga MJ, Bakker FC, Haarman HJ, et al. Treatment of traumatic thoracolumbar spine fractures: a multicenter prospective randomized study of operative versus nonsurgical treatment. *Spine (Phila Pa 1976)* 2006; 31: 2881-2890.
- Tezeren G, Kuru I. Posterior fixation of thoracolumbar burst fracture: short-segment pedicle fixation versus long-segment instrumentation. *J Spinal Disord Tech* 2005; 18: 485-488.
- Xu BS, Tang TS, Yang HL. Long-term results of thoracolumbar and lumbar burst fractures after short-segment pedicle instrumentation, with special reference to implant failure and correction loss. *Orthop Surg* 2009; 1: 85-93.
- Eno JJ, Chen JL, Mitsunaga MM. Short same-segment fixation of thoracolumbar burst fractures. *Hawaii J Med Public Health* 2012; 71: 19-22.
- Alvine GF, Swain JM, Asher MA, Burton DC. Treatment of thoracolumbar burst fractures with variable screw placement or Isola instrumentation and arthrodesis: case series and literature review. *J Spinal Disord Tech* 2004; 17: 251-264.
- Toyone T, Tanaka T, Kato D, Kaneyama R, Otsuka M. The treatment of acute thoracolumbar burst fractures with transpedicular intracorporeal hydroxyapatite grafting following indirect reduction and pedicle screw fixation: a prospective study. *Spine (Phila Pa 1976)* 2006; 31: E208-214.
- Daniaux H. [Transpedicular repositioning and spongionoplasty in fractures of the vertebral bodies of the lower thoracic and lumbar spine] *Unfallchirurg* 1986; 89: 197-213. German
- Li D, Huang Y, Yang H, Sun T, Wu Y, Li X, et al. Short-segment pedicle instrumentation with transpedicular bone grafting for nonunion of osteoporotic vertebral fractures involving the posterior edge. *Eur J Orthop Surg Traumatol* 2013; 23: 21-26.
- Phillips FM, Ho E, Campbell-Hupp M, McNally T, Todd Wetzel F, Gupta P. Early radiographic and clinical results of balloon kyphoplasty for the treatment of osteoporotic vertebral compression fractures. *Spine (Phila Pa 1976)* 2003; 28: 2260-2265.
- Dong R, Chen L, Gu Y, Han G, Yang H, Tang T, et al. Improvement in respiratory function after vertebroplasty and kyphoplasty. *Int Orthop* 2009; 33: 1689-1694.
- Yung AW, Thng PL. Radiological outcome of short segment posterior stabilisation and fusion in thoracolumbar spine acute fracture. *Ann Acad Med Singapore* 2011; 40: 140-144.
- Li KC, Hsieh CH, Lee CY, Chen TH. Transpedicle body augments: a further step in treating burst fractures. *Clin Orthop Relat Res* 2005; 436: 119-125.
- Alanay A, Acaroglu E, Yazici M, Oznur A, Surat A. Short-segment pedicle instrumentation of thoracolumbar burst fractures: does transpedicular intracorporeal grafting prevent early failure? *Spine (Phila Pa 1976)* 2001; 26: 213-217.
- Ge CM, Wang YR, Jiang SD, Jiang LS. Thoracolumbar burst fractures with a neurological deficit treated with posterior decompression and interlaminar fusion. *Eur Spine J* 2011; 20: 2195-2201.
- Shen GW, Wu NQ, Zhang N, Jin ZS, Xu J, Yin GY. A prospective comparative study of kyphoplasty using the Jack vertebral dilator and balloon kyphoplasty for the treatment of osteoporotic vertebral compression fractures. *J Bone Joint Surg Br* 2010; 92: 1282-1288.
- Cho DY, Lee WY, Sheu PC. Treatment of thoracolumbar burst fractures with polymethyl methacrylate vertebroplasty and short-segment pedicle screw fixation. *Neurosurgery* 2003; 53: 1354-1361.
- Knop C, Fabian HF, Bastian L, Rosenthal H, Lange U, Zdichavsky M, et al. Fate of the transpedicular intervertebral bone graft after posterior stabilisation of thoracolumbar fractures. *Eur Spine J* 2002; 11: 251-257.
- McDonough PW, Davis R, Tribus C, Zdeblick TA. The management of acute thoracolumbar burst fractures with anterior corpectomy and Z-plate fixation. *Spine (Phila Pa 1976)* 2004; 29: 1901-1909.
- Wood KB, Bohn D, Mehbod A. Anterior versus posterior treatment of stable thoracolumbar burst fractures without neurologic deficit: a prospective, randomized study. *J Spinal Disord Tech* 2005; 18s: 15-23.
- Sasso RC, Renkens K, Hanson D, Reilly T, McGuire RA, Best NM. Unstable thoracolumbar burst fractures: anterior-only versus short-segment posterior fixation. *J Spinal Disord Tech* 2006; 19: 242-248.