

The use of ozone in the prevention of osteoradionecrosis of the jaw

Goran Batinjan, DMD, Irina Filipović Zore, PhD, DMD, Marko Vuletić, DMD, Ivana Rupić, DMD.

ABSTRACT

نتج عن العلاج الإشعاعي في منطقة الرأس والعنق آثار عديدة وغير مرغوب فيها على النسيج تجويف الفم. يعد النخر العظمي الإشعاعي المنشأ (ORN) من المضاعفات الأكثر شيوعاً والأكثر خطورة من العلاج الإشعاعي في منطقة الرأس والرقبة وكان الغرض من هذا التقرير هو إثبات إمكانية استخدام الأوزون في الوقاية من ORN من الفك وتظهر البروتوكولات العلاجية الأخيرة لعلاج المرضى من ORN الذين تلقوا العلاج الإشعاعي للرأس والرقبة. خلال فترة العلاج، استخدم جهاز ElektroMagneTron. خضع المريض لامتحانات متابعة ما بعد الجراحة عندما أجري له العلاج الأوكسجيني الحيوي-والتقييم السريري. وأظهر التقييم أن التئام الجروح كان بدون مضاعفات. يعطى العلاج بالأوزون كخيار في البروتوكول العلاجي للوقاية والعلاج من ORN.

Radiation therapy of the head and neck area has resulted in numerous and undesired effects on the oral cavity tissue. The most frequent and most dangerous complications of radiotherapy of the head and neck area is osteoradionecrosis (ORN). The purpose of this study is to demonstrate the possibility of using ozone in the prevention of ORN of the jaw, and show the recent therapeutic protocols for treatment in patients receiving radiation therapy for the head and neck. We used an ElektroMagneTron device during the therapy. The patient underwent postoperative follow-up examination when bio-oxygenation therapy and clinical evaluation of wound healing were performed. Wound healing evaluation showed no complications. Ozone therapy is given as an option in the therapeutic protocol for the prevention and treatment of ORN.

Saudi Med J 2014; Vol. 35 (10): 1260-1263

From the Department of Oral Surgery (Batinjan, Filipović Zore), School of Dental Medicine (Vuletić, Rupić), University of Zagreb, Zagreb, Croatia.

Received 30th January 2014. Accepted 4th June 2014.

Address correspondence and reprint request to: Dr. Goran Batinjan, Department of Oral Surgery, School of Dental Medicine, University of Zagreb, Zagreb, Croatia. E-mail: gbatinjan@sfgz.hr

Radiation therapy in the head and neck area has resulted in numerous and undesired effects on the oral cavity tissue. Side effects in that area are unpleasant for patients, and they are manifested as oral mucositis and loss of taste that usually subsides within a few weeks. Xerostomia may last longer, but patients can receive help as a supportive therapy such as preparations for stimulating saliva creation and artificial saliva. The most frequent and most dangerous complication of radiotherapy of the head and neck area is osteoradionecrosis (ORN).¹ Osteoradionecrosis is a bone exposure in the radiated area that fails to heal within 3 months or less. Due to radiation, the bone becomes acellular, avascular, and hypoxic, and clinical signs were observed: ulceration, necrotic mucosa, and exposure of the necrotic bone accompanied by pain and possible paresthesia. The exposed part of the bone shows visible changes in color and strength, and radiologically a typical loss of bone structure appears and develops into diffuse transparency corresponding to a bone breakdown. Notwithstanding, advances in technology, the treatment of patients with a diagnosis of malignancy in the head and neck area should be a multidisciplinary. Also, the necessary preventative measures can be applied before and after the radiation therapy in reducing the incidence and degree of ORN.² Prevention is a very important part of the comprehensive care of patients who have undergone radiation therapy of the head and neck. Oral prophylaxis of these patients should be performed before, during, and after radiation. Teeth that cannot be repaired should be removed. The optimal time for extraction of teeth is 3 weeks before the start of radiation (no less than 2 weeks), and less optimal extraction should be carried out within 4 months from the completion of radiation.² Patients should be educated on the importance of good oral hygiene and daily fluoridation using custom-made intraoral splints. During radiation therapy, patients should come once a week, and after radiation therapy, once a month during the first 6 months for regular control. After this period, the patient should have a check-up every 4 months.

In such patients, cervical caries are characteristic due to xerostomia, and all carious lesions should be recovered soon to preserve pulp vitality. The extraction of teeth 4 months after the end of radiation is often recommended according to Marx protocol, namely, the treatment in a hyperbaric chamber.² Ozone and soft tissue low-energy laser can be used in the prevention and treatment of ORN. Ozone was used for therapeutic purposes, and its effectiveness is scientifically proven.³ Active oxygen-ozone (a precursor of active oxygen) is one of the most powerful oxidants known and in recent times it has assumed an increasingly important role in dentistry and in oral surgical treatment. A high-frequency current field separates the oxygen molecule into the highly reactive monatomic oxygen that combines with another oxygen molecule and forms ozone. When this process occurs in the oral cavity, active oxygen generated penetrates through the mucus membrane and effectively destroys bacteria in that area. The effect of ozone is multifaceted: it promotes oxygenation of tissues, it is a strong bactericide, fungicide, and virucide, it stimulates the immune response (production of cytokines, interleukin 2, and interferon), and it increases cellular energy by stimulating the Krebs cycle (production of adenosine triphosphate [ATP]).³ In this paper, preliminary results of the bio-oxidative effect of ozone in the prevention of ORN and treatment of post-extraction wounds after serial extraction of all teeth in the upper jaw of a patient at high risk of developing ORN are presented.

Case Report. A 55-year-old man received radiotherapy to the neck and head area between February and April 2012 for the treatment of metastatic planocellular carcinoma in the right lateral neck area, of an unknown primary. The total dose of adjuvant radiotherapy was 79.2 Gy in 30 fractions over 8 weeks. He was a longtime smoker (smoking ≥ 20 cigarettes a day). He came to the Department of Oral Surgery, Faculty of Dentistry 7 months after radiotherapy due to pain and a burning sensation in the mouth while eating. Clinical examination (**Figure 1**) revealed the presence of numerous residual roots in the upper jaw and multiple lesions of inflamed oral mucosa in the lower jaw. At the time of arrival, it was more than 6 months after radiation therapy had ended. The possibility of radiomucositis was ruled out, and it was concluded that he suffered from candidiasis and mucosal damage due to severe xerostomia. Treatment of candidiasis and mucosal lesions was undertaken using miconazole oral gel (20 mg/g) and marshmallow root tea (*Althaeae radix*) for 14 days. Mucosal erythema subsided after the treatment of candidiasis. We performed panoramic x-rays and

vitalometry test. The results revealed that the teeth of the mandible were vital, except tooth 44, and recovery was advised. Further, the upper jaw teeth showed no signs of vitality and the extraction of all maxillary teeth was recommended, which was performed with bio-oxygenation therapy as a measure of preventing ORN. The surgical procedure consisted of several steps. The first step was preoperative ozoning, which reduced the number of bacteria in the operational area to a minimum (GI-gingival probe for 40 seconds). The next step was alveolus ozoning after extraction (AL-alveolar probe and KP-installation probe) (Mymed-Mylius Medizinische GmbH, Töging am Inn, Germany). The entire procedure was completed with ozoning after suturing in order to stimulate circulation and faster healing. During the therapy, an ElektroMagneTron device (Mymed-Mylius Medizinische GmbH, Töging am Inn, Germany) was used.

He underwent postoperative follow-up examinations (on the third, seventh, and fourteenth day after surgery) when bio-oxygenation therapy and clinical evaluation of wound healing were performed. Wound healing evaluation showed that healing was without complications. Healing of the wound was assessed by an experienced surgeon who did not perform the surgical procedures or post surgical therapy. Before the assessment of the degree of wound healing in the patient, the same specialist from oral surgery department assessed 25 wound images of different degrees of wound healing twice in 7 days between the 2 assessments. However, images were presented in different order and properly labeled. The Kappa test revealed no significant difference between the 2 assessments (Kappa value = 0.921), which represents the uniformity of assessments.

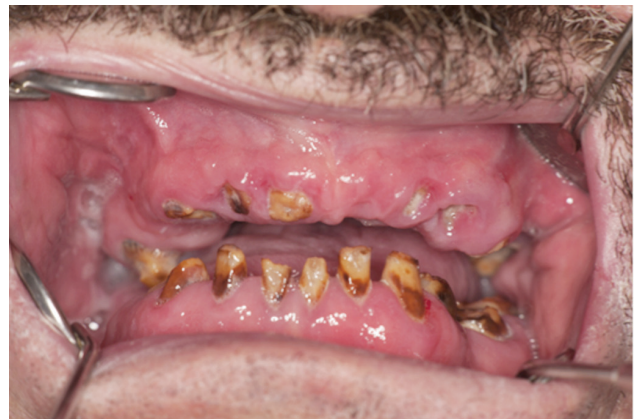

Figure 1 - Clinical picture of the patient during the examination, revealed the presence of numerous residual roots in the upper jaw and multiple lesions of inflamed oral mucosa in the lower jaw.

Assessments were performed on the third, seventh (Figure 2), and fourteenth (Figure 3) postoperative day, using the 4 point scales: 1=normal, 2=acute inflammation, 3=acute inflammation followed by infected alveolus, and 4=alveolar osteitis. The surgeon who assessed the wound swelling had no information on the therapy after the surgical procedure.

Discussion. This case aims to show the positive effect of bio-oxygenation therapy as a possible choice in the prevention of ORN, as it is proven that ozone accelerates the metabolism of bone healing.³ In addition to the patient receiving high doses of radiation, he was also a smoker, an additional predisposing factor for the development of ORN. Periodontal destruction caused by poor oral hygiene and smoking are the major risk factors, and carries the risk for developing ORN.⁴ Vescovi & Nammour,⁵ showed that ozone

can stimulate cell proliferation and cause accelerated healing of soft tissue, which was proven by good results in the prevention and treatment of bone necrosis and post-extraction treatment of the wound. The evaluation of wound healing in control examinations showed no complications. It was found that ozone also shows good results in the treatment of refractory osteomyelitis in the head and neck as adjunctive therapy with antibiotics, surgical therapy, and hyperbaric oxygen therapy. In patients with multiple myeloma who have a high risk of jaw ORN, ozone is also used as an adjunctive therapy with antibiotics and surgical therapy, and the results showed a reduced incidence of ORN. In cases where the ORN developed, lesions were smaller in scale.⁶ Ozone was also shown to be a good therapeutic option in the prevention of osteonecrosis caused by bisphosphonates. Agrillo et al⁷ stated that ozone proved to be an effective postoperative therapy in the prevention of osteonecrosis associated with the use of bisphosphonates. They also stated that the results of research in recent literature showed a reduced success rate of existing protocols in the treatment of osteonecrosis in patients taking bisphosphonates. Due to the poor results of surgical therapy, antibiotics, and hyperbaric oxygen in stopping the pathological processes in such patients, new protocols for the treatment of osteonecrosis associated with bisphosphonates were proposed, which included the use of ozone.⁸

Based on the current understanding of the pathophysiology of ORN, a unique protocol for prevention and treatment should be developed. During the last 80 years, many theories on the pathogenesis of ORN were proposed, which has resulted in different approaches to therapy. Until recently, hypoxia and its consequences were considered the main cause of ORN, which led to the use of hyperbaric oxygen in its prevention and treatment in patients irradiated in the head and neck areas. In previous literature,⁸ we found that the hyperbaric chamber quickly improves oxygenation of the tissues and causes proliferation of blood vessels, fibroblasts, and osteoblasts.⁸ According to recent literature,⁹ many medical institutions very selectively use the hyperbaric chamber as a treatment of choice, thus, there is a substantial need to develop new protocol or an amendment to an existing protocol for the prevention and treatment of ORN. Besides, such therapy is expensive and time-consuming, and often insufficient and contraindicated.⁹ The new theories on the development of ORN focus on bone damage caused by radiation-induced fibrosis, and that damage to bone cells occurs as a result of the interaction of acute inflammation, free radicals, and the chronic

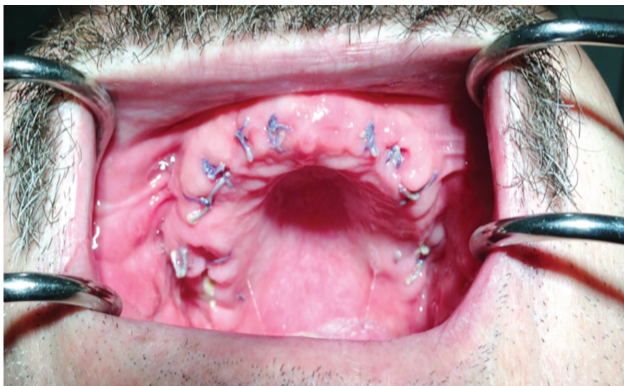


Figure 2 - On the seventh postoperative day, the control and removal of sutures after serial extraction of maxillary teeth using bio-oxygenation therapy.

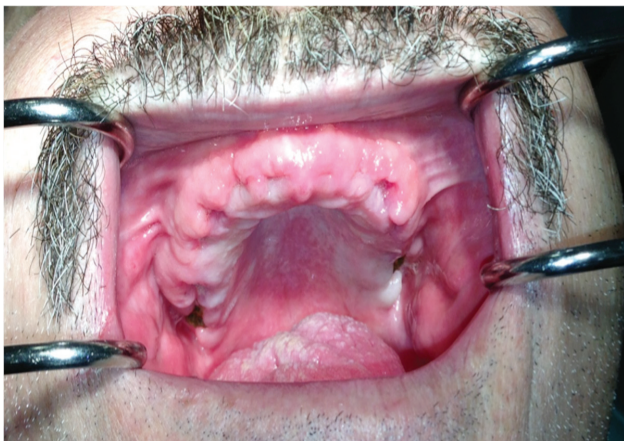

Figure 3 - On the fourteenth postoperative day, the control with the application of bio-oxygenation therapy.

activation of fibroblasts with various growth factors. Pursuant to the new theory, it is recommended that a protocol that includes pentoxifylline, a vasodilator that inhibits fibrosis, and tocopherol (vitamin E) are used to help reduce the harmful effects of free radicals. A very good result was obtained using this protocol, which suggests that this theory and these drugs could be the basis for the treatment and prevention of ORN, and bio-oxygenation therapy certainly finds its place as a supportive therapy in the prevention and treatment of ORN.¹⁰

In conclusion, this case report indicated the positive effect of ozone on multiple post-extraction wound healing and the prevention of ORN in high-risk patients. Prompted by our positive results of the effects of ozone. Future studies with a larger number of clinical cases of patients of which some would receive ozone, while the ORN in the control group would not be treated with ozone should be. On this basis, the optimal protocol for ozone therapy could be defined, which would have a preventive and therapeutic effect on the side effects of radiotherapy and symptoms of ORN.

References

1. Sciubba JJ, Goldenberg D. Oral complications of radiotherapy. *Lancet Oncol* 2006; 7: 175-83.
2. Jacobson AS, Buchbinder D, Hu K, Urken ML. Paradigm shifts in the management of osteoradionecrosis of the mandible. *Oral Oncol* 2010; 46: 795-801.
3. Nogales CG, Ferrari PH, Kantorovich EO, Lage-Marques JL. Ozone therapy in medicine and dentistry. *J Contemp Dental Pract* 2008; 9: 75-84.
4. Katsura K, Sasai K, Sato K, Saito M, Hoshina H, Hayashi T. Relationship between oral health status and development of osteoradionecrosis of the mandible: a retrospective longitudinal study. *Oral Surg Oral Med Oral Pathol Oral Radiol Endod* 2008; 105: 731-738.
5. Vescovi P, Nammour S. Bisphosphonate-related osteonecrosis of the jaw (BRONJ) therapy. A critical review. *Minerva Stomatol* 2010; 59: 181-203, 204-213.
6. Petrucci MT, Gallucci C, Agrillo A, Mustazza MC, Foà R. Role of ozone therapy in the treatment of osteonecrosis of the jaws in multiple myeloma patients. *Haematologica* 2007; 92: 1289-1290.
7. Agrillo A, Sassano P, Rinna C, Priore P, Iannetti G. Ozone therapy in extractive surgery on patients treated with bisphosphonates. *J Craniofac Surg* 2007; 18: 1068-1070.
8. Agrillo A, Petrucci MT, Tedaldi M, Mustazza MC, Marino SM, Gallucci C, et al. New therapeutic protocol in the treatment of avascular necrosis of the jaws. *J Craniofac Surg* 2006; 17: 1080-1083.
9. Peleg M, Lopez EA. The treatment of osteoradionecrosis of the mandible: The case for hyperbaric oxygen and bone graft reconstruction. *J Oral Maxillofac Surg* 2006; 64: 956-960.
10. Lyons A, Ghazali N. Osteoradionecrosis of the jaws: current understanding of its pathophysiology and treatment. *Br J Oral Maxillofac Surg* 2008; 46: 653-660.

Copyright

Whenever a manuscript contains material (tables, figures, etc.) which is protected by copyright (previously published), it is the obligation of the author to obtain written permission from the holder of the copyright (usually the publisher) to reproduce the material in Saudi Medical Journal. This also applies if the material is the authors own work. Please submit copies of the material from the source in which it was first published.