

Clinical Image

Submitted by: Mohamed A. Gornas, MD, Ayman A. El-Mesallamy, MD, Tahir H. Obeid, FRCP, FAAN,

Anas E. Babiker, CSCST Cardiology, MSc Interv. Cardiology.

From the Department of Neurology (Gornas, Obeid), the Department of Radiology (El-Mesallamy), and the Department of Cardiology (Babiker), Alzaytouna Specialist Hospital, Khartoum, Sudan.

Address correspondence to: Prof. Tahir H. Obeid, University of Medical Sciences and Technology, PO Box 12810, Khartoum, Sudan.

Fax. +249 183224799. E-mail: obeidth7@gmail.com

Notice: Authors are encouraged to submit quizzes for possible publication in the Journal. These may be in any specialty, and should approximately follow the format used here (maximum of 2 figures). Please address any submissions to: Editor, Saudi Medical Journal, Prince Sultan Military Medical City, PO Box 7897, Riyadh 11159, Kingdom of Saudi Arabia. Tel. +966 (11) 4777714 Ext. 42841. E-mail: info@smj.org.sa

An adult male with acute paraplegia

Clinical Presentation

A 56-year-old Sudanese male with hypertension for 15 years was admitted to Alzaytouna Specialist Hospital in Khartoum, Sudan in January 2014 with a history of acute paraplegia for 3 hours. He had severe lower thoracic pain radiating to the interscapular area. This was followed by complete weakness of the lower limbs. The weakness worsened rapidly with complete paralysis within 30 minutes. Examination revealed blood pressure of 90/65 mm Hg with pulse 80. He had flaccid paraplegia with a sensory level at T12. Lab investigations including complete blood count, renal profile, coagulation profile, and erythrocyte sedimentation rate were all normal. Urgent MRI of the dorsal region of the spine was normal. Magnetic resonance angiography followed (Figure 1). Diffusion-weighted image (DWI) of the spinal cord revealed an abnormality (Figure 2). We are reporting this case to document the occurrence of this rare problem and to emphasize the significant role of diffusion-weighted images in such situations.

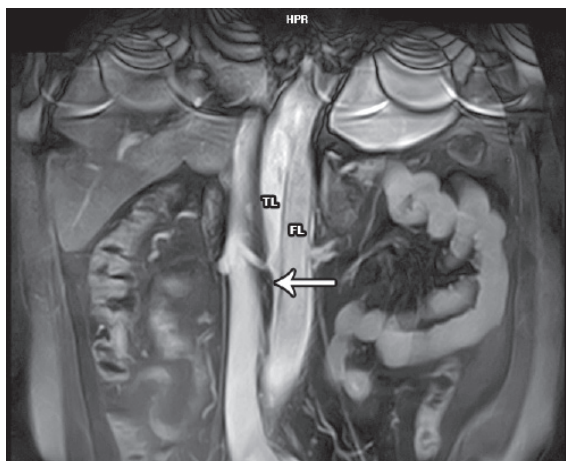


Figure 1 - Magnetic resonance imaging study from the present case of a 56 year-old man.

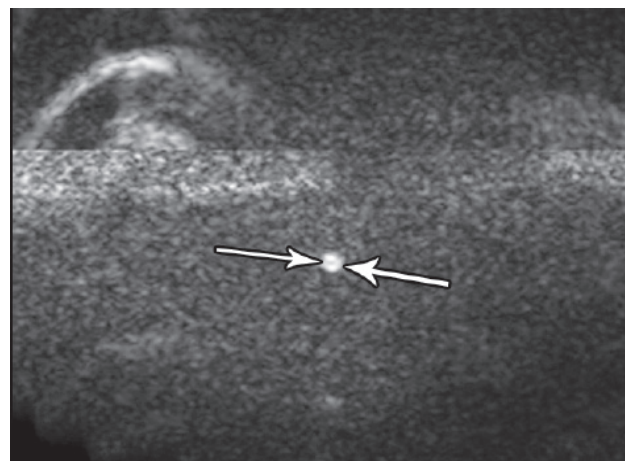


Figure 2 - A diffusion-weighted image of the spinal cord of a 56-year-old man.

Clinical Image

Questions

1. Figure 1 is a magnetic resonant imaging of the patient hours after his first presentation. What does it show?
2. Figure 2 is a diffusion-weighted image of the spinal cord at the level of T12. What does it show?
3. What is your final diagnosis?

Answers

1. Magnetic resonance angiography study from the present case of a 56 year-old man suffering from aortic dissection manifested by the presence of a true lumen and a false lumen separated by an intimal flap (arrow).
2. Diffusion-weighted image of the spinal cord of a 56 year-old man with aortic dissection at the lower cord region opposite to T12 level showing a light bulb signal posteriorly (arrow).
3. Acute ischemic infarct of the cord due to aortic dissection.

Discussion

Neurologic sequelae of aortic dissection (AD) can occur in as many as 17-40% of the patients.¹ This can be explained by the fact that a detailed neurological exam is difficult to obtain in critically ill patients. It is even more misleading as patients can present with painless dissections in 5-15% of the cases.¹ Neurological symptoms of AD were classified into different groups including stroke or transient ischemic attacks, spinal cord ischemia (SCI), ischemic neuropathy, and hypoxic encephalopathy. Whereas SCI in patients with AD could be due to obstruction of the arteries supplying the spinal cord or due to general hypotension.

While DWI has been proven as the most sensitive modality for the diagnosis of acute cerebral ischemia, it shows the same potential in evaluating spinal cord infarctions as shown in previous case reports.²⁻⁴ Magnetic resonance imaging could be normal in the first hours or days after spinal cord infarction.⁵ This can delay any interventional therapy, which may be of much help to the patient especially when presenting acutely. However, in the first few hours conventional MRI could be normal in some patients as concluded by a few studies.⁵

In our case, a conventional MRI of the patient who presented 6 hours after the onset of symptoms was normal. The sagittal T2 showed no clear abnormality of the cord. The DWI of the cord revealed an abnormal signal at the level of T12. Although T2 images can demonstrate findings of ischemia, they are non-specific and do not differentiate between acute and chronic lesions, and therefore they are considered unreliable. Few reports have compared between diffusion-weighted and T2 images of patients diagnosed with SCI and almost all cases demonstrate a better signal intensity on DWI than on T2 images in the first hours of presentation.^{2,3} As in our case, these reports prove that DWI in the early hours of SCI is the best modality for the diagnosis.

Clinical Image

We emphasize the fact that acute aortic dissection should be considered in the differential diagnosis of acute paraplegia after excluding other more common causes. We postulate that in some cases where SCI was suspected but not documented, is due to the fact that DWI was not carried out. A DWI of the cord would provide additional information for the assessment of ischemic changes and also improve on both sensitivity and specificity of the diagnosis and we recommend that it should be an indispensable part of the MRI protocol.

References

1. Gaul C, Dietrich W, Erbguth FJ. Neurological symptoms in aortic dissection: a challenge for neurologists. *Cerebrovasc Dis* 2008; 26: 1-8.
2. Zhang J, Huan Y, Qian Y, Sun L, Ge Y. Multishot diffusion-weighted imaging features in spinal cord infarction. *J Spinal Disord Tech* 2005; 18: 277-282.
3. Shinoyama M, Takahashi T, Shimizu H, Tominaga T, Suzuki M. Spinal cord infarction demonstrated by diffusion-weighted magnetic resonance imaging. *J Clin Neurosci* 2005; 12: 466-468.
4. Thurnher MM, Bammer R. Diffusion-weighted MR imaging (DWI) in spinal cord ischemia. *Neuroradiology* 2006; 48: 795-801.
5. Fujikawa A, Tsuchiya K, Takeuchi S, Hachiya J. Diffusion-weighted MR imaging in acute spinal cord ischemia. *Eur Radiol* 2004; 14: 2076-2078.

Related Articles

Ahmed AF, Idris AS, Kareem AM, Dawoud TA. Acute toxemic schistosomiasis complicated by acute flaccid paraplegia due to schistosomal myeloradiculopathy in Sudan. *Saudi Med J* 2008; 29: 770-773.

Rajab KE, Issa AA, Das RK, Al-Arabi AN. Paraplegia in a puerperal woman due to spinal metastasis from papillary carcinoma of the thyroid gland. *Saudi Med J* 2005; 26: 985-988.