

# Incidence and diagnostic features of eosinophilic esophagitis in a group of children with dysphagia and gastroesophageal reflux disease

Asaad M. Assiri, FRCP, FRCPC, Anjum Saeed, FCPS.

## ABSTRACT

**الأهداف:** معرفة معدل الحدوث والعلامات التشخيصية لالتهاب المرئي الازينوفيلي في مجموعة من الأطفال المصابين بعثر البلع ومرض الارتجاع المعدي المرئي .

**الطريقة:** صممت هذه الدراسة علي أنها دراسة ذات اثر رجعي لتحليل 229 حالة من الذين أجريت لهم مناظير للجهاز الهضمي العلوي في الفترة من يناير 2009م وحتى يناير 2012م في مستشفى خاص ومن الدرجة الثالثة بالرياض بالمملكة العربية السعودية لمعرفة نسبة المرضى الذين يعانون من التهاب المرئي الازينوفيلي في هذه المجموعة.

**النتائج:** 14 طفل من جملة 229 تم تشخيصهم بالتهاب المرئي الازينوفيلي (عدد الخلايا الازينوفيلي أكثر من 15 لكل حقل الطاقة العالية) ولكن قد تم استبعاد 3 حالات لأمراض مصاحبة 8 منهم كانوا ذكورا و3 إناثا بمتوسط عمر بلغ 8.4 عام (أقل من 18 عام). كان العرض الأساسي عثر البلع وبلية القيء وألم البطن في المنطقة العليا من البطن. وجد تاريخ الإصابة بالحساسية والربو في 40-50% من الأطفال. ووجد الازينوفيلي الطرفية في عدد 4 منهم بنسبة 36.3% مع متوسط (مدى 7-28%). كان الباريوم النقيض غير طبيعي في 3 منهم. وجد الشكل الحلقي المطابق للمرئي في 3 منهم، والسراب الخطي في 2 والتهاب المرئي الحاد إلى المتوسط في 8 منهم. وقد تمت معالجتهم جميعا بالاستيرويد المستنشق عن طريق البلع ما عدا 2 تم إعطاؤهم مبدئيا استيرويدات جهازية.

**خاتمة:** أن التهاب المرئي الازينوفيلي غير نادر الحدوث في الأطفال الذين يعانون من عثر البلع ولا بد من اعتباره واحد من التشخيصات التفريقية للمرضى الذين يعانون من التهاب المريء الارتجاعي.

**Objectives:** To investigate the incidence and diagnostic features of eosinophilic esophagitis (EoE) in a group of children with dysphagia and gastroesophageal reflux disease.

**Methods:** This study was designed as a retrospective case analysis of 229 patients who underwent upper

gastrointestinal endoscopy between January 2009 and January 2012 at a private tertiary care hospital in Riyadh, Saudi Arabia to ascertain the proportion of patients with eosinophilic esophagitis.

**Results:** Out of 229 children, 14 children were diagnosed as EoE (esophageal eosinophil count more than 15/high power field on esophageal biopsies), but 3 children were excluded because of other associated conditions. There were 8 males and 3 females with a mean age of 8.4 years (<18 years). The major presentation was dysphagia followed by vomiting and epigastric pain. History of allergy and bronchial asthma was present in 40-50% of children. Peripheral eosinophilia was present in 36.3% (range 7-28%). Barium contrast was abnormal in 3 children. Typical ringed (circular) appearance of esophagus was found in 3, linear furrowing in 2, and moderate to severe esophagitis in 8 children. All the patients were managed with swallowed inhaled steroids, except 2 patients who were initially given systemic steroids.

**Conclusion:** Eosinophilic esophagitis is not an uncommon manifestation in children with dysphagia, and should be considered as one of the top differential diagnoses in patients with reflux esophagitis.

*Saudi Med J 2014; Vol. 35 (3): 292-297*

*From the Prince Abdullah Bin Khalid Celiac Disease Research Chair (Assiri, Saeed), King Saud University, and Dr. Sulaiman Al-Habib Medical Group (Assiri), Riyadh, Kingdom of Saudi Arabia.*

*Received 5th October 2013. Accepted 28th January 2014.*

*Address correspondence and reprint request to: Dr. Asaad M. Assiri, Pediatric Department, King Khalid University Hospital, King Saud University, Riyadh, Kingdom of Saudi Arabia. Tel. +966 (11) 4671313. E-mail: prof-asaad@hotmail.com*

**Disclosure.** This study was supported by the Deanship of Scientific Research, College of Medicine Research Center, King Saud University, Riyadh, Saudi Arabia.

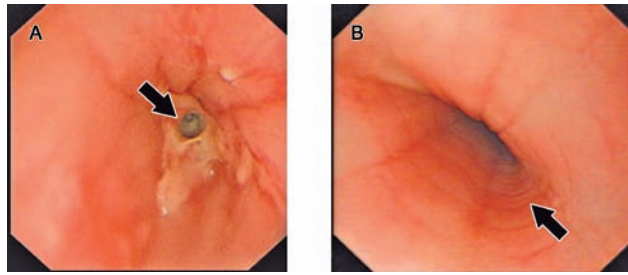
Eosinophilic esophagitis (EoE) is an immune/antigen-mediated inflammatory condition of the esophagus. The first ever description of EoE was reported by Landres et al<sup>1</sup> in the late 1970's as an association with eosinophilic gastroenteritis. It is an emerging and well-recognized disease in children and adults because of the recent better understanding of the biology of eosinophils, their functions, and association with various gastrointestinal disorders.<sup>2</sup> Once considered a rare disorder, this entity is becoming increasingly more recognized, probably due to more awareness among physicians, or due to an actual increase in the incidence.<sup>3</sup> Some studies clearly documented an increase in the incidence rather than more awareness among physicians.<sup>4,5</sup> In most studies, males outnumber females.<sup>6</sup> Continued and persistent exposure of the gastrointestinal tract to various antigens/pathogens, allergens, and food leads to recruitment of eosinophils throughout the GI tract except the esophagus, which is normally devoid of eosinophils.<sup>7</sup> Eosinophilic esophagitis is the infiltration of esophageal mucosa with eosinophils, which contribute to tissue damage and chronic inflammation. Eosinophilic esophagitis is a clinico-pathological disorder, characterized by >15 eosinophils per high power field (HPF) in one or more esophageal biopsies in the absence of gastroesophageal reflux disease (GERD).<sup>8</sup> Infants and children with EoE present with feeding aversion, vomiting, regurgitation, epigastric pain, dysphagia, or food impaction. Older children and adults have more of dysphagia and food impaction with or without central chest pain. There is a strong association with other allergic disorders like bronchial asthma and allergic rhinitis in children with EoE.<sup>9</sup> Although the symptoms are more or less similar to GERD, children with EoE are typically non-responders to anti-reflux medications including high-dose proton pump inhibitors (PPIs). Avoidance of allergens by dietary restriction as well as receiving steroids, either topical or systemic, has shown promising results.<sup>10</sup> We conducted this study to observe the incidence and diagnostic features of EoE in children presenting with dysphagia and GERD-like symptoms.

**Methods.** This study was designed as a retrospective, descriptive, cross-sectional analysis of 229 patients who underwent upper GI endoscopy between January 2009 and January 2012 at a private tertiary care hospital in Riyadh, Saudi Arabia to investigate the proportion of EoE in this group. The data were retrieved from electronic records and files of the patients, and mainly focused on demographic information, frequency

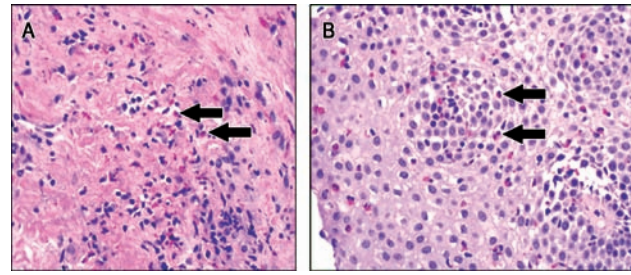
of symptoms, clinical presentation, and diagnostic features differentiating EoE from other mimickers like GERD. These procedures were carried out by a single pediatric gastroenterologist. The children had presented with GERD-like symptoms or dysphagia and were unresponsive to a trial of antireflux medication including prokinetics, antacids, and PPI's for 6-8 weeks. The diagnosis was confirmed as EoE on the basis of endoscopic findings and consistent presence of esophageal eosinophilia (eosinophils >15/HPF) from different areas of the esophagus. After reviewing the full clinical details of all cases, the inclusion criteria for enrolling the children were: age less than 18 years; confirmed EoE with presence of >15/HPF eosinophils on esophageal biopsies; and non-responders to acid suppression therapy or negative pH studies if carried out. We excluded all those patients who had an esophageal eosinophil count <15/HPF, and who had other diseases like eosinophilic gastroenteritis, inflammatory bowel disease, and celiac disease. The major variables analyzed were age, gender, clinical presentation including history of allergy to any food, treatment history, family history, endoscopic findings with esophageal biopsies, pH monitoring if carried out, barium studies, and peripheral eosinophil counts.

Statistical analysis was carried out by using the Statistical Package for Social Sciences version 19 (SPSS Inc., Chicago, IL, USA). Simple descriptive terms were used. Means and standard deviations (SD) were calculated for quantitative variables like age. Frequencies and percentages were calculated for qualitative variables like gender, clinical presentation, endoscopic, and histopathological findings. A *p*-value less than 0.05 was considered significant where applicable. The hospital internal review board and ethical committee approved this study. This study was conducted according to the principles of the Helsinki Declaration.

**Results.** A total of 229 children had undergone evaluation for gastroesophageal reflux-like symptoms, dysphagia, or food impaction and abdominal pain over 3 years. Out of these, 14 children were identified as having EoE, but 3 children were excluded because of having other disorders like celiac disease and eosinophilic gastroenteritis. Therefore, a net total of 11 (4.8%) remaining children were confirmed to have EoE by histopathology; esophageal biopsies showed >15 eosinophils/HPF. There were 8 males and 3 females with a mean age of 8.4 years (range 2-14 years). The major presentation was dysphagia followed by vomiting and epigastric pain. History of allergy to food was



**Figure 1** - Endoscopic evidence of A) eosinophilic stricture at middle part of esophagus, B) ringed appearance.



**Figure 2** - Histopathological findings showing A) stratified squamous epithelium of the esophagus, with infiltration by eosinophils (arrow), and B) the esophageal mucosa is showing infiltration of the lamina propria by eosinophils (arrow) Hematoxylin & Eosin x 40.

**Table 1** - Summary of clinical presentations, barium studies, endoscopic, and histopathological findings among pediatric patients with dysphagia and gastroesophageal reflux disease.

Cases	Age years	Gender	History of allergy/BA	Clinical presentation	Eosinophil count (%)	Barium studies	Endoscopic findings	Histopathology
Case 1	7	M	None	Dysphagia	N	N	Esophagitis with patchy white exudates	Basal cell hyperplasia, eosinophilic microabscesses
Case 2	2	M	BA, allergic rhinitis, allergic to milk and nuts	Abdominal pain, vomiting, FTT	8.8	N	Esophagitis, linear furrowing	Basal cell hyperplasia, eosinophilic microabscesses
Case 3	13	F	Allergic to egg and nuts	Dysphagia, vomiting	7	Abnormal	Esophagitis, ringed appearance	Basal cell hyperplasia
Case 4	12	M	BA, allergic to banana	Dysphagia	N	Abnormal	Esophagitis with patchy white exudates, stricture	Basal cell hyperplasia, eosinophilic microabscesses
Case 5	11	M	None	Food impaction	N	N	Ringed appearance	Basal cell hyperplasia, elongation of lamina propria
Case 6	10	M	BA	Epigastric pain	15	N	N	Basal cell hyperplasia, elongation of lamina propria
Case 7	3	F	BA, allergic to chocolate and nuts	Food impaction, vomiting	28	Abnormal	Esophagitis, linear furrowing, stricture	Basal cell hyperplasia, neutrophil infiltration
Case 8	10	F	None	Dysphagia, food impaction, vomiting	N	N	Esophagitis, ringed appearance	Basal cell hyperplasia, ulceration
Case 9	11	M	None	Dysphagia, vomiting	N	N	Patchy white exudates	Eosinophilic microabscesses, neutrophil infiltration
Case 10	6	M	None	Dysphagia abdominal pain	N	ND	Esophagitis with erythema and few white specks	Basal cell hyperplasia, eosinophilic microabscesses, ulceration
Case 11	14	M	BA, allergic rhinitis	Dysphagia vomiting	6	ND	Esophagitis with white exudates	Eosinophilic microabscesses, neutrophil infiltration

N - normal, BA - bronchial asthma, FTT - failure to thrive, ND - not done

found in 4 (36.3%), bronchial asthma in 5 (45.4%), and allergic rhinitis in 2 (18.1%). None of the children had a positive family history. Physical examination was unremarkable in all the children except one child who had failure to thrive. Peripheral eosinophilia was present in 4 (36.3%) children with a mean of 14.7% (range

7-28%). Barium contrast studies showed narrowing of the mid-esophagus but without any holdup of contrast in 2 children and normal findings in 7 children. Upper GI endoscopy findings of typical ringed (circular) appearance of the esophagus, and strictures are shown in **Figure 1**. One child had a normal endoscopic

examination of esophagus. Eosinophilic infiltration of the esophageal mucosa is shown in **Figure 2**. Other histological features of the esophagus included basal cell hyperplasia, eosinophilic microabscesses, neutrophilic infiltration of the mucosa, elongation of the lamina propria, and ulcerations. All the patients were managed with swallowed inhaled steroids, except 2 patients who were initially given systemic steroids. The clinical summary of these children is shown in **Table 1**. Unfortunately, pH measurements and immunological studies could not be performed in these children because of cost-effectiveness considerations in a private setup.

**Discussion.** The presence of eosinophils in the esophageal mucosa was once considered diagnostic for GERD. The exact prevalence of EoE is unknown in the underdeveloped as well as in the developed world, but a few studies from Western countries have reported it at 40-50/100,000 individuals in the general population.<sup>11</sup> The exact prevalence in Saudi Arabia is not known, but a few case reports, and a clinical study have been published recently.<sup>12,13</sup> Urban populations are more at risk than those in rural areas. It is more common in males for an unknown reason, and affects all age groups.<sup>6,14</sup> This study showed the incidence of EoE to be 4.3% in children who underwent endoscopic procedures for GERD-like symptoms or dysphagia. There was a male predominance (72.7%) among children residing in Riyadh city.

The pathogenesis of EoE is not well understood, but there is an interplay between genetic and environmental factors in this disorder. Eosinophil recruitment in the gastrointestinal tract results from various mechanisms including inflammation, infections, gastroesophageal reflux, and food allergy.<sup>15</sup> There has been a strong association between EoE and food allergy.<sup>16</sup> Although many studies showed a higher incidence of allergic phenomena in these children, this study documented bronchial asthma in 45.5%, and allergy to multiple food items in 36.3%.

The presentation of EoE is variable in different age groups. Infants and toddlers may have refusal to feed, vomiting, or choking on food.<sup>10,11,17</sup> This study revealed that infants and toddlers presented with failure to thrive, vomiting, and food impaction. Young children present with abdominal pain, dysphagia, and vomiting. Dysphagia and food impaction are the common presentations in adolescents in addition to central chest pain or discomfort. The diagnosis of EoE should be considered in non-responders to acid suppression medication for reflux-like symptoms.<sup>12,18</sup>

Physical examination is typically unremarkable except in patients with failure to thrive in early childhood.<sup>19</sup> The current study showed relatively older children having dysphagia, vomiting, and solid food impaction as the primary presentations in concordance with other studies.

The diagnosis of EoE rests mainly on the clinical manifestations, esophageal mucosal appearance on upper GI endoscopy, and histological findings of more than 15 eosinophils/HPF in the esophageal mucosa from distal as well as proximal areas. Patients with clinical symptoms including feeding dysfunction, abdominal pain, vomiting, dysphagia, and impaction of a food bolus need further evaluation to rule out GERD either with pH measurement or an empiric trial of high-dose of PPIs.<sup>20</sup> Our patients had clinical presentations of dysphagia/impaction and/or GERD-like symptoms with classical endoscopic findings including ringed appearance, furrowing, and moderate to severe esophagitis, and a range of findings on esophageal biopsies similar to other studies in the literature.<sup>21</sup> A normal endoscopic appearance does not rule out EoE.

Barium contrast study may also be helpful in delineating strictures due to EoE.<sup>22</sup> The current practice of using endoscopic ultrasound to determine the thickness of the esophageal wall may also be an added advantage in the diagnosis.<sup>23</sup> Blood tests include total IgE level, which is usually elevated in 50-60% of patients with EoE.<sup>24</sup> Presence of peripheral eosinophilia, which is usually mild also supports EoE, and is evident in around 40-50% of patients.<sup>25</sup> The present study showed peripheral eosinophilia in approximately 36.3% of children. Assessment by an allergist/ immunologist is also suggested because of the strong association with allergies.

The optimal treatment for EoE has still not been defined, but there are certain areas that need to be addressed in this condition. Avoidance of triggering and offending food allergens with pharmacological intervention is the mainstay of management. An elemental diet has a good remission rate, but recurrence of symptoms is often seen with normal diet ingestion.<sup>26</sup> This mode of treatment was not tried in any of our patients. Swallowed inhaled steroids either fluticasone or beclomethasone have been effective in ameliorating the symptoms and prevention of complications.<sup>27</sup> All our patients were treated with high dose swallowed inhaled steroids at the start of therapy, and later were maintained on a low dose with good response. Systemic steroids, which used to be the drug of choice for these

children are seldom given these days because of their toxicity. Two of our patients were given systemic steroids because of concurrent exacerbations of bronchial asthma. Leukotriene inhibitors and biological agents like mepolizumab are other medical measures in use for EoE.<sup>28</sup> Esophageal strictures often require mechanical dilatation despite patients being managed with diet and topical steroids. Two of our patients required esophageal dilatation with pneumatic balloon dilators with good results.

Limitations of our study include the fact that it is retrospective; therefore, the potential effect of missing data could not be ruled out. This is a single center experience, so the results may not be generalizable to other settings. Children were diagnosed to have EoE among a group of children with dysphagia and GERD. Further prospective, randomized controlled studies are warranted to look for natural history, clinical presentation, and diagnostic tools to manage this emerging disease in the pediatric age group more effectively.

In conclusion, although our study needs further validation, it provides a solid foundation that eosinophilic esophagitis is an emerging disease in children and adolescents and should be considered as one of the top differential diagnoses in patients with gastroesophageal reflux-like symptoms in older children with dysphagia and food impaction.

## References

- Landres RT, Kuster GG, Strum WB. Eosinophilic esophagitis in a patient with vigorous achalasia. *Gastroenterology* 1978; 74: 1298-1301.
- Prasad GA, Alexander JA, Schleck CD, Zinsmeister AR, Smyrk TC, Elias RM, et al. Epidemiology of eosinophilic esophagitis over three decades in Olmsted County, Minnesota. *Clin Gastroenterol Hepatol* 2009; 7: 1055-1061.
- Kapel RC, Miller JK, Torres C, Aksoy S, Lash R, Katzka DA. Eosinophilic esophagitis: a prevalent disease in the United States that affects all age groups. *Gastroenterology* 2008; 134: 1316-1321.
- Liacouras CA, Furuta GT, Hirano I, Atkins D, Attwood SE, Bonis PA, et al. Eosinophilic esophagitis: updated consensus recommendations for children and adults. *J Allergy Clin Immunol* 2011; 128: 3-20.
- Vanderheyden AD, Petras RE, DeYoung BR, Mitros FA. Emerging eosinophilic (allergic) esophagitis: increased incidence or increased recognition? *Arch Pathol Lab Med* 2007; 131: 777-779.
- Liacouras CA, Spergel JM, Ruchelli E, Verma R, Mascarenhas M, Semeao E, et al. Eosinophilic esophagitis: a 10-year experience in 381 children. *Clin Gastroenterol Hepatol* 2005; 3: 1198-1206.
- Furuta GT, Liacouras CA, Collins MH, Gupta SK, Justinich C, Putnam PE, et al. Eosinophilic esophagitis in children and adults: a systematic review and consensus recommendations for diagnosis and treatment. *Gastroenterology* 2007; 133: 1342-1363.
- Dellon ES, Aderoju A, Woosley JT, Sandler RS, Shaheen NJ. Variability in diagnostic criteria for eosinophilic esophagitis: a systematic review. *Am J Gastroenterol* 2007; 102: 2300-2313.
- Assa'ad AH, Putnam PE, Collins MH, Akers RM, Jameson SC, Kirby CL, et al. Pediatric patients with eosinophilic esophagitis: an 8-year follow-up. *J Allergy Clin Immunol* 2007; 119: 731-738.
- Konikoff MR, Noel RJ, Blanchard C, Kirby C, Jameson SC, Buckmeier BK, et al. A randomized, double-blind, placebo-controlled trial of fluticasone propionate for pediatric eosinophilic esophagitis. *Gastroenterology* 2006; 131: 1381-1391.
- Gill R, Durst P, Rewalt M, Elitsur Y. Eosinophilic esophagitis disease in children from West Virginia: a review of the last decade (1995-2004). *Am J Gastroenterol* 2007; 102: 2281-2285.
- Saadah OI, Aburiziza AJ, Abu Shakra RI. Eosinophilic esophagitis in children from Western Saudi Arabia: relative frequency, clinical, pathological, endoscopic, and immunological study. *Gastroenterol Res Pract* 2012; 2012: 328253.
- Hasosah MY, Sukkar GA, Alshahafi AF, Thabit AO, Fakeeh ME, Al-Zahrani DM, et al. Eosinophilic esophagitis in Saudi children: symptoms, histology and endoscopy results. *Saudi J Gastroenterol* 2011; 17: 119-123.
- Kapel RC, Miller JK, Torres C, Aksoy S, Lash R, Katzka DA, et al. Eosinophilic esophagitis: a prevalent disease in the United States that affects all age groups. *Gastroenterol* 2008; 134: 1316-1321.
- Zhu X, Wang M, Mayi P, Rayapudi M, Pandey AK, Kaul A, et al. Interleukin-15 expression is increased in human eosinophilic esophagitis and mediates pathogenesis in mice. *Gastroenterology* 2010; 139: 182-193.
- Rothenberg ME. Biology and treatment of eosinophilic esophagitis. *Gastroenterology* 2009; 137: 1238-1249.
- Rodrigues M, D'Amico MF, Patiño FR, Barbieri D, Damião AO, Sipahy AM. Clinical manifestations, treatment, and outcomes of children and adolescents with eosinophilic esophagitis. *J Pediatr (Rio J)* 2013; 89: 197-203.
- Iwanczak B, Janczyk W, Ryzko J, Banaszkiwicz A, Radzikowski A, Jarocka-Cyrta E, et al. Eosinophilic esophagitis in children: frequency, clinical manifestations, endoscopic findings, and seasonal distribution. *Adv Med Sci* 2011; 56: 151-157.
- Hruz P, Straumann A, Bussmann C, Heer P, Simon HU, Zwahlen M, et al. Escalating incidence of eosinophilic esophagitis: a 20-year prospective, population-based study in Olten County, Switzerland. *J Allergy Clin Immunol* 2011; 128: 1349-1350.
- Noel RJ, Putnam PE, Rothenberg ME. Eosinophilic esophagitis. *N Engl J Med* 2004; 351: 940-941.
- Cury EK, Schraibman V, Faintuch S. Eosinophilic infiltration of the esophagus: gastroesophageal reflux versus eosinophilic esophagitis in children--discussion on daily practice. *J Pediatr Surg* 2004; 39: e4-7.
- Binkoyitz LA, Lorenz EA, Di Lorenzo C, Kahwash S. Pediatric eosinophilic esophagitis: radiological findings with pathologic correlation. *Pediatr Radiol* 2010; 40: 714-719.

23. Dalby K, Nielsen RG, Kruse-Andersen S, Fenger C, Durup J, Husby S. Gastroesophageal reflux disease and eosinophilic esophagitis in infants and children. A study of esophageal pH, multiple intraluminal impedance and endoscopic ultrasound. *Scand J Gastroenterol* 2010; 45: 1029-1035.
24. Erwin EA, James HR, Gutekunst HM, Russo JM, Kelleher KJ, Platts-Mills TA, et al. Serum IgE measurement and detection of food allergy in pediatric patients with eosinophilic esophagitis. *Ann Allergy Asthma Immunol* 2010; 104: 496-502.
25. Aceves SS, Newbury RO, Dohil R, Schwimmer J, Bastian JF, et al. Distinguishing eosinophilic esophagitis in pediatric patients: clinical, endoscopic, and histological features of an emerging disorder. *J Clin Gastroenterol* 2007; 41: 252-256.
26. Schaefer ET, Fitzgerald JF, Molleston JP, Croffie JM, Pfefferkorn MD, Corkins MR, et al. Comparison of oral prednisone and topical fluticasone in the treatment of eosinophilic esophagitis: a randomized trial in children. *Clin Gastroenterol Hepatol* 2008; 6: 165-173.
27. Konikoff MR, Noel RJ, Blanchard C, Kirby C, Jameson SC, Buckmeier BK, et al. A randomized, double-blind, placebo-controlled trial of fluticasone propionate for pediatric eosinophilic esophagitis. *Gastroenterology* 2006; 131: 1381-1391.
28. Attwood SE, Lewis CJ, Bronder CS, Morris CD, Armstrong GR, Whittam J. Eosinophilic oesophagitis: a novel treatment using Montelukast. *Gut* 2003; 52: 181-185.

#### Related Articles

Sarkhy AA. Gastroesophageal reflux disease in infants. Myths and misconceptions, where is the evidence? *Saudi Med J* 2012; 33: 593-600.

Makhadoom N, Abouloyoun A, Bokhary HA, Dhafar KO, Gazzaz ZJ, Azab BA. Prevalence of gastroesophageal reflux disease in patients with laryngeal and voice disorders. *Saudi Med J* 2007; 28: 1068-1071.

Somi MH, Farhang S, Mirinezhad K, Jazayeri E, Nasseri-Moghaddam S, Moayeri S, et al. Prevalence and precipitating factors of gastroesophageal reflux disease in a young population of Tabriz, Northwest of Iran. *Saudi Med J* 2006; 27: 1878-1881.