

Minimally invasive endoscopic removal of a massive trabecular juvenile ossifying fibroma of the paranasal sinuses

Osama A. Marglani, MD, FRCSC, Mohammed Y. Kassab, MD, FRCS(Ed), Syed A. Raza, MBBS, MS.

ABSTRACT

في هذه الحالة المريضة تبلغ فتاة من العمر 11 عاماً تشكو من انسداد الأنف من الناحية اليسرى وجحوظ للعين اليسرى للأعلى لمدة 3 أشهر. وكشف الفحص السريري كتلة قاسية في تجويف الأنف اليسرى. وأظهر التصوير المقطعي وجود ورم ضخم على الجيب الفكّي اليسار مع تمدد في الجيب الغربالي، وضغطاً تجويف العين اليسرى. وكشف فحص الأنسجة وجود ورم ليفي تربقي تعظمي الذي أزيل عن طريق الجراحة بالمنظار من قبل فريق طبي مكون من جراحي المخ والأعصاب وقاعدة الجمجمة وجراحي أمراض الأذن الأنف الحنجرة وقد تحمل المريض العملية المطولة بشكل جيد ولا يوجد عودة للورم بعد التدخل الجراحي كما أن الورم استأصل تماماً. لم يكن هناك أي ندبات خارجية أو عواقب نفسية.

An 11-year-old female patient presented with left-sided nasal obstruction and upward displacement of the left eye of 3 months duration. Clinical examination revealed a firm mass in the left nasal cavity. A CT scan showed a massive tumor involving the left maxillary sinus with extension into the ethmoid sinus, and encroaching on the left orbit. Histopathological examination revealed trabecular juvenile ossifying fibroma, which was removed via a transnasal endoscopic surgery by the Otorhinolaryngology, Head and Neck and the skull base team. She tolerated the lengthy procedure well, and there was no recurrence postoperatively as the tumor was resected completely. There was no external scarring and no psychological trauma discerned.

Saudi Med J 2014; Vol. 35 (8): 872-875

From the Department of Otolaryngology-Head & Neck Surgery, (Marglani, Raza), the Department of Neurosurgery (Kassab), King Abdullah Medical City, and the Department of Otolaryngology-Head & Neck Surgery, (Marglani), Umm Al-Qura University, Makkah, Kingdom of Saudi Arabia.

Received 29th January 2014. Accepted 27th May 2014.

Address correspondence and re-print request to: Dr. Osama A. Marglani, Associate Professor, Department of Otolaryngology-Head & Neck Surgery, Umm Al-Qura University, King Abdullah Medical City, Makkah, Kingdom of Saudi Arabia. E-mail: marglani1@yahoo.com

Ossifying fibroma (OF) is a benign fibro-osseous lesion that was first described by Menzel in 1872.¹ Juvenile ossifying fibroma (JOF) is an uncommon benign neoplasm of the maxillofacial bones and behaves aggressively. It has a high rate of recurrence ranging from 30-50%, and is commonly seen in patients between 5-15 years of age.² It appears in both genders and can affect any age group.³ The JOF has 2 histological types: psammomatoid (PJOF), which is more common, and trabecular (TrJOF). Seventy-five percent of PJOF usually present in the paranasal sinuses and orbit, and the remaining 25% present in the maxilla and mandible, while 95% of TrJOF present in the jawbones and maxillary sinuses.^{2,3} Clinical symptoms depend on the site of involvement. It is usually asymptomatic until it expands enough to produce symptoms. A definite diagnosis of JOF is made on the basis of histopathology.³ Both CT and MRI scans are of immense importance in ascertaining the extent of the lesion, and also in revealing bony erosion, which is important in preoperative planning and also postoperatively to detect recurrence. Our objective in presenting this particular case is to discuss TrJOF and its management by minimally invasive endoscopic sinus surgery, which offers multiple advantages when compared with other external surgical approaches.

Case Report. An 11-year-old girl presented to the Department of Otorhinolaryngology, Head & Neck surgery, complaining of left-sided nasal obstruction, and a history of double vision of 3 months duration. This was gradual in onset and progressive along with the presence of swelling in the left malar region. There was no history of trauma. Physical examination revealed a mass (Figure 1) in the left nasal cavity, which was firm, fleshy, pink, mobile from side to side and bleed on

Disclosure. Authors have no conflict of interests, and the work was not supported or funded by any drug company.

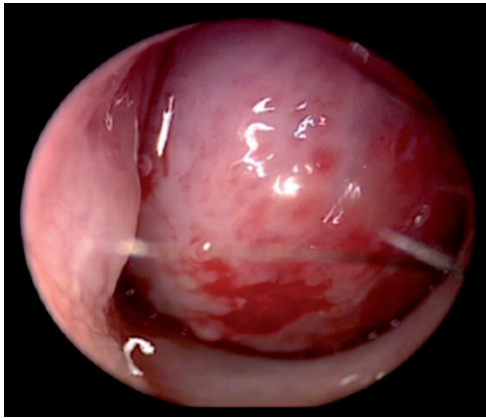


Figure 1 - Firm mass in the nasal cavity.

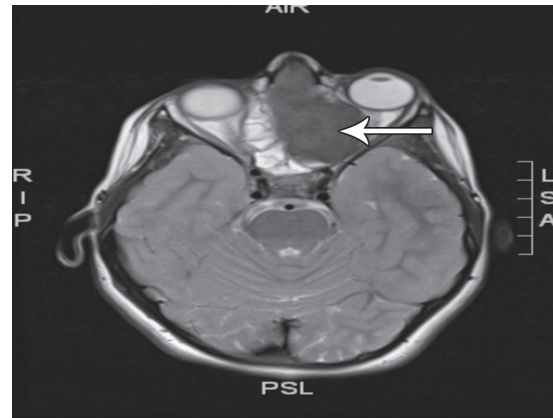


Figure 3 - Axial T2 weighted MRI showing the mass encroaching on the left optic nerve.

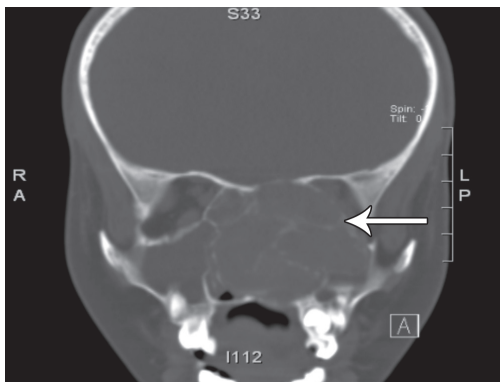

Figure 2 - A coronal CT scan showing mass in the nasal cavity.

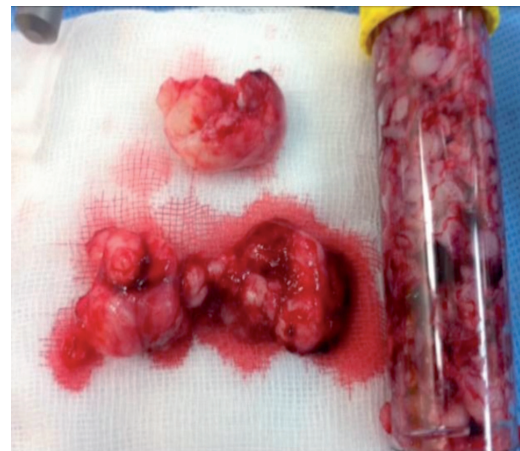


Figure 4 - Postoperative specimen of the nasal mass.

touch. Fullness and expansion of the left malar region were also noted. Her visual acuity was normal, and proptosis was detected on the left side. Nasal endoscopy also demonstrated a fleshy mass in the left nasal cavity; the superior border could not be made out and the scope could not be passed beyond the mass.

A CT scan (Figure 2) of the sinuses showed a large left nasal cavity mass with thinning out and rarefaction of the surrounding bony septa and remodeling of nasal septum and medial wall of the left orbit. The floor of the left cranial fossa was thinned out suggesting a benign lesion. An MRI (Figure 3) of the paranasal sinuses showed a large left nasal cavity mass extending into the left maxillary sinus and left ethmoid air cells with ill-defined bony septa. There was also remodeling and thinning out of the medial orbital wall with encroachment on the left orbit and displacement of the medial rectus muscle and the left optic nerve with no definite infiltration with mild proptosis of the left eye. The possibility of a fibromatous lesion of the nasal cavity was kept in mind.

The ENT and skull base team undertook a transnasal endoscopic piecemeal removal of the mass (Figure 4). Gross examination revealed friable, firm to hard tissue measuring 6x5x5 cm in aggregate. Histopathological examination showed respiratory mucosa with an underlying well-circumscribed tumor; the mass consisted of fibrous proliferation with bland-appearing spindle cells in a collagenous background with minimal atypia and rare mitotic activity. There were foci of ossification and calcification; the pathological diagnosis was TrJOF (Figure 5). She was discharged from hospital the next day, and no recurrence was observed after 9 months of postoperative follow-up (Figure 6).

Discussion. Fibro-osseous diseases are a group of benign lesions that arise more frequently from the maxillofacial bones. The pathophysiology of all benign fibro-osseous lesions (BFOL) is by replacement of

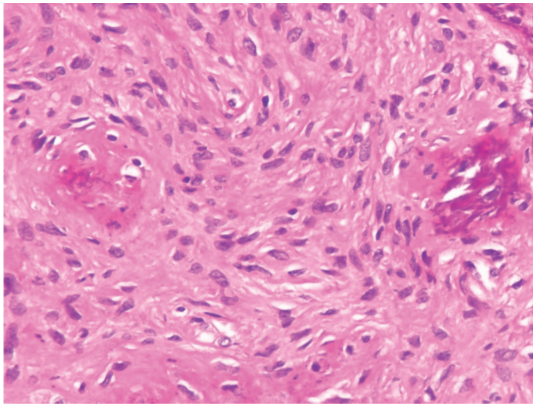


Figure 5 - Histopathology of the lesion showing fibrous proliferation with bland appearing spindle cells in a collagenous background with minimal atypia and rare mitotic activity, which is characteristic of trabecular juvenile ossifying fibroma.

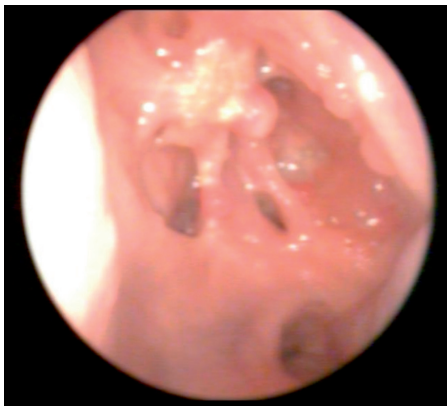

Figure 6 - Post operative follow-up.

the normal bones with fibrous connective tissue with variable amounts of mineralized tissue such as osteoid, mature bone, and cementum-like calcification.³ The incidence of sporadic OFs is 2%.⁴ The differential diagnosis of such sinonasal fibrovascular lesions includes: solitary fibrous tumor, inverted papilloma, angioma, lobular capillary hemangioma, osteoma, OF, and other malignant tumors. Immunohistochemistry and light microscopic features helps in providing evidence for the differential diagnosis.⁵

Ossifying fibromas are considered true BFOLs; they are found mainly in the jawbone especially in molar and premolar regions of the mandible, and originate from the periodontal ligament space.^{3,6} They occur most commonly in females aged between 30-40 years. Ossifying fibromas are usually asymptomatic, and exhibit slow growth, but when the lesion expands it can cause facial asymmetry. Radiographically, the lesion is characterized by a unilocular mass, sharply defined, with

a smooth cortical border. Early lesions are radiolucent, while late lesions are radiopaque with a radiolucent rim.^{6,7}

The JOF has 2 histological types: psammomatoid (PJOF), which is more common, and trabecular (TrJOF). The PJOF is the more common type,⁴ and 75% of PJOF masses arise from the orbit and paranasal sinuses, whereas the rest arises from the maxilla and mandible. Pathologically, PJOF has small uniform spherical ossicles resembling psammoma bodies. The TrJOF is usually distinguished by trabeculae of fibrillary osteoid and woven bone.⁸

Management of OF depends on the size of the mass and if it is symptomatic or asymptomatic. An observation approach for small asymptomatic masses, and surgical excision for large symptomatic masses is adopted.⁹ The management of JOF is complete surgical excision; incomplete surgical excision is associated with a high recurrence rate.⁵ The surgical approaches for removal of the mass depend on the site of the lesion. Different surgical approaches for the removal have been advocated including Caldwell-Luc,¹⁰ transethmoidal, lateral rhinotomy, and endoscopic resection.⁶ In our case, she was managed by a transnasal endoscopic sinus surgery, which enabled us to remove such a large lesion comfortably avoiding a scar and extended hospital stay had we approached the tumor externally.

In conclusion, TrJOF is a rare fibro-osseous tumor with aggressive behavior, of unknown etiology. It occurs mostly in patients younger than 15 years, and the maxilla is the most commonly involved bone. Management of OFs of the nose and paranasal sinuses is challenging. A massive OF of the nasal cavity and maxilla can be treated endoscopically by an expert skull base team, and offers the advantage of cosmesis and thereby avoiding facial disfigurement when compared with radical surgery in children. Additionally, there is no subsequent psychological scarring discerned, normal social interaction, and shorter hospital stay. Combined teamwork is necessary to manage large tumors. Image-guided navigation helps in planning the surgery preoperatively and intraoperatively to avoid injury to vital structures such as the optic nerve and base of the skull.

Acknowledgment. The authors thank Dureen I. Rednah, Dr. Bassem R. Zuraiqi, Dr. Ahmed Sheikh, Dr. Hassan Hawasavi, and Dr. Naif Bawazer for their help in preparing the manuscript.

References

1. Mohsenifar Z, Nouhi S, Abbas FM, Farhadi S, Abedin B. Ossifying fibroma of the ethmoid sinus: Report of a rare case and review of literature. *J Res Med Sci* 2011; 16: 841-847.

2. Guruprasad Y, Giraddi G. Juvenile ossifying fibroma of maxilla. *J Maxillofac Oral Surg* 2010; 9: 96-98.
3. Keles B, Duran M, Uyar Y, Azimov A, Demirkan A, Esen HH. Juvenile ossifying fibroma of the mandible: a case report. *J Oral Maxillofac Res* 2010; 1: 5.
4. Wang TT, Zhang R, Wang L, Chen Y, Dong Q, Li TJ. Two cases of multiple ossifying fibromas in the jaw. *Diagn Pathol* 2014; 9: 75.
5. Lin HL, Huang CC, Lee TJ. Endoscopic sinus surgery treatment for a huge sinonasal fibroma. *Chang Gung Med J* 2004; 27: 233-237.
6. Cury SE, Cury RE, Cury SN, Cury MD, Pontes HA, Pinto Jr D. Trabecular juvenile ossifying fibroma (WHO-type): Case report. *Webmed Central Histopathology* 2013; 4: WMC004228.
7. Slootweg PJ. Maxillofacial fibro-osseous lesions: classification and differential diagnosis. *Semin Diagn Pathol* 1996; 13: 104-112.
8. El-Mofty S. Psammomatoid and trabecular juvenile ossifying fibroma of the craniofacial skeleton: two distinct clinicopathologic entities. *Oral Surg Oral Med Oral Pathol Oral Radiol Endod* 2002; 93: 296-304.
9. Shields JA, Peyster RG, Handler SD, Augsburg JJ, Kapustiak J. Massive juvenile ossifying fibroma of maxillary sinus with orbital involvement. *Br J Ophthalmol* 1985; 69: 392-395.
10. Abuzinada S, Alyamani A. Management of juvenile ossifying fibromas. *J Maxillofac Oral Surgery* 2010; 9: 91-95.

Related Articles

Aljfout QM, Tubeishi KA, Al-Assaf SM, Alnawaiseh ST. Computed tomography scan of rhinosinusitis, current practice, and requirements for endoscopic surgery of paranasal sinuses. *Saudi Med J* 2011; 32: 32-35.

Al-Sindi K, Al-Shehabi MH, Al-Khalifa SA. Inflammatory myofibroblastic tumor of paranasal sinuses. *Saudi Med J* 2007; 28: 623-627.