

Is systemic infliximab therapy effective for retinal cavernous hemangioma?

Sulaiman M. Alsulaiman, MD, Marwan A. Abouammoh, MD, Saad A. Al-Dahmash, MD, Ahmed M. Abu El-Asrar, MD, PhD.

ABSTRACT

تم تشخيص طفلة رضية تبلغ من العمر 10 أشهر كحالة ورم وعائي كهفي شبكي يشمل اللطخة الصفراء بعدما لاحظ الأبوان انحراف العين اليمنى إلى الخارج. الفحص السريري كشف عن وجود نزيف زجاجي متبدد، وعناقيد شبيهة بالعنب وممتلئة بالدم في قاع العين. بعد 4 دورات من العلاج بعقار الإنفليكسيماب عبر الوريد على مدى 3 أشهر، لم نلاحظ أي تغيير يذكر في حجم الورم الوعائي الكهفي.

A 10-month-old infant with the diagnosis of retinal cavernous hemangioma involving the macula presented with an outward deviation of the right eye that has been noticed by her parents. Examination revealed a clearing vitreous hemorrhage, and grape-like clusters filled with blood in the posterior pole. After 4 cycles of intravenous infliximab over the period of 3 months, no evident change was noted on the size of the cavernous hemangioma.

Saudi Med J 2014; Vol. 35 (9): 1127-1130

From the Department of Ophthalmology, College of Medicine, King Saud University, Riyadh, Kingdom of Saudi Arabia.

Received 6th February 2014. Accepted 23rd June 2014.

Address correspondence and reprint request to: Dr. Marwan A. Abouammoh, Department of Ophthalmology, College of Medicine, King Saud University, PO Box 245, Riyadh 11411, Kingdom of Saudi Arabia. Fax: +966 (11) 4775724. E-mail: dr.abouammoh@gmail.com

Cavernous hemangioma of the retina and optic disc is a rare vascular hamartoma characterized by clusters of thin-walled saccular aneurysms filled with dark blood resembling a bunch of grapes. It may be isolated or associated with skin and central nervous system (CNS) hemangiomas as part of neuro-oculo-cutaneous syndrome. Cavernous hemangiomas are believed to be present from birth, but the average age at diagnosis is

23 years. It is more common in females and usually unilateral. Patients with this condition are usually asymptomatic and diagnosed incidentally. Visual loss may be the result of vitreous hemorrhage, epimacular membrane or macular location of the tumor.¹⁻³ Here we report a rare presentation of a 10-month-old girl with retinal cavernous hemangioma involving the macula for which she received systemic infliximab therapy. The aim of this study is to distinguish cavernous hemangioma presenting in infancy from other retinal vascular abnormalities.

Case Report. A 10-month-old girl was referred to the ophthalmic emergency room at King Abdulaziz University Hospital, Riyadh, Kingdom of Saudi Arabia as a case of vitreous hemorrhage in the right eye for further management. Her parents noticed an outward deviation of her right eye for the last 5 weeks. The parents denied any history of ocular or head trauma and there was no history of systemic disease. Ophthalmic examination revealed a right exotropia measuring 30 prism diopters. The vision in the right eye was central, steady, and unmaintained and she resisted occlusion of the left eye. Extra-ocular muscle movements were full. Portable slit-lamp examination of the anterior segment was within normal limits except for mild subconjunctival hemorrhage in the right eye which was thought to be secondary to examination under sedation in a previous hospital. Fundus examination of the right eye showed old vitreous hemorrhage covering the macula. There were small saccular dilatations filled with dark blood involving the macula possibly representing cavernous hemangioma of the retina. Slit-lamp and

Disclosure. This work was partly supported by the Dr. Nasser Al-Rasheed Chair in Ophthalmology, King Saud University, Riyadh, Kingdom of Saudi Arabia.

fundus examination of the left eye was within normal limits. However, she was admitted to rule out the possibility of child abuse.

General physical examination was within normal limits and the blood work-up did not show any evidence of bleeding disorders. Brain magnetic resonance imaging was unremarkable with no evidence of subdural hemorrhage or findings suggestive of CNS vascular malformation. Bone survey was within normal limits. Ultrasonography of the right eye showed a dome shaped lesion in the macula that measured 2.5mm in elevation, 8x9.5 mm in diameter with vitreous hemorrhage emanating from its surface (Figure 1). A scan revealed high regular internal reflectivity (Figure 2). Fundus fluorescein angiography showed delayed filling

in the venous phase and lack of leakage in the late phase (Figure 3). The diagnosis of cavernous hemangioma of the retina was made. Examination after one month showed that the vitreous hemorrhage began to clear, so amblyopia therapy was initiated. Three months later, examination under sedation revealed a mass in the macular area, composed of grape-like saccular dilatations of thin-walled blood vessels with adjacent retinal blood vessels of normal caliber. There was a grey-white fibrotic tissue over the tumor (Figure 4) with remarkable lack of exudation. She then received 4 cycles of systemic infliximab therapy (infusion of 5mg/kg over 2 hours) at weeks 0, 2, 6, and 8 weeks. Examination at one month after the last dose revealed no apparent decrease in the size of the tumor. Six months after the

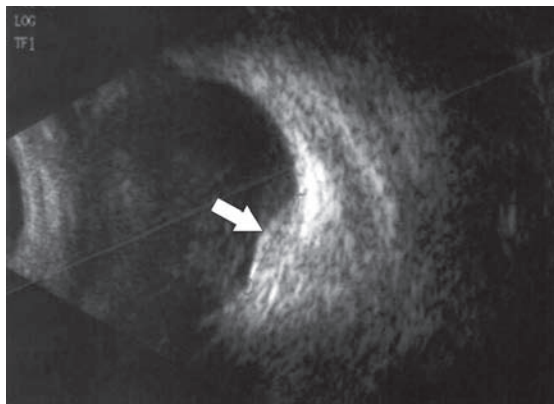


Figure 1 - A B-scan ultrasonography showing a dome shaped mass (arrow) with absence of choroidal excavation.

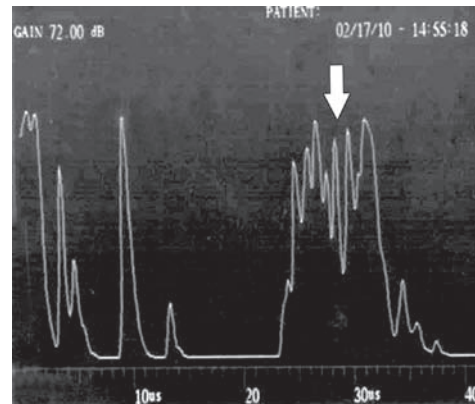


Figure 2 - A-scan ultrasonography of the lesion showing high internal reflectivity (arrow).

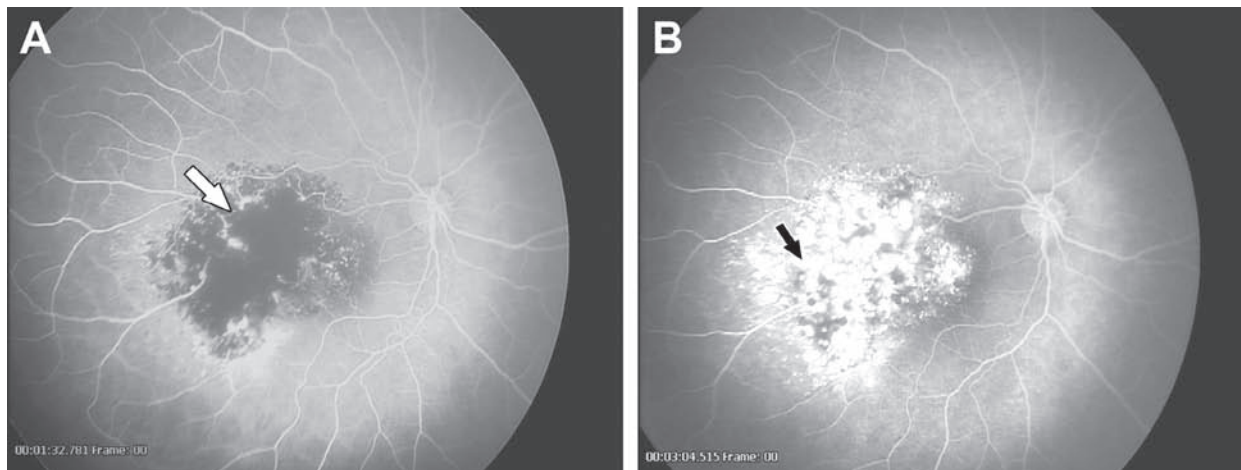


Figure 3 - Fluorescein angiography showing: A) hypofluorescence (white arrow) of the entire lesion in the early phase; B) slow filling of most vascular saccules (black arrow) as the study progresses.

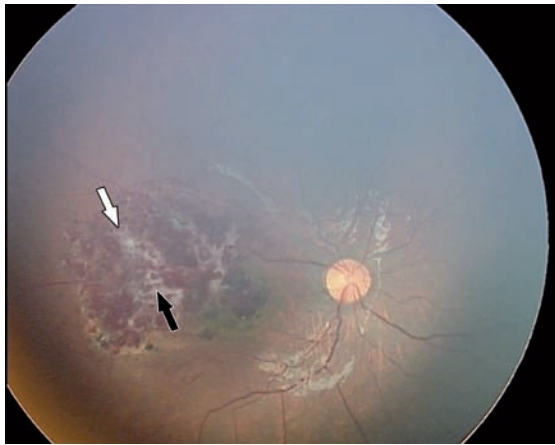


Figure 4 - Color fundus photo showing grape-like sacculations (white arrow) with some white fibrotic tissue over the lesion (black arrow).

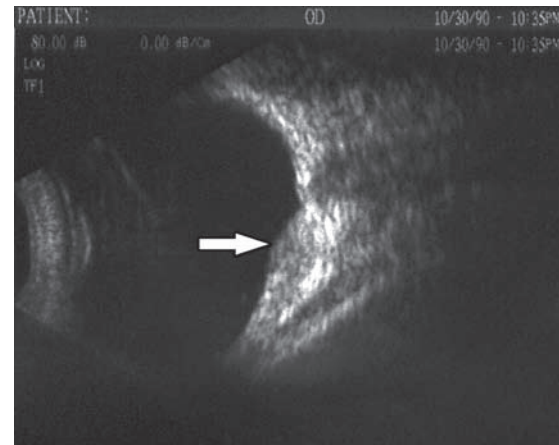


Figure 5 - A B-scan ultrasonography showing the same dome shaped mass with absence of choroidal excavation after infliximab therapy with no apparent change in size.

last infliximab dose, ultrasonography revealed the same highly reflective choroidal mass over the macular area measuring 2.5mm in elevation, 8x9.23mm in diameter (Figure 5). No complications related to infliximab use were noticed during follow-up.

Discussion. Among the differential diagnoses of vitreous hemorrhage in childhood, trauma comes high on the list. Trauma may be accidental, or part of shaken baby syndrome/battered baby syndrome.¹ In our patient, the presence of subconjunctival hemorrhage along with vitreous hemorrhage raised the possibility of non-accidental injury. However, there was a peculiar vascular dilatation filled with dark blood seen through the vitreous opacity.

Retinal cavernous hemangioma is a very rare cause of vitreous hemorrhage. It is even more rare to present in infancy. It has been reported only once in a 6-month-old girl by Gass.² The size of the tumor may account for the vitreous hemorrhage in our patient. The diagnosis is easy to reach most of the time based on the characteristic clinical appearance. Fluorescein angiography typically shows delayed and incomplete filling of the tumor mass, and plasma-erythrocytic layering termed as fluorescence capping. In most cases, there is no evidence of extravascular leakage of dye from these tumors.² Histopathologically, the tumor is composed of thin-walled vascular spaces of variable sizes that occupy the inner half of the retina. Their walls consist of endothelium and in some instances a thin layer of stroma.² Optical coherence tomography findings have been reported and coincide with the

histopathological description.³ Familial cases are thought to have autosomal dominant inheritance with variable penetrance and expressivity.² The patient did not show any systemic findings and the parents were healthy with no ophthalmic problems.

Management of this condition is usually conservative as visual prognosis is good in most cases. Laser photocoagulation, cryotherapy, or diathermy have been reported. These treatment modalities carry the risk of extensive vitreous hemorrhage and scarring with tractional membrane formation.² Vitrectomy can also be used to treat persistent hemorrhage.⁴

Infliximab is a chimeric monoclonal antibody against tumor necrosis factor that is widely used in the treatment of ocular and systemic inflammatory conditions such as Behcet's disease,⁵ rheumatoid arthritis, and Crohn's disease. It has been reported to cause regression of neovascular age-related macular degeneration through its inhibitory effect on vascular endothelial growth factor.⁶ Also, regression of vasoproliferative tumors with systemic infliximab therapy has been reported.⁷ There is a single report of regression of macular cavernous hemangioma with visual acuity improvement after systemic infliximab therapy. Japiassú et al⁸ reported a 63-year old man with retinal cavernous hemangioma complicated by exudation and secondary macular edema, which responded to systemic infliximab therapy with regression of the tumor and resolution of macular edema. In our patient, there was no exudation initially, and the reduction in size after treatment was minimal. Infliximab has been proven to be systemically safe in the pediatric population even at high doses.⁹ Nevertheless,

the physician must always be cautious for any potential side effects.¹⁰

In conclusion, this is a reported case of cavernous hemangioma in infancy that should be distinguished from other retinal vascular abnormalities with serious systemic consequences for the patient. Systemic infliximab does not appear beneficial in the treatment of this tumor.

References

1. Harley RD. Ocular manifestations of child abuse. *J Pediatr Ophthalmol Strabismus* 1980; 17: 5-13.
2. Gass JD. Cavernous hemangioma of the retina. A neuro-oculocutaneous syndrome. *Am J Ophthalmol* 1971; 71: 799-814.
3. Pringle E, Chen S, Rubinstein A, Patel CK, Downes S. Optical coherence tomography in retinal cavernous haemangioma may explain the mechanism of vitreous haemorrhage. *Eye (Lond)* 2009; 23: 1242-1243.
4. Haller JA, Knox DL. Vitrectomy for persistent vitreous hemorrhage from a cavernous hemangioma of the optic disk. *Am J Ophthalmol* 1993; 116: 106-107.
5. Al Rashidi S, Al Fawaz A, Kangave D, Abu El-Asrar AM. Long-term Clinical Outcomes in Patients with Refractory Uveitis Associated with Behçet Disease Treated with Infliximab. *Ocul Immunol Inflamm* 2013; 21: 468-474.
6. Theodossiadis PG, Liarakos VS, Sfikakis PP, Vergados IA, Theodossiadis GP. Intravitreal administration of the anti-tumor necrosis factor agent infliximab for neovascular age-related macular degeneration. *Am J Ophthalmol* 2009; 147: 825-830, 830.e1.
7. Japiassú RM, Brasil OF, Cunha AL, de Souza EC. Regression of vasoproliferative tumor with systemic infliximab. *Ophthalmic Surg Lasers Imaging* 2008; 39: 348-349.
8. Japiassú RM, Moura Brasil OF, de Souza EC. Regression of Macular Cavernous Hemangioma with Systemic Infliximab. *Ophthalmic Surg Lasers Imaging* 2010; 9: 1-3.
9. Friesen CA, Calabro C, Christenson K, Carpenter E, Welchert E, Daniel JF, et al. Safety of infliximab treatment in pediatric patients with inflammatory bowel disease. *J Pediatr Gastroenterol Nutr* 2004; 39: 265-269.
10. Dekker L, Armbrust W, Rademaker CM, Prakken B, Kuis W, Wulfraat NM. Safety of anti-TNFalpha therapy in children with juvenile idiopathic arthritis. *Clin Exp Rheumatol* 2004; 22: 252-258.

Ethical Consent

All manuscripts reporting the results of experimental investigations involving human subjects should include a statement confirming that informed consent was obtained from each subject or subject's guardian, after receiving approval of the experimental protocol by a local human ethics committee, or institutional review board. When reporting experiments on animals, authors should indicate whether the institutional and national guide for the care and use of laboratory animals was followed.