

# Vancomycin-induced acute tubular necrosis

Ahmed M. Alkhunaizi, MD, FACP,  
Kareem Hinedi, MD.

## ABSTRACT

**Objectives:** To report nephrotoxicity in the form of acute tubular necrosis (ATN) related to vancomycin.

**Methods:** This study was conducted at Johns Hopkins Aramco Healthcare, Saudi Aramco, Dharan, Saudi Arabia between June and August 2013. All patients who received intravenous vancomycin as a part of the hospital's vancomycin stewardship program were monitored for the development of ATN.

**Results:** A total of 89 patients received vancomycin over a 3-month period. Three patients developed ATN attributed to high levels of vancomycin, with an incidence of 3.4%.

**Conclusion:** Intravenous vancomycin is nephrotoxic and can lead to ATN. The medical community must be aware of the potential risks of vancomycin associated nephrotoxicity. Renal function and vancomycin drug levels should be closely monitored.

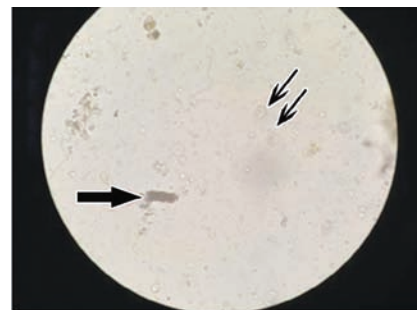
Vancomycin, a tricyclic glycopeptide antibiotic, is a widely used antibiotic for the treatment of infections caused by gram positive organisms, especially methicillin resistant *Staphylococcus aureus* (MRSA). Oral preparations of vancomycin are increasingly used in the treatment of *Clostridium difficile*-induced colitis. The side effect profile of vancomycin can range from the rather benign red-man syndrome (related to rapid infusion of the drug) to the most serious complications, such as Stevens-Johnson syndrome and toxic epidermal necrolysis. Earlier reports of renal failure related to vancomycin were mainly linked to the impurities of vancomycin preparations.<sup>1</sup> Nephrotoxicity related to the new preparations of vancomycin is believed to be a rare phenomenon, and mainly in the form of interstitial nephritis. Here, we report the incidence of vancomycin induced acute tubular necrosis (ATN).

**Methods.** This study was conducted at the Johns Hopkins Aramco Healthcare, Saudi Aramco, Dharan, Saudi Arabia between June and August 2013. We have recently started a vancomycin stewardship program

where patients needing vancomycin were prescribed the antibiotic by our pharmacy team according to body weight and creatinine (Cr) clearance. Trough levels were monitored regularly. Levels of 10-15 mcg/ml were considered adequate for skin and soft tissue infections, while higher levels of 15-20 mcg/ml were the target for more severe infections. All patients were monitored prospectively for the development of side effects, and had their renal function closely monitored. Acute kidney injury (AKI) was defined as an increase in serum Cr of  $\geq 0.3$  mg/dl, or a percentage increase of  $\geq 50\%$  above baseline. The ATN was defined as AKI in addition to the presence of microscopic urinary finding of renal tubular injury, such as renal tubular epithelial cells, in addition to granular casts. Patients who had other reasons to cause AKI, such as sepsis, hypotensive episodes, or were exposed to nephrotoxic agents were excluded. This study was approved by the Institutional Review Board at Johns Hopkins Aramco Healthcare, Dharan, Saudi Arabia.

**Results.** A total of 89 patients were enrolled in the program, and received 89 courses of vancomycin. Three patients developed ATN attributed to vancomycin nephrotoxicity. Urine microscopy showed typical findings of ATN with numerous brown, muddy, and granular casts, in addition to renal tubular epithelial cells (Figure 1). There was no eosinophilia, eosinophiluria, or skin rash. Over this observation period, the incidence of vancomycin induced ATN was 3.4%.

**Patient 1.** An 82-year-old female with hypertension, seizure disorder, and Alzheimer's dementia was admitted with poor intake, altered mental status, and seizure activity. Admission serum Cr was 0.7 mg/dL (normal values: <1.4 mg/dL). Urine culture grew *Escherichia coli*, for which she received intravenous ceftriaxone for several days. She received total parenteral nutrition through a



**Figure 1** - Urine microscopy findings showing granular casts (large arrow), and renal tubular epithelial cells (small arrows) in patient 1 (40x magnification).

central line. During the course of hospitalization, the patient developed line infection with *Staphylococcus epidermidis*, and received intravenous vancomycin. The vancomycin trough levels were elevated at >40 µg/ml occasionally as shown in Figure 2. One week after the initiation of vancomycin, the serum Cr started to increase, and peaked at 2.1 mg/dL within 4 days. She maintained a good urine output. Vancomycin was discontinued, and 7 days later the kidney function started to recover, as shown in Figure 2.

**Patient 2.** A 21-year-old female, a known case of methylmalonic aciduria secondary to cobalamin D deficiency. She had chronic kidney disease (CKD) secondary to interstitial fibrosis. Her baseline serum Cr was 2 mg/dl. She was admitted with portacath infection, and was hemodynamically stable with no signs of metabolic decompensation. The blood culture was positive for coagulase negative *Staphylococcus*, for which she received intravenous vancomycin. The vancomycin trough level was above 20 µg/ml for several days, and it was 40 µg/ml on one occasion. While receiving vancomycin, the serum Cr increased, and peaked at 3.3 mg/dl. Vancomycin was discontinued, and the serum Cr went back to baseline by the time of discharge.

**Patient 3.** A 79-year-old female was diagnosed 2 years earlier with breast cancer, for which she underwent modified mastectomy followed by hormonal therapy. She was admitted with pneumonia and received treatment with ceftriaxone, azithromycin, and vancomycin. Her serum Cr was 1.1 mg/dl, and during the course of treatment it peaked at 4.4 mg/dl.

Vancomycin trough level was above 20 µg/ml on several occasions. Her condition gradually worsened, and she finally expired.

**Discussion.** Three patients developed ATN after exposure to high levels of vancomycin. The ATN was attributed to vancomycin as there were no other identifiable causes to explain the kidney injury. One patient received ceftriaxone prior to the administration of vancomycin, while the third patient received ceftriaxone concomitantly with vancomycin. Ceftriaxone may cause interstitial, rather than tubular renal injury. The absence of eosinophiluria and eosinophilia does not eliminate interstitial nephritis, but makes it a less likely etiology of the acute renal injury. The ATN was diagnosed by the rapid rise of Cr, and documented by the urine microscopy finding of granular casts and renal tubular epithelial cells. All 3 patients had an underlying medical illness. The renal function recovered after discontinuation of vancomycin in 2 patients.

Vancomycin, a tricyclic glycopeptide antibiotic, is a widely used antibiotic for the treatment of a variety of infections, especially those caused by methicillin resistant MRSA. In addition, oral preparations are increasingly used in the treatment of *Clostridium difficile*-induced colitis. The side effect profile of vancomycin can range from the rather benign red-man syndrome (related to rapid infusion of the drug) to the most serious complications such as Stevens-Johnson syndrome, and toxic epidermal necrolysis. Earlier reports of renal failure related to vancomycin were mainly linked to

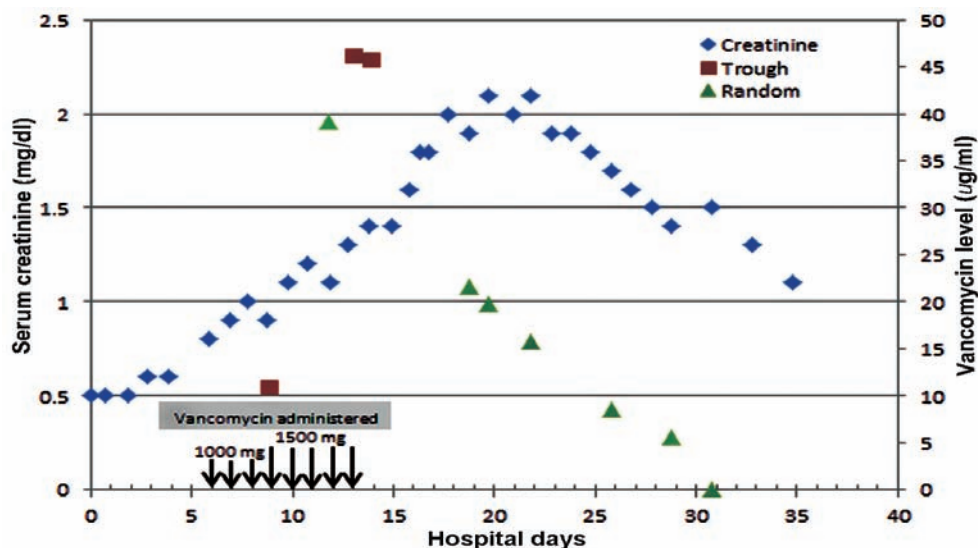


Figure 2 - Serum vancomycin levels in relation to serum creatinine in patient 1.

the impurities of vancomycin preparations.<sup>1</sup> With the advent of more purified forms of vancomycin, renal failure has become a rare event, and mainly attributed to the concomitant use of nephrotoxic agents, such as aminoglycosides and non-steroidal anti-inflammatory agents. Renal injury related to vancomycin itself is rare, and mainly attributed to the development of interstitial nephritis.<sup>2,3</sup> The ATN related to vancomycin has been rarely reported, and attributed to exposure to toxic levels.<sup>1,4-6</sup> Several risk factors are believed to contribute to the development of nephrotoxicity of vancomycin, including exposure to high levels, prolonged therapy, long hospitalization, and concomitant use of other nephrotoxic agents.<sup>7</sup> Vancomycin has been shown to accumulate in all segments of the renal proximal tubule, and less so in the distal tubule and collecting duct.<sup>8</sup> The mechanism of tubular injury is not known, but thought to be related to increased production of reactive oxygen species and oxidative stress.<sup>7,9</sup>

Due to the widespread infection with MRSA and *Clostridium difficile*, the use of vancomycin has accelerated around the globe.<sup>10</sup> As a result, health care professionals should be vigilant to the development of side effects and complications, such as nephrotoxicity. Monitoring vancomycin level is mandatory to prevent toxicity, and to ensure an adequate therapeutic drug concentration.<sup>9</sup>

Received 23rd March 2014. Accepted 1st July 2014.

From the Internal Medicine Services Division, Nephrology Section (Alkhunaizi), General Internal Medicine Unit (Hinedi), Johns Hopkins Aramco Healthcare, Dhahran, Kingdom of Saudi Arabia. Address correspondence and reprints request to: Dr. Ahmed M. Alkhunaizi, Johns Hopkins Aramco Healthcare, Saudi Aramco, PO Box 10955, Dhahran 31311, Kingdom of Saudi Arabia. Tél. +966 (13) 8779748. Fax. +966 (13) 8773790. E-mail: aalkhunaizi@gmail.com / khinedi@gmail.com

## References

1. Shah-Khan F, Scheetz MH, Ghossein C. Biopsy-proven acute tubular necrosis due to vancomycin toxicity. *Int J Nephrol* 2011; 2011: 436856.
2. Htike NL, Santoro J, Gilbert B, Eifenbein IB, Teehan G. Biopsy-proven vancomycin-associated interstitial nephritis and acute tubular necrosis. *Clin Exp Nephrol* 2012; 16: 320-324.
3. Salazar MN, Matthews M, Posadas A, Ehsan M, Graeber C. Biopsy proven interstitial nephritis following treatment with vancomycin: a case report. *Conn Med* 2010; 74: 139-141.
4. Wicklow BA, Ogborn MR, Gibson IW, Blydt-Hansen TD. Biopsy-proven acute tubular necrosis in a child attributed to vancomycin intoxication. *Pediatr Nephrol* 2006; 21: 1194-1196.
5. Belen C, Budhiraja P, Bracamonte E, Popovtzer M. Biopsy-proven acute tubular necrosis associated with vancomycin in an adult patient. *Ren Fail* 2012; 34: 502-505.
6. Sokol H, Vigneau C, Maury E, Guidet B, Offenstadt G. Biopsy-proven anuric acute tubular necrosis associated with vancomycin and one dose of aminoside. *Nephrol Dial Transplant* 2004; 19: 1921-1922.
7. Elyasi S, Khalili H, shti-Khavidaki S, Mohammadpour A. Vancomycin-induced nephrotoxicity: mechanism, incidence, risk factors and special populations. A literature review. *Eur J Clin Pharmacol* 2012; 68: 1243-1255.
8. Fujiwara K, Yoshizaki Y, Shin M, Miyazaki T, Saita T, Nagata S. Immunocytochemistry for vancomycin using a monoclonal antibody that reveals accumulation of the drug in rat kidney and liver. *Antimicrob Agents Chemother* 2012; 56: 5883-5891.
9. Levine DP. Vancomycin: a history. *Clin Infect Dis* 2006; 42 Suppl 1: S5-S12.
10. Kirst HA, Thompson DG, Nicas TI. Historical yearly usage of vancomycin. *Antimicrob Agents Chemother* 1998; 42: 1303-1304.

## New Peer Reviewers

Join our team of expert peer reviewers for the Saudi Medical Journal by sending an enquiry and summarized CV to [info@smj.org.sa](mailto:info@smj.org.sa). Note that SMJ reviewers, whose reviews are returned on time and are judged satisfactory by the Editors, may receive 1 CME credit per review, with a maximum of 5 credits per year, from the Saudi Council for Health Specialties.