

# The superior gluteal artery perforator flap for reconstruction of sacral sores

Weijian Chen, MS, Bo Jiang, MS, Jiaju Zhao, MS, Peiji Wang, MD.

## ABSTRACT

في هذا التقرير نصف تجربتنا باستخدام شرائح ثابتة للشريان الألووي العلوي SGAP لإعادة ترميم حالتين للقرحة العجزية. عالجتنا في وحدتنا مريضة تبلغ من العمر 47 عام ومريض يبلغ من العمر 38 عام يعانون من قرحة عجزية. بلغ حجم العيوب 6×5 سم<sup>2</sup> و 9×8 سم<sup>2</sup>. وأصلح التشوه بشرائح SGAP. وكان حجم تصميم شرائح SGAP يختلف من 20×7 إلى 16×9 سم<sup>2</sup>. وقد بقت جميع الشرائح والتئمت الأولية، والملمس، والوظائف وكان ظهورها مرضي دون أي ضعف في المنطقة المتلقية والمتبرعة. شرائح SGAP التي لديها إمدادات الدم يمكن الإعتماد عليها وتحافظ على عضلة الألووية الكبيرة ويمكن نقلها ببساطة وأمان وهو الأسلوب الأمثل ويمكن إعادة استخدامها لإعادة بناء القروح العجزية مع انخفاض معدل تكرارها بعد الجراحة وظهور المرض.

This report describes our experiences using the superior gluteal artery perforator (SGAP) flaps for reconstruction of 2 sacral sore cases. A 47-year-old female patient and a 38-year-old man with sacral sores were treated in our unit. The size of the defects were approximately 5×6 cm<sup>2</sup> and 8×9 cm<sup>2</sup>, the defects were repaired by SGAP flaps. The size of designed was SGAP flaps varied from 7×20 to 9×16 cm<sup>2</sup>. All flaps survived and healed primary, the texture, functions, and appearance of flaps were satisfactory, and also without region dysfunction of donor and recipient sites. The SGAP flap, which has reliable blood supply, preserves the gluteus maximus muscle and could be transferred simply and safely, is an ideal and reusable method to reconstruct sacral sores with low rate of postoperative recurrence and satisfactory appearance.

*Saudi Med J* 2016; Vol. 37 (10): 1140-1143  
doi: 10.15537/smj.2016.10.15682

From the Department of Hand and Foot Surgery (Chen, Jiang, Zhao, Wang), The Second Affiliated Hospital of Soochow University, Suzhou, and the Department of Orthopedic Surgery (Chen), Affiliated Provincial Hospital of Anhui Medical University, Hefei, China.

Received 31st May 2016. Accepted 17th June 2016.

Address correspondence and reprint request to: Dr. Peiji Wang, Department of Hand and Foot Surgery, The Second Affiliated Hospital of Soochow University, Suzhou, China. E-mail: wangpeiji88@163.com

Pressure sores result from the destruction of skin and underlying soft tissue due to continuous pressure applied to the skin and muscle. As a result, the blood supply to the tissue is decreased, which leads to necrosis.<sup>1</sup> And also, those patients with exposed sacrum, thin skin, and subcutaneous tissue had a higher rate of recurrence. Therefore, reconstructing a sacral sore is still a thorny problem to surgeons. Many traditional methods were applied to repair it, such as primary closure, local random flaps, and muscle flaps. Recently, the gluteus maximus myocutaneous flap has been a mainstream method to repair sores because of providing excellent blood supply and mass of tissue that allow for better distribution of pressure.<sup>2</sup> Simultaneously, the major drawbacks such as limited shifting capacity, excessive blood loss, and muscle atrophy long-term postoperation limit the range of application in some cases.<sup>3</sup> After the concept of a perforator flap was introduced by Koshima et al,<sup>4</sup> the perforator flaps were extensively used in the treatment of soft tissue defects. With the in-depth research of anatomy and application of clinical of the SGAP flaps, they became well accepted as useful alternatives for reconstruction of sacral, ischial, and trochanteric pressure ulcers. The aim of our study

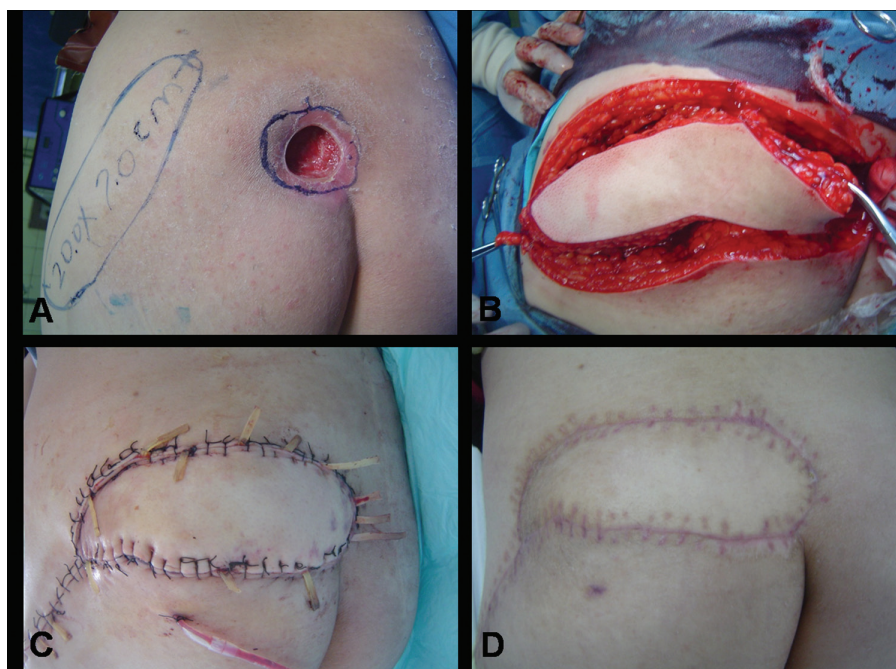
**Disclosure.** Authors have no conflict of interests, and the work was not supported or funded by any drug company. This study was funded by the Scientific and Technological Development Planning Project, Suzhou, (No. SYS201230), and the Preponderant Clinic Discipline Group Project Funding of the Second Affiliated Hospital of Soochow University (No.XKQ2015010), Soochow, China.

was to show the experiences obtained from using the SGAP flaps for reconstruction of sacral sores.

**Case Report. Patient 1.** A 47-year-old female was involved in a traffic accident with right femoral shaft fracture, after an open reduction and internal fixation, bedridden long-term and improper nurse lead directly to a sacral sore at home. After debridement, the size of the defect was approximately 5×6 cm<sup>2</sup> (Figure 1A). Besides, anti-infective treatment and local treatment for one week preceded surgical reconstruction. Then, a left SGAP flap was harvested to cover the defect. The size of the flap was 7×20 cm<sup>2</sup> (Figure 1B). The procedure of operation runs: the skin of the superior border of the flap was incised firstly along the marked line down through the subcutaneous tissue and deep fascia to the muscle, until our chosen perforator was encountered. By using a loup magnification, this vessel was dissected out slowly by splitting the muscles fibres rather than cutting, and carefully ligated the small muscular side branches. It is no need to excessively dissect this vessel to the origin of the superior gluteal artery to prevent injury to the perforator vessel. Generally, the pedicle contained

one, at most 2 perforators in the flap we designed, we thought that multiple perforators in the pedicle would restrict the mobility of flap. After the inferior border of the flap was then incised, the flap was detached from the muscle, perforator vessel was chosen as the pivot point to advance, or rotate the SGAP flap into the sacral defect, took care to avoid twisting, kinking, compression, or undue tension on the pedicle. The operative region was closed primarily without tension, suction drainages were applied under the flap and defect (Figure 1C). The flap survived and healed primary without flap necrosis. After 10 months of follow-up, the result remained stable, there was no donor site morbidity, no recurrence, and also the appearance of the surgical site was satisfactory (Figure 1D).

**Patient 2.** A 38-year-old man became paraplegic because of severe spinal cord injury and developed a deep sacral and 2 trochanteric pressure sores, which failed to heal with traditional methods at the other hospital (Figure 2A). Necrectomy, local treatment, anti-infective treatment and enhanced nutrition were underwent before surgery, the defect measured 8×9 cm<sup>2</sup> after completely debridement. Two weeks



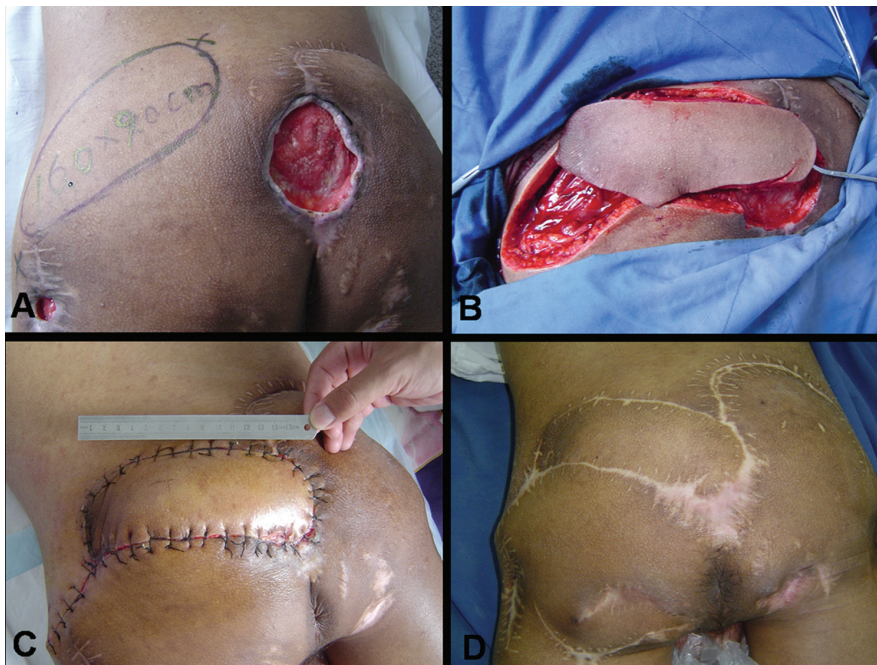
**Figure 1** - Photograph showing A) a 47-year-old female involved in a traffic accident with right femoral shaft fracture, bedridden long-term lead to a sacral sore with the size of 5×6 cm<sup>2</sup> after debridement. B) The superior gluteal artery perforator (SGAP) flap with the size of 7×20 cm<sup>2</sup> was harvested to cover the defect. C) The operative region was closed primarily without tension, suction drainages were applied under the flap and defect. D) The flap survived and healed primary. After 10 months of follow-up, there was no donor site morbidity, no recurrence, the texture, functions and appearance of flaps were satisfactory.

later, a flap of  $9 \times 16 \text{ cm}^2$  based on a superior gluteal artery perforator was rotated into the defect, the wound of trochanteric pressure sores was closed directly after excised the necrotic tissue and granulation tissue (Figure 2B). The flap survived and healed primary after 10 days, postoperatively (Figure 2C). With a follow-up of 2 years, the original sacral sore region and ischial pressure ulcers were uneventful (Figure 2D).

**Discussion.** Patients who are paraplegic, or bedridden are prone to pressure sores due to long-term constant compression, sacral region is usually happen to pressure sores due to its relatively thin layer of soft tissues overlying the sacrum and local poor blood supply, which make the sores reluctant to heal, prone to recurrence, and difficult to reconstruct. Traditional methods such as the gluteus maximus myocutaneous flaps with its major drawbacks such as limited shifting capacity, excessive blood loss, sacrifice the function of the normal muscle, and not reusable if sore recurrence occurs at the same region, which may limit the range of application in some cases. To address this problem,

we should consider the possibility of sore recurrence, preserve other reconstructive flap options and minimize the function damage to donor site before harvesting a flap

In 1993, Koshima et al<sup>4</sup> introduced the concept of a perforator flap for treating pressure sores in the sacrococcygeal region. With an evolution of work by surgeons, such as big difference had brought to this problem. According to an anatomical study by Ahmadzadeh et al,<sup>5</sup> a mean of  $5 + 2$  cutaneous perforators can be found in the gluteal region arising from the superior gluteal artery. All of the superior gluteal artery perforators were musculocutaneous perforators passing through the gluteal muscle. The average diameter of the perforators arising from the superior ranged from 0.6 to 1.0 mm. Each perforator of the superior gluteal artery supplies an mean area of  $21 \pm 8 \text{ cm}^2$ . With the in-depth research of anatomy and application of clinical of the SGAP flap, it was well accepted as an reliable and alternative method to reconstruct soft tissue defects in sacrococcygeal, greater trochanter, and ischial tuberosity regions.



**Figure 2** - Photograph showing A) a 38-year-old paraplegic man with severe spinal cord injury and developed a deep sacral and 2 trochanteric pressure sores. The defect of sacral region measured  $8 \times 9 \text{ cm}^2$  after debridement. B) A flap of  $9 \times 16 \text{ cm}^2$  based on a superior gluteal artery perforator was harvest to reconstruct the defect, the wound of trochanteric pressure sores was closed directly after excised the necrotic tissue and granulation tissue. C) The flap survived and healed primary after 10 days postoperative. D) With a follow-up of 2 years, the original sacral sore region and ischial pressure ulcers were uneventful.



Compare to traditional methods, the SGAP flaps were found many prominent advantages run: the perforator flap based on the superior gluteal artery has detectable anatomy. Therefore, it has reliable blood supply that make it high graft survival rate, and also, perforator flaps differ from myocutaneous flaps in that they only contain skin and subcutaneous fat; therefore, the sacrococcygeal region has fine appearance, good texture, and no significant flap bloated, which largely brought aesthetic results (Figure 1D). Furthermore, the SGAP flap preserves the entire contralateral side as a future donor site. On the ipsilateral side, the gluteal muscle itself is preserved and all flaps which based on the inferior gluteal artery are still available.<sup>6</sup> As we all know, sacral sores were prone to recurrence especially to paraplegic patients because of the local anatomy, despite any successful surgery, the possibility of ulcer recurrence and the absence of an available skin paddle should be taken into consideration if the recurrence occurs at the same location. Take the gluteus maximus myocutaneous flaps for example, if they were used initially, it was difficult to elevate healthy tissue ipsilateral side next to the sore to reconstruct the defect if the recurrence occurs. For this reason, it is significant that preservation of the tissue structure and vascularity in those cases in which secondary surgery is probably required.<sup>7</sup> Moreover, the SGAP flap minimizes blood and donor site morbidity, preserves the intact gluteal muscle and prevent the sacrifice of its function which is crucial to those ambulatory patients.<sup>8</sup> In our patients without paraplegia, this method did not affect their hip joints extension-flexion function, or walking.

Two patients in our treatment group with pressure sores were all in sacral region, all flaps survived and healed primary without significant postoperative complications. To better reach this goal, we have the following experiences and suggestions: 1) A good general condition is the premise of a successful reconstruction, notice to strengthen nutrition, compensatory albumen and vitamin, improve microcirculation, systemic and local infection control. 2) Completely debride the ulcerated area and scar tissues with adequate bursectomy, generally, the underlying bursa were deeper and wider than the skin defect. Thus, these nonviable tissues must be excised down to healthy tissue. 3) Guided by a hand-held doppler, we chose

the most lateral perforator vessel as the pedicle, the flap around which would create a longest pedicle possible to give a greater arc of movement. Generally, the pedicle contained one, at most 2 perforators in the flap we designed, we thought that multiple perforators in the pedicle would restrict the mobility of flap. 4) Dissection was time consuming and required extreme care to prevent injury to the perforator vessel, this vessel should be dissected out slowly by splitting along the muscles fibres rather than cutting, and carefully ligate the small muscular side branches, and also no need to excessively dissect it to the origin of the superior gluteal artery. 5) We preferred to close the donor site firstly to reduce the tension between the defect and flap, which would help to reduce the risk of wound dehiscence. 6) It is necessary to educate patients and caregivers learn to pressure relief and skin care for good long-term results. Recurrence is usually not secondary to the operation, but to the poor compliance of patients at home or the lack of appropriate wound care assistance.<sup>9</sup>

## References

1. Kim CM, Yun IS, Lee DW, Lew DH, Rah DK, Lee WJ. Treatment of ischial pressure sores with both profunda femoris artery perforator flaps and muscle flap. *Arch Plast Surg* 2014; 41: 387-393.
2. Cushing CA, Phillips LG. Evidence-based medicine: pressure sores. *Plast Reconstr Surg* 2013; 132: 1720-1732.
3. Parry SW, Mathes SJ. Bilateral gluteus maximus myocutaneous advancement flaps: sacral coverage for ambulatory patients. *Ann Plast Surg* 1982; 8: 443-445.
4. Koshima I, Moriguchi T, Soeda S, Kawata S, Ohta S, Ikeda A. The gluteal perforator-based flap for repair of sacral pressure sores. *Plast Reconstr Surg* 1993; 91: 678-683.
5. Ahmadzadeh R1, Bergeron L, Tang M, Morris SF. The superior and inferior gluteal artery perforator flaps. *Plast Reconstr Surg* 2007; 120: 1551-1556.
6. Lin CT, Chang SC, Chen SG, Tzeng YS. Modification of the superior gluteal artery perforator flap for reconstruction of sacral sores. *J Plast Reconstr Aesthet Surg* 2014; 67: 526-532.
7. Lin PY, Kuo YR, Tsai YT. A reusable perforator-preserving gluteal artery-based rotation fasciocutaneous flap for pressure sore reconstruction. *Microsurgery* 2012; 32: 189-195.
8. Hurbungs A, Ramkalawan H. Sacral pressure sore reconstruction-the pedicled superior gluteal artery perforator flap. *S Afr J Surg* 2012; 50: 6-8.
9. Gusenoff JA, Redett RJ, Nahabedian MY. Outcomes for surgical coverage of pressure sores in nonambulatory, nonparaplegic, elderly patients. *Ann Plast Surg* 2002; 48: 633-640.